

BSC 702 Gross Anatomy

Lecture Notes:

Thorax, Abdomen and Pelvis

Fall 2013

Thoracic Wall

By Thierry Bacro, Ph.D

Center for Anatomical Studies and Education
Department of Regenerative Medicine and Cell Biology
College of Medicine
Medical University of South Carolina

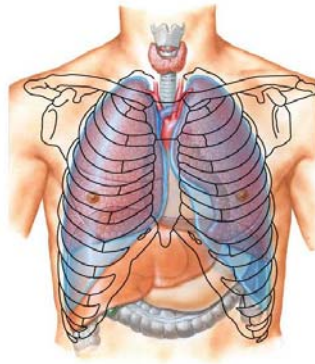
Slide 2: In this lecture, we will discuss the main features of the thoracic walls. We will also describe the main function of these components.

The Thorax

The thorax is the region of the trunk between the neck and the abdomen.

The content of the thorax, the thoracic viscera are surrounded and protected by the bone and cartilage framework of the thoracic cage.

The upper abdominal viscera are also protected by the thoracic cage.



Netter 190

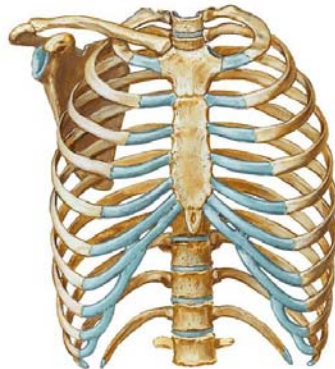Slide 2.

The thorax is the region of the trunk between the neck and the abdomen. In this lecture we will consider the structure of the thoracic wall, its skeletal and muscular components, blood and nerve supply, and briefly some thoracic contents, especially as they relate to the thoracic wall. The visceral contents of the thoracic cavity are surrounded and protected by a bone and cartilage framework, the thoracic cage. The viscera of the upper part of the abdomen are also protected by the thoracic cage.

Thoracic Cage

The sternum consists of

- The manubrium (T₃-T₄)
- The body (T₅-T₈)
- The xiphoid process
- The manubriosternal joint (sternal angle) (T₄-T₅)
- The xiphisternal joint (T₉).



Netter 179

Slide 3.

The thoracic cage consists of the sternum, 12 ribs, and the 12 thoracic vertebrae. The sternum is the flat bone in the anterior midline with three parts: manubrium, body, and xiphoid process. The manubrium is located at the level of the 3rd and 4th vertebral bodies. The clavicles and the first ribs articulate at the top on each side. The manubrium articulates with the body at the manubriosternal joint. At this location, the joint makes a palpable ridge called the sternal angle (angle of Louis), and the second costal cartilage joins the sternum at this point. The sternal angle is located between the level of T₄ and T₅ vertebral bodies and is an important landmark for several structures in the thorax. The sternal body lies at the levels of T₅-T₈. It articulates with the xiphoid process at the xiphisternal joint. This is located at the T₉ level.

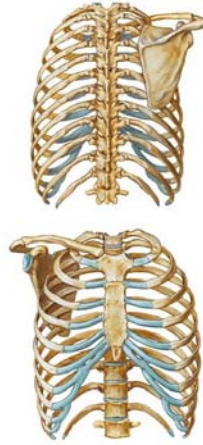Thoracic Cage

The posterior wall of the thoracic cage include the 12 thoracic vertebrae with the 12 ribs passing anteriorly.

Anteriorly, note the following:

- The costal cartilages
- The 2nd rib at the sternal angle
- The ribs 1 to 7 articulating with the sternum
- The costal cartilages 8 to 10 fuse to the costal cartilage 7
- The ribs 11 and 12 have no attachment to sternum.

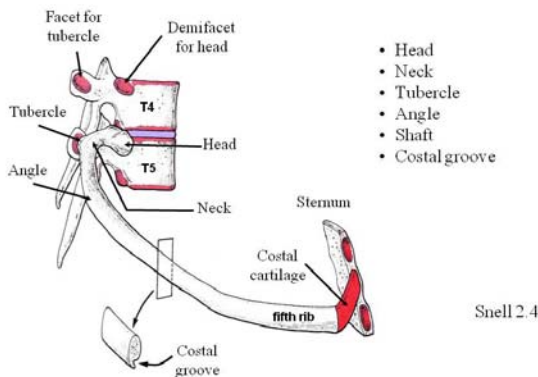
Netter 179



Slide 4.

Each thoracic vertebra articulates with one or more ribs on each side. There are 12 pairs of ribs and each articulates with its corresponding vertebra. The upper 7 articulate via costal cartilages directly with the sternum. The cartilages of ribs 8, 9, and 10 fuse and join with the 7th rib to form a single sternal attachment. Ribs 11 and 12 have short costal cartilage ends but make no attachment to the sternum. These are commonly called the floating ribs. Ribs can be classified as typical or atypical.

Typical Ribs (2-7)



Slide 5.

Typical ribs (2-7) are long, flat bones with a smooth upper edge and a sharper inferior edge with a costal groove. A typical rib has a head, neck, tubercle, angle, and shaft. Two articular facets on the head form joints with the same numbered vertebral body and with the vertebra above. The tubercle articulates with the transverse process of the same numbered vertebra. At the angle, the rib shaft takes a relatively sharp bend and twists anteriorly. The shaft joins the sternum by a costal cartilage.

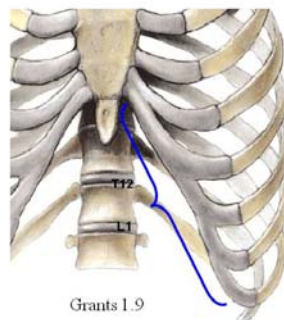
Atypical Ribs (8-12)

The ribs 8 to 10 are articulating with the fused costal cartilages which then articulate with sternum via 7th.

The fused costal cartilages form the costal margin with the tips of 11 and 12 (lowest point at L3).

The ribs 11 and 12 are the "floating ribs". They do not attached to the sternum.

Note that the ribs 1, 10, 11, 12 articulate with one vertebral body.

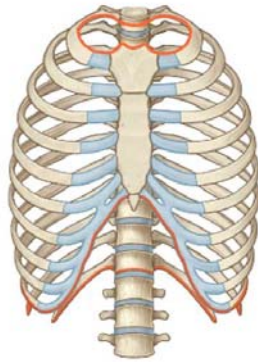


Slide 6.

Ribs 8 through 12 (and rib 1) are considered atypical. Costal cartilages of ribs 8-10 are fused and make indirect articulation with the sternum through the 7th costal cartilage. This fusion of cartilages 7 through 10 forms the costal margin, a palpable antero-inferior border. The most inferior part of the costal margin includes the tips of the floating ribs, 11 and 12, at the L3 vertebral level. Note also that ribs 1, 10, 11, and 12 articulate with only one vertebral body. The flattened first rib is included in this classification.

The 2 Thoracic Apertures

The superior aperture is at the root of neck. The borders are the T₁ vertebra, 1st ribs, the first costal cartilages and the superior border of the manubrium. The inferior aperture communicates with the abdomen and its borders are the T₁₂ vertebra, costal margin and xiphisternal joint.



Drake fig 3.4A

Slide 7.

The thoracic cage is incomplete superiorly and inferiorly at apertures which permit passage of structures to and from the neck and the abdomen. The superior aperture at the root of the neck is bordered by the T₁ vertebral body, the 1st ribs and the superior edge of the manubrium. The inferior aperture is bordered by the body of the T₁₂ vertebra, the entire costal margin, and the xiphisternal joint.

The Superior Aperture

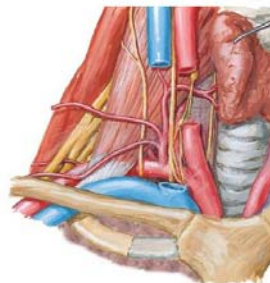
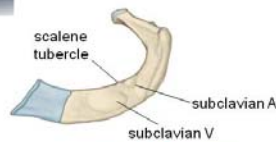
The 1st rib is the anterior border of the superior aperture. Note the following:

- Flat and broad
- Grooves for subclavian artery and vein
- Has a scalene tubercle for the anterior scalene muscle

Note the superior aperture allows the passage of the following structures:

- The vessels and nerves to upper limb and neck
- The trachea and esophagus
- The superior portion of each lung and pleura.

Drake (Gray) 3.22



Netter 32

Slide 8.

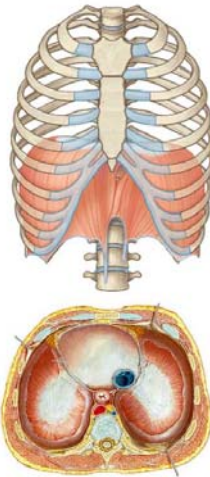
Major vessels and nerves pass through the superior thoracic aperture. The apex of lung with its pleura projects above the 1st rib on each side. The trachea and esophagus pass through at the midline. The superior thoracic aperture is bordered anteriorly and laterally by the atypical 1st rib, which has grooves on its superior side for subclavian vein and artery and a scalene tubercle for attachment of the anterior scalene muscle. Roots of the brachial plexus pass between anterior and middle scalene muscles.

The Inferior Aperture

Drake fig 3.4B

The inferior aperture is closed by the diaphragm (dome shape). The following main structures pass through it:

- Vessels, nerves to/from thorax and abdomen
- Esophagus
- Aorta
- Esophagus
- Inferior vena cava



Netter 188

Slide 9.

The inferior thoracic aperture is closed by the diaphragm. It allows the passage of the esophagus, aorta, inferior vena cava, and nerves to the abdomen. The diaphragm has a double-domed shape. In the lower drawing, the pericardium on the diaphragm and parietal pleura are cut away to show the domes of the diaphragm. Due to its curved shape, at mid-inspiration the opening of the inferior vena cava is at the T₈ vertebral level, the esophageal hiatus at T₁₀, and the aortic hiatus at T₁₂.

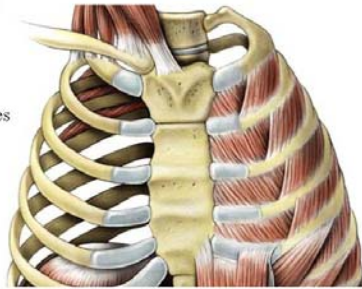
Muscles of the Thoracic Wall.

Grants 1.T2

It has 3 layers of intercostal muscles:

- The external intercostal
- The internal intercostal
- The innermost intercostal

Note that the intercostal veins, arteries and nerves pass between the internal and innermost layers.



Slide 10.

The intercostal spaces are closed by 3 layers of intercostal muscles. The intercostal veins, arteries, and nerves travel a course between the internal and innermost layers.

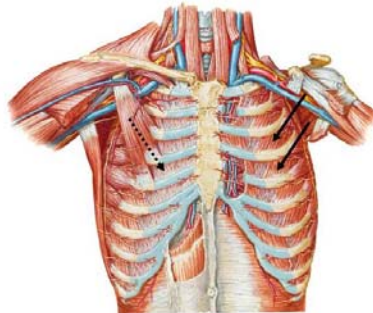
External Intercostal Muscles

Netter 183

- Origin: from the lower border of the ribs
- Extent: from the tubercle to the costochondral junction
- Insertion: on the superior border of the rib below.

Note that the same layer continues anteriorly as the external intercostal membrane.

Observe also the orientation of the muscle fibers, downward and forward.



Slide 11.

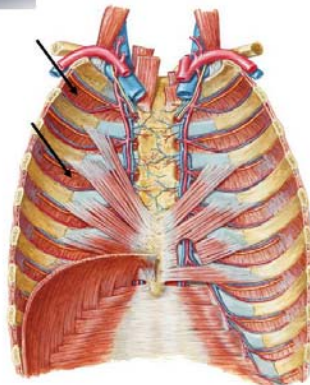
The external intercostal muscle is most superficial. It originates along lower borders of the ribs and inserts on superior borders of the next ribs below. Fiber directions are downward and anteriorly directed (like putting your hands into your front pants pockets). The muscle extends from the rib tubercles around anteriorly as far as costochondral junctions. From there, the superficial layer continues as an aponeurosis called the external intercostal membrane.

Internal Intercostal Muscles

Netter 184

- Origin: from the subcostal groove of the ribs
- Insertion: to the superior border of the rib below

Observe also the orientation of the muscle fibers, downward and backward.

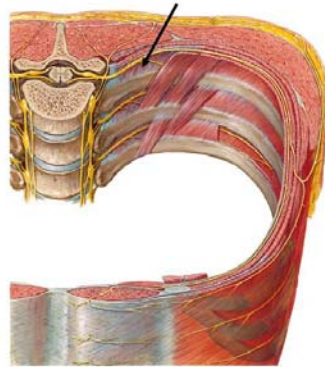


Slide 12.

The internal intercostal muscle originates in the subcostal grooves and inserts on the superior border of the next rib. Fibers are directed downward and posteriorly (like when you give a military salute). The muscle extends from just adjacent to the sternum around posteriorly as far as the angle of the ribs. From the angle, this second layer continues as the aponeurotic internal intercostal membrane (see next slide).

Internal Intercostal Membrane

Note that the same layer continues posteriorly as an aponeurosis called the internal intercostal membrane.



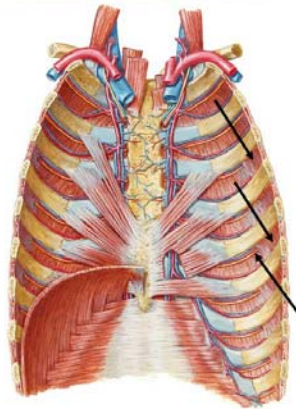
Netter 252

Slide 13.

One can observe on this view from Netter the internal intercostal membrane.

Innermost Intercostal Muscles

- The deepest layer of muscles crossing the intercostal space
 - Associated with other deep muscles such as the transversus thoracis and the subcostals
- Note the intercostal vessels and nerves pass between internal and innermost intercostal muscle layers.

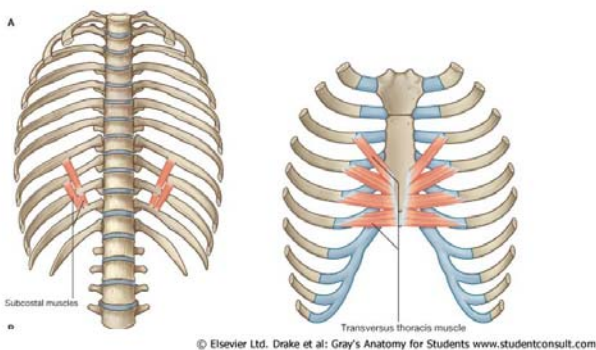


Netter 184

Slide 14.

The innermost intercostal muscles are the deepest muscles across intercostal spaces. The fibers are oriented in the same direction as internal intercostals. They are best defined on the lateral thoracic wall. Note how the intercostal nerves and vessels pass between internal and innermost intercostal muscle layers. In the same plane are 2 other more minor muscle sets of muscles associated with the innermost intercostals: the transversus thoracis on the anterior wall and subcostals (not shown on this slide, see next) on the posterior wall, near the angles of the ribs.

Innermost Intercostal Muscles



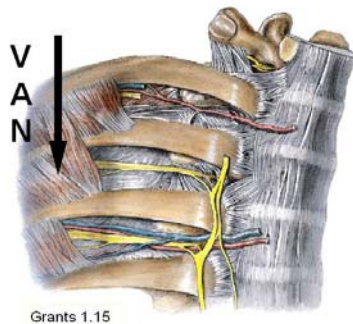
© Elsevier Ltd. Drake et al: Gray's Anatomy for Students www.studentconsult.com

Slide 15.

Visualize on this drawing from Drake the transversus thoracis on the posterior aspect of the anterior wall and subcostals on the anterior aspect of the posterior wall, near the angles of the ribs.

Intercostal Vessels and Nerves

The vessels and nerves are located in the subcostal groove, between the innermost and inner layers of muscles. Note also on this view the sympathetic chain with the rami communicantes.

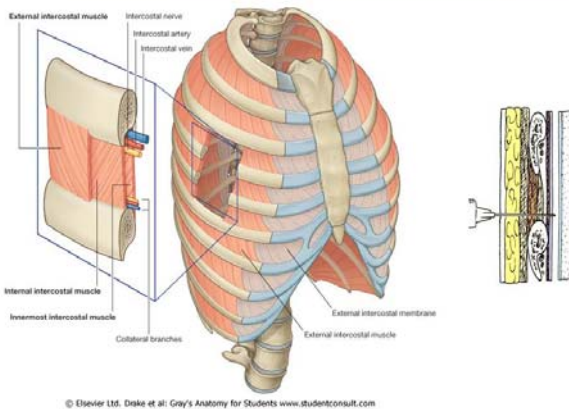


Grants 1.15

Slide 16.

In this image of the deep side of the posterior thoracic wall, the intercostal veins, arteries and nerves are beginning their course between the innermost and internal intercostal muscle layers. At the top rib in this group, the vessels and nerves are just entering the subcostal groove. The arrangement of the linear structures in the subcostal groove from superior to inferior is consistently Vein, Artery, Nerve.

Intercostal Vessels and Nerves



© Elsevier Ltd. Drake et al: Gray's Anatomy for Students www.studentconsult.com

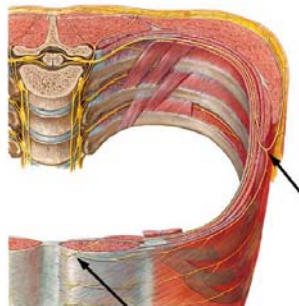
Slide 17.

Air or fluid may be removed through an intercostal space by needle thoracocentesis or thoracostomy drainage tube. The layers penetrated include: skin, superficial fascia, serratus anterior muscle, external, internal and innermost intercostal muscles, endothoracic fascia, and parietal pleura.

Insertion should be at the superior edge of a rib to avoid damage to vessels and nerves. Both of these procedures differ from a thoracotomy, an opening through an intercostal space.

Intercostal Nerves

- Recall that these are the continuation of the ventral primary rami of T₁₋₁₂ with T₁₂ being the subcostal nerve
- Note that at the costal margin, the T₇ to T₁₁ nerves leave the intercostal space and continue in the anterior abdominal wall.
- The branches are :
 - Lateral and anterior cutaneous
 - Motor (to the intercostal muscles)
 - Motor (to the muscles of the abdominal wall for T₇-T₁₂)
 - Sensory (parietal pleural)
 - Sensory (peritoneum) (T₇-T₁₂)



Netter 252

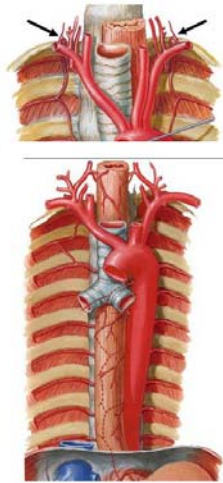
Slide 18.

Intercostal nerves are continuation of the anterior primary rami of thoracic spinal nerves, providing cutaneous supply to lateral and anterior thoracic wall (and abdominal wall), motor supply to intercostal muscles, motor supply to abdominal wall muscles (T₇₋₁₂), and sensory supply to the parietal pleura and peritoneum (T₇₋₁₂). The 12th nerve is given the special name, subcostal nerve, as it runs below the 12th rib (in the abdominal wall).

Posterior Intercostal Arteries

- In the intercostal spaces 1 and 2: branches of superior intercostal arteries (branch of costocervical trunk from subclavian artery)
- In the intercostal spaces 3 to 11: from the posterior intercostal arteries (from thoracic aorta).

Netter 201 and 231



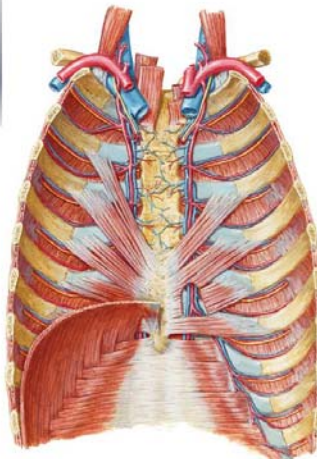
Slide 19.

The superior intercostal artery (a branch of the costocervical trunk, itself a branch of the subclavian artery) supplies the first 2 intercostal spaces on both sides. Starting at the 3rd intercostal space, the other posterior intercostal arteries are branches of the descending thoracic aorta. All the intercostal arteries travel around the thoracic wall in the subcostal grooves between the internal and innermost intercostal muscle layers.

Anterior Intercostal Arteries

- In the intercostal spaces 1 to 6: the branches are from the internal thoracic artery (from the 1st portion of the subclavian artery)
- In the intercostal spaces 7 to 11: the branches are from the musculophrenic artery (a branch of the internal thoracic artery).

Netter 184



Slide 20.

The anterior intercostal arteries in the first 6 intercostal spaces are branches from the internal thoracic artery, on each side of the sternum.

The internal intercostal artery divides at the 7th intercostal space into 2 terminal branches, the musculophrenic artery, which courses around the muscular border of the diaphragm, and the superior epigastric artery, which descends deep to the anterior abdominal wall.

The anterior intercostal arteries for spaces 7-11 are branches of the musculophrenic artery.

Intercostal Arteries

| Spaces | Anterior intercostal arteries | Posterior intercostal arteries |
|--------|--|---|
| 1-2 | Internal thoracic A (from 1 st part of subclavian) | Superior intercostal A (costocervical trunk) |
| 3-4 | | Thoracic aorta |
| 5-6 | | |
| 7-8 | Musculophrenic A (from internal thoracic) | |
| 9-10 | | |
| 11 | | |

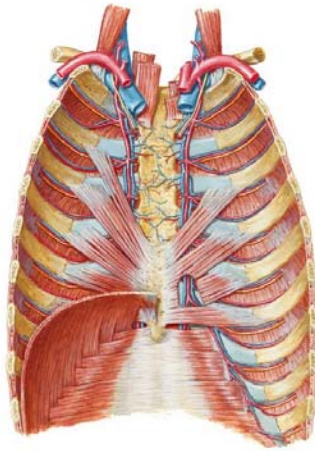
Slide 21.

This table provides you with a summary of the arterial blood supply of the thoracic wall.

Anterior Intercostal Veins

- Anteriorly the venous drainage parallels arterial supply
- The internal thoracic veins drain into the brachiocephalic vein on each side
- The lymphatics from the anterior wall drain into the internal thoracic nodes.

Netter 184



Slide 22.

The venous drainage on the anterior thoracic wall parallels the arterial supply to either the musculophrenic vein or directly to the internal thoracic vein. The internal thoracic vein drains in the brachiocephalic vein.

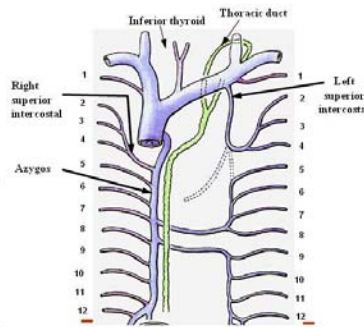
Lymphatic drainage of the anterior thoracic wall goes first to the internal thoracic lymph nodes along the internal thoracic arteries and veins.

Azygos System

The azygos system drains the posterior intercostal veins.

- On both sides: the 1st space into brachiocephalic vein
- On right side:
 - The 2 to 4th spaces into right superior intercostal vein, then into azygos vein
 - The 5 to 12th spaces directly into the azygos vein

Thoracic duct drains into left brachiocephalic/jugular veins



Grants, 1-74

Slide 23.

The more common scheme of venous drainage on the posterior thoracic wall differs slightly from the one in your text but the pattern presented here in this slide is the one you should learn. Expect to see variations of this pattern in the dissection.

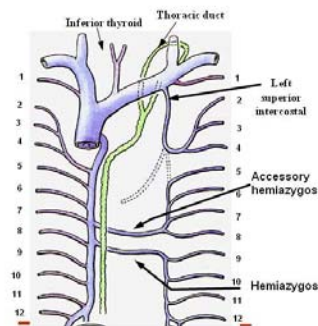
On the right side, the 1st vein drains directly into the right brachiocephalic vein.

The veins from the 2nd to the 4th drain to the right superior intercostal vein which empty in the azygos vein. The rest (5 to 12) drain directly into the azygos vein. Note that the azygos vein arches over the root of the right lung to drain into the superior vena cava.

The lymphatic drainage of the posterior wall goes to posterior intercostal and para-aortic lymph nodes. Lymphatic vessels then connect to the thoracic duct (see later in this lecture).

Azygos System

- On both sides: the 1st space into brachiocephalic vein
- On left side:
 - The 2 to 4th spaces into left superior intercostal vein, then into the left brachiocephalic vein
 - The 5 to 8th into the accessory hemiazygos vein
 - The 9 to 12th spaces into the hemiazygos vein.



Grants, 1-74

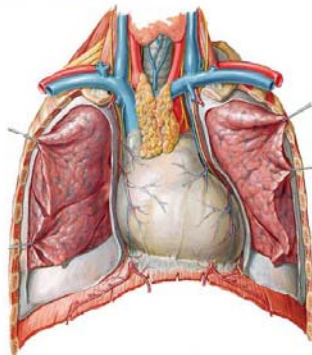
Slide 24.

On the left side, the 1st vein drains directly into the left brachiocephalic vein. Then, the veins in spaces 2 to 4 drain into the left superior intercostal vein which then empty into the left brachiocephalic vein. The veins from spaces 5 to 8 drain into the accessory hemiazygos vein with the veins from space 9 to 12 draining into the hemiazygos vein. Note how these last 2 major veins cross to the azygos vein on the right side.

Thoracic Cavity

The thoracic cavity has 3 compartments: the 2 pulmonary cavities (pleural cavities) and the mediastinum. This last one is a central compartment/partition containing the following thoracic structures:

- The heart
- The thoracic part of great vessels
- The thoracic part of trachea
- The thoracic part of esophagus
- The thymus
- Several nerves
- And lymphatics vessels



Netter 205

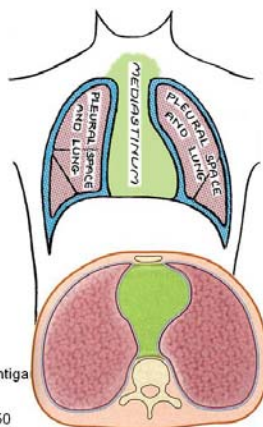
Slide 25.

The thoracic cavity has 3 compartments: the 2 pulmonary (pleural cavities), which contain the lungs and their surrounding pleural sacs and the mediastinum in between, which contains all the other thoracic structures.

Pleural Cavities and Mediastinum

The pleural cavities are closed serous sacs containing lungs (see lecture on thoracic contents).

The mediastinum is a movable compartment/partition between right and left pleural cavities extending from thoracic outlet and root of neck to diaphragm.



Brantiga

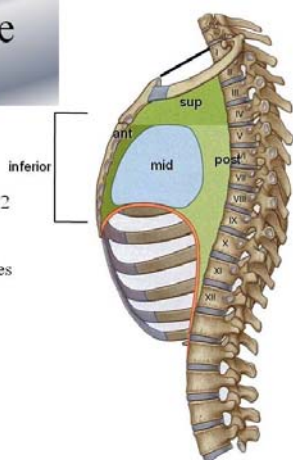
Drake (Gray) 3.50

Slide 26.

The mediastinum is a movable compartment, partitioning between the 2 pleural cavities. The pleural cavities are closed serous lined compartments. The mediastinum extends from the thoracic outlet and the root of the neck, superiorly, down to the diaphragm.

Divisions of the Mediastinum

- Superior border: suprasternal notch to upper border of T₁
- Inferior border: diaphragm
- Between sternum anteriorly and the 12 thoracic vertebrae posteriorly
- A line between the sternal angle and the disc between T₄ and T₅ divides the superior mediastinum from the inferior mediastinum
- The inferior mediastinum is further divided in 3 compartments:
 - Anterior mediastinum
 - Middle mediastinum
 - Posterior mediastinum



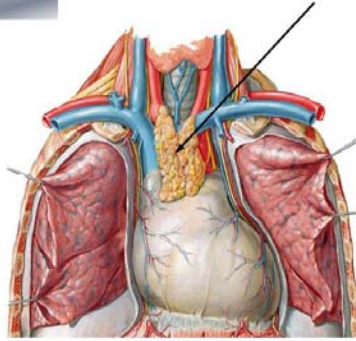
Drake (Gray) 3.52

Slide 27.

The mediastinum extends anteriorly from the sternum to the 12 thoracic vertebrae of the vertebral column posteriorly. The superior extent is a line drawn between the suprasternal notch of the manubrium to the upper border of the T₁ vertebral body. The inferior limit of the mediastinum is the diaphragm. A line between the sternal angle and the T₄/T₅ intervertebral disc divides the mediastinum in the superior and inferior mediastina. The inferior mediastinum is further divided by the pericardial sac and cavity into anterior, middle, and posterior mediastina.

Thymus

The thymus is the most anterior structure in the superior mediastinum. It is part of the immune system and is very active early in life. In the older adult, it remains sometimes as a mass of fatty tissue immediately posterior to the sternum. It can also sometimes extend down into anterior mediastinum.



Netter 205

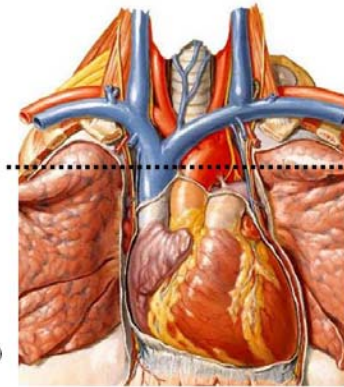
Slide 28.

The thymus (and/or its remnants) is the most anterior structure in the superior mediastinum. It usually extends down into the anterior mediastinum, just anterior to the upper part of the pericardium. The thymus is an important lymphoid organ that is large and active in infants and children. After puberty, the lymphoid tissue is largely replaced by fat. In the dissection lab, it is rare to find a discrete, well-developed thymus as seen in this figure.

Other Structures in Superior Mediastinum

- The superior vena cava (SVC):
 - Right brachiocephalic vein
 - Left brachiocephalic vein
- The aortic arch:
 - Brachiocephalic trunk
 - Left common carotid artery
 - Left subclavian artery
- The trachea
- The esophagus
- The thoracic duct
- The phrenic nerve
- The vagus nerve:
 - Left recurrent laryngeal nerve
 - (Right recurrent laryngeal nerve)

Netter 206



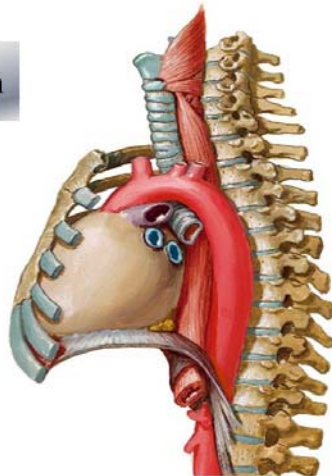
Slide 29.

In this figure, the thymus and the anterior wall of the pericardium have been cut away. The dotted line indicates the level of the sternal angle. Major structures in the superior mediastinum superior to the line include: superior vena cava (SVC) and its 2 large tributaries (the right and left brachiocephalic veins), the aortic arch and its 3 branches (the brachiocephalic trunk, the left common carotid artery, and the left subclavian artery), the trachea, the esophagus, the phrenic nerves, the vagus nerves and their recurrent laryngeal branches.

Inferior Mediastinum

- We can better appreciate on this lateral view the 3 compartments of the inferior mediastinum:
- The anterior mediastinum
 - The middle mediastinum
 - The posterior mediastinum.

Netter 227



Slide 30.

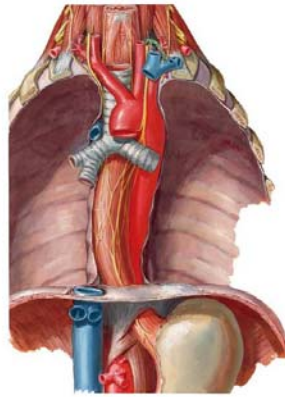This lateral view from Netter allows us to visualize the 3 subdivisions of the inferior mediastinum: the anterior, middle and posterior mediastinum.

Esophagus

Note the relationship of the esophagus with the trachea, the aorta and both vagus nerves.

Note also how it pierces the diaphragm to enter the stomach.

Netter 226



Slide 31.

The esophagus is a muscular tube that conveys food from the pharynx to the stomach. In the superior mediastinum, the esophagus is posterior to the trachea. In the posterior mediastinum, it passes posterior to the left bronchus and the left atrium. More distally, it lies anterior to the aorta. It passes posterior to part of the diaphragm, and then through the esophageal hiatus of the diaphragm to the stomach.

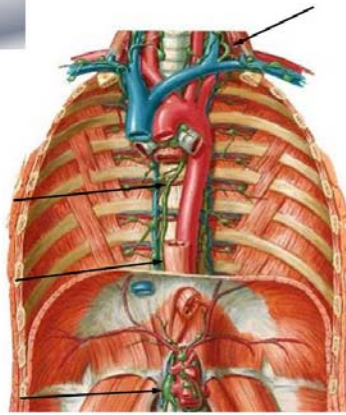
Note its relationship with the trachea, the aorta and both vagus nerves.

Thoracic Duct

The thoracic duct is the major lymphatic channel draining into the venous system. It begins in the abdomen (cisterna chyli) on the right side of the aorta. As it ascends, it passes through the aortic hiatus, then on the posterior aspect (right side) of the esophagus and crosses over to the left side when entering the superior mediastinum.

Recall that it drains into the left brachiocephalic vein, between the internal jugular and the subclavian vein.

Netter 259



Slide 32.

The thoracic duct drains into the venous system. It begins in the abdomen (cisterna chyli) on the right side of the aorta (at the level of about L₁). As it ascends, it passes with the aorta through the aortic hiatus of the diaphragm, then ascends on the posterior aspect (right side) of the esophagus to cross over to the left (at about the level of T₄) before entering the superior mediastinum to empty usually into the left brachiocephalic vein.

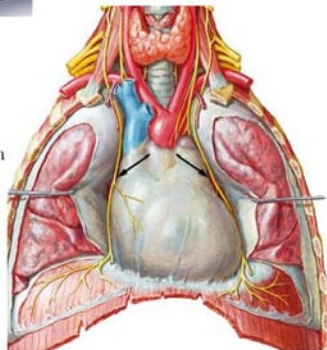
Phrenic Nerves

Recall that the phrenic nerve originates from C₃₋₅.

Observe on this drawing how it descends anterior to the roots of the lungs, between the pericardium and the pleura on each side.

Note how it distributes its branches to the mediastinal pleura and the dome of the diaphragm (see later).

Netter 205



Slide 33.

Recall that the phrenic nerves arise from the ventral primary rami of C₃₋₅. The phrenic nerve is the motor supply of the muscle of the diaphragm. The phrenic nerves descend between the pericardium and pleura on each side, anterior to the roots of the lungs. They distribute to the mediastinal pleura and then to the muscle of the dome of the diaphragm (see the thoracic contents lecture).

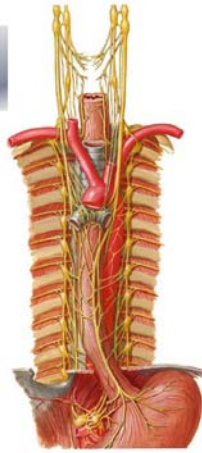
Vagus and Sympathetic Chain

Observe on this drawing the rotation of the left and right vagus nerves becoming as they pass down the anterior and the posterior vagus nerves.

Observe also here the right and the left sympathetic chains and the associated ganglia.

Note finally the thoracic splanchnic nerves branching off the sympathetic chains

Netter 234



Slide 34.

The right vagus nerve is anterior to the right subclavian artery, gives off its right recurrent laryngeal nerve branch (passes under the subclavian artery) and descends posterior to the right brachiocephalic vein, SVC, and root of the right lung. It continues along the esophagus as the posterior vagal trunk through the esophageal hiatus into the abdomen.

The left vagus nerve passes between left common carotid and subclavian arteries and descends anterior to the aortic arch. The left recurrent laryngeal nerve branch loops under the arch, lateral and posterior to the ligamentum arteriosum (an embryological remnant). The left vagus nerve continues posterior to the root of the left lung and along the esophagus as the anterior vagal trunk through the esophageal hiatus.

Observe also the right and left (paravertebral) sympathetic chains and associated structures (ganglia, white and grey rami communicantes) as well as the thoracic splanchnic nerves. Recall that preganglionic sympathetic fibers travel in greater splanchnic nerve (T₅₋₉), lesser splanchnic nerve (T₁₀₋₁₁), and least splanchnic nerve (T₁₂).

The End

Slide 35.

The End.

The Trachea, Bronchi and Lungs.

by Thierry Bacro, Ph.D

Center for Anatomical Studies and Education
Department of Regenerative Medicine and Cell Biology
College of Medicine
Medical University of South Carolina

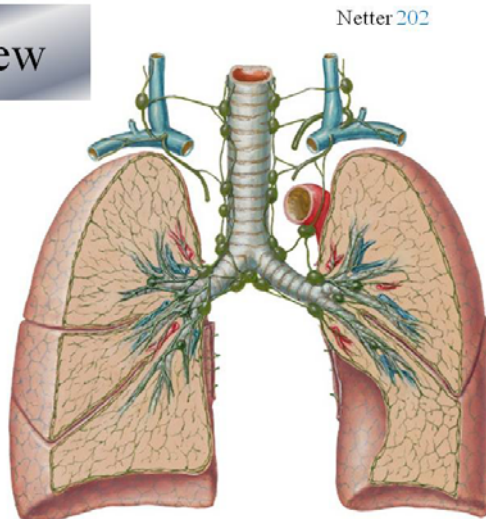
Slide 1.

In this lecture, we will discuss the gross anatomical structures of the respiratory system, namely the trachea, the bronchi, the lungs and the pleurae. We will end this lecture by introducing the mediastinum.

2

Overview

- Trachea
- Bronchi
- Lungs
- Pleurae
- Mediastinum.



Slide 2.

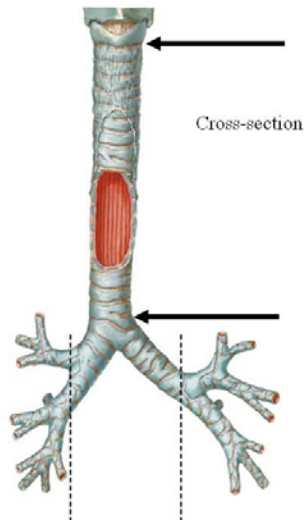
In this slide, please visualize the structures that will be discussed during the course of this lecture.

3

The Trachea

- Approximately 5 inches long, 1 inch wide, mobile cartilaginous and membranous tube
- Starting at the lower border of the cricoid cartilage
- Ending by branching into the right and the left main (primary) bronchi at the level of sternal angle.

Netter 196

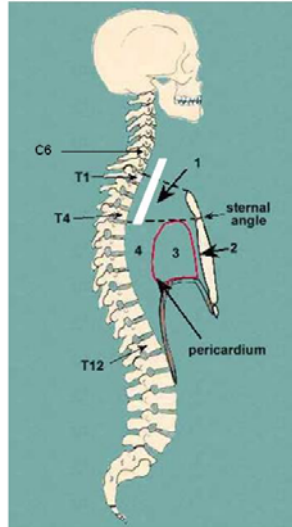

Slide 3.

First, let's turn our attention to the trachea. The trachea is an approximately 5 inches long, 1 inch wide, mobile cartilaginous and membranous tube starting at the lower border of the cricoid cartilage and ending by bifurcating (branching) into the right and the left main (primary) bronchi at the level of the sternal angle.

Level of the Trachea

- Start at the level of the cricoid cartilage, at the C₆ vertebra
- Ends at the bifurcation, between the 4th and 5th thoracic vertebrae (sternal angle).

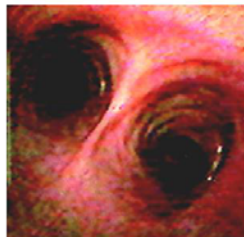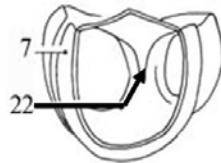


Slide 4.

Recall that the cricoid cartilage (upper end of the trachea) is at the level of the C₆ vertebra and the sternal angle (lower end of the trachea) is at the lower level of the 4th thoracic vertebra.

The Carina

Note that during a bronchoscopy, a keel-shaped anatomical structure, the carina can be observed at the level of the bifurcation. Note the left and the right primary bronchi.



Author Unknown

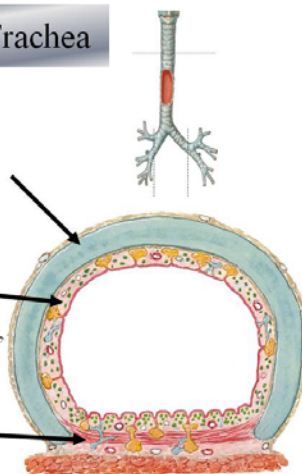
Slide 5.

Note that during a bronchoscopy, a keel-shaped anatomical structure, the carina can be observed at the level of the bifurcation. Note the left and the right primary bronchi.

Cross-section of the Trachea

- Has a fibroelastic wall with embedded series of U-shaped bars of hyaline cartilage keeping the lumen patent
- Has a mucosa lining the inside of the lumen
- Has a band of smooth muscle, the trachealis muscle, closing the posterior free end of the U-shaped cartilage.

Netter 196



Slide 6.

In this cross-section of the trachea, we can observe that the trachea:

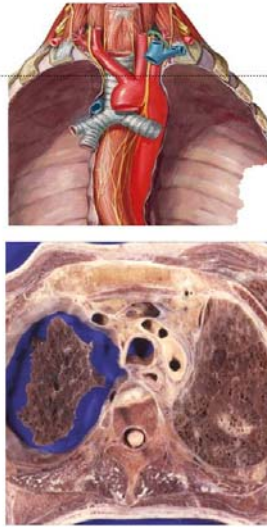
- Has a fibroelastic wall with an embedded series of U-shaped bars of hyaline cartilage keeping the lumen patent (open)
- Has a mucosa lining the inside lumen
- Has a band of smooth muscle, the trachealis muscle, closing the posterior free end of the U-shaped cartilage.

7

Relationships

- Anteriorly: the arch of the aorta and the left brachiocephalic vein (the sternum, the thymus, the left common carotid artery, the brachiocephalic trunk)
- Posteriorly: the esophagus, the left recurrent laryngeal nerve

Netter 226



Slide 7.

In terms of relationship, the trachea is surrounded by:

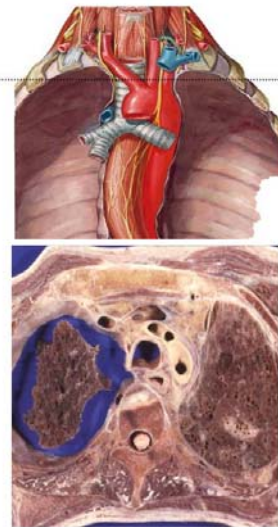
- Anteriorly: the brachiocephalic trunk and the arch of the aorta (the sternum, the thymus, the left common carotid artery, and left brachiocephalic vein)
- Posteriorly: the esophagus and the left recurrent laryngeal nerve.

8

Relationships

- On the right side: the azygos vein, the right vagus nerve and the pleura
- On the left side: the arch of the aorta, the left common carotid and left subclavian arteries, the left vagus, left phrenic nerve and pleura

Netter 226



Slide 8.

In terms of relationship, the trachea is surrounded by:

- On the right side: the azygos vein, the right vagus nerve and the pleura
- On the left side: the arch of the aorta, the left common carotid and left subclavian arteries, the left vagus, left phrenic nerve and pleura.

9

Nerve Supply of the Trachea

- The trachea receives branches from:
 - the vagus and the recurrent laryngeal nerves
 - the sympathetic trunks
- These branches are distributed to the:
 - the trachealis muscle
 - the mucous membrane lining the trachea.

Slide 9.

The trachea receives its innervation through branches of:

- The vagus and the recurrent laryngeal nerves
- The sympathetic trunks

These branches are distributed to the:

- The trachealis muscle
- The mucous membrane lining the trachea.

Nerve Supply of the Trachea

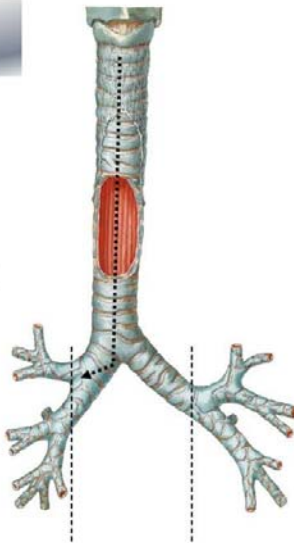
- The trachea receives branches from:
 - the vagus and the recurrent laryngeal nerves
 - the sympathetic trunks
- These branches are distributed to the:
 - the trachealis muscle
 - the mucous membrane lining the trachea.

10

Primary Bronchi

- Recall that the trachea divides into right and left primary bronchi
- Note that the right bronchus is wider, shorter and more vertical than the left bronchus
- This is clinically important as swallowed foreign objects (like peanuts...) will tend to lodge in the right bronchus.

Netter 196



Slide 10.

Recall that the trachea divides into right and left primary bronchi. Understand that the right lung divides into 3 lobes, the superior, the middle and the inferior lobe whereas the left lobe divides in 2 lobes, the superior and the inferior lobe with an additional structure not present in the right lung the lingual.

Note how the right bronchus is wider, shorter and more vertical than the left bronchus. This is clinically important as small swallowed foreign objects (like peanuts, coins, etc...) will have a higher probability of lodging themselves in the right bronchus than in the left bronchus.

Slide 11.

Observe that:

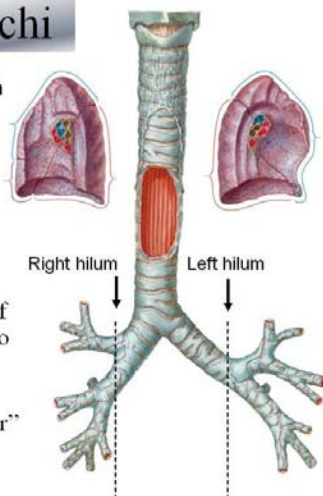
- The primary bronchi divide into secondary bronchi
- On the right side, the primary bronchus divides into a superior bronchus and an intermediate bronchus before entering the hilum of the right lung
- On the left side, the primary bronchus first enters the hilum of the left lung and then divides into a superior and an inferior bronchus
- The terms “secondary” and “lobar” bronchi are synonymous terms because the secondary bronchi ventilate the lobes of the right and left lungs.

11

Secondary Bronchi

- Observe how the primary bronch divide into secondary bronchi
- On the right side, the primary bronchus divides into a superior bronchus and an intermediate bronchus before entering the hilum of the right lung
- On the left side, the primary bronchus first enters the hilum of the left lung and then divides into a superior and an inferior bronchus
- Note that “secondary” and “lobar” bronchi are synonymous terms.

Netter 193 and 196



Slide 12.

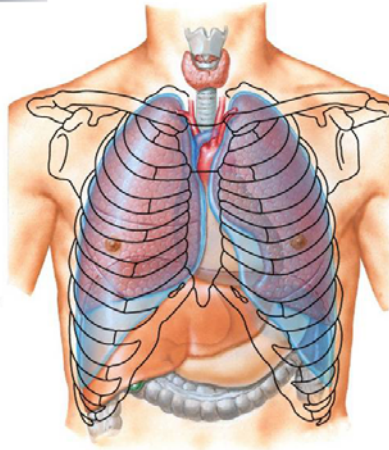
The secondary bronchi further divide into tertiary bronchi, also called segmental bronchi because they ventilate the bronchopulmonary segments of the lungs (see next). Note that the bronchi continue to undergo division until the level of the terminal bronchiole (up to a total of 27 divisions)..

13

The Lungs

Netter 190

- Are found on each side of the mediastinum
- Are separated by the heart, great vessels and the other structures found in the mediastinum
- Each lung is conical in shape, covered with a visceral pleura and suspended by its root
- Also has an apex, a concave base that sits on the diaphragm, a convex costal surface and a concave mediastinal surface.



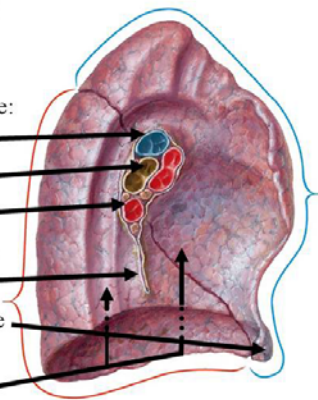
14

The Left Lung

[View a video describing the left lung](#)

Netter 193

- Two lobes (superior and inferior) separated by a single oblique fissure
- A root allowing the passage of the:
 - Left pulmonary artery
 - Left pulmonary bronchus
 - Left pulmonary veins
- The pulmonary ligament, inferior extension of the sleeve of pleura
- The lingula, at the lower tip of the superior lobe
- Note the multiple impressions.



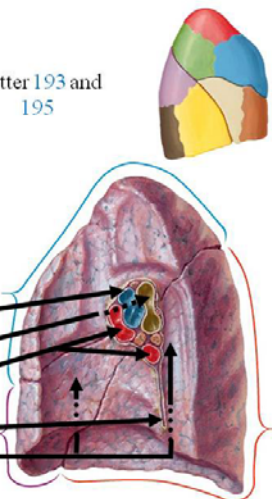
15

The Right Lung

[View a video describing the right lung](#)

Netter 193 and 195

- Review the 3 lobes (superior, middle, inferior)
- Observe the oblique and the horizontal fissures
- Note how the structures present in the right root differ from the root in the left lung :
 - Right pulmonary artery
 - Right pulmonary bronchus
 - Right pulmonary veins
- The pulmonary ligament
- Note the multiple impressions.



Slide 13.

The lungs are found on each side of the mediastinum. They are separated by the heart, the great vessels and the other structures found in the mediastinum.

Note that each lung:

- Is conical in shape, covered with a visceral pleura and suspended by its root
- Has an apex, a concave base that sits on the diaphragm, a convex costal surface and a concave mediastinal surface.

Slide 14.

As already described, the left lung has two lobes (superior and inferior) separated by a single oblique fissure. The root of the lung allows the passage through the hilum of the lung of the left pulmonary artery, the left pulmonary bronchus and the left pulmonary veins. The pulmonary ligament, an inferior extension of the sleeve of pleura (where the mediastinal fuses with the visceral layer) allows the up and down movement of the root of the lung during breathing. The lingula, found immediately anterior to the cardiac impression is the lowest and most anterior part of the superior lobe of the left lung. Note the other multiple impressions of the medial surface of the left lung.

Slide 15.

Recall that the right lung has 3 lobes (superior, middle, inferior). Like the left lung, the right lung has an oblique fissure. Note the additional horizontal fissure at the level of the 4th intercostal space, running on the lateral aspect of the lung to cross the oblique fissure at the level of the mid-axillary line. Note the structures in the root of the right lung: the right pulmonary artery, the right pulmonary bronchus, and the right pulmonary veins. Finally note the pulmonary ligament (see later) and the multiple impressions also present on the medial surface of the right lung.

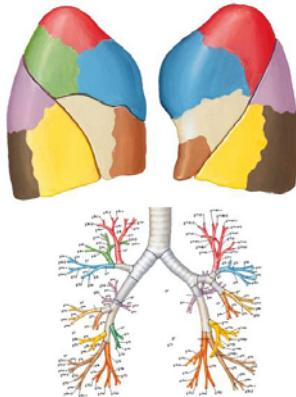
Observe also how the structures present in the root of the right lung differ from the structures in the root of the left lung. The pulmonary veins lie inferior and anterior in the roots of the left and the right lung. Note however how the left pulmonary artery lies superior in the left lung whereas the right pulmonary artery lies anterior to the right bronchi in the right lung. Please review the video-clips comparing the right lung to the left lung.

16

The Bronchopulmonary Segment

- Is the anatomical, functional and surgical unit of the lung
- Is ventilated by a tertiary (segmental) bronchi
- Receives a branch of the pulmonary artery, and has its own lymphatic vessels and autonomic nerve supply
- Does not contain the vein!

Netter 195 and 197



Slide 16.

Note on this drawing how the pulmonary vein lies in the connective tissue between adjacent BPS. The pulmonary veins are intersegmental.

Slide 17.

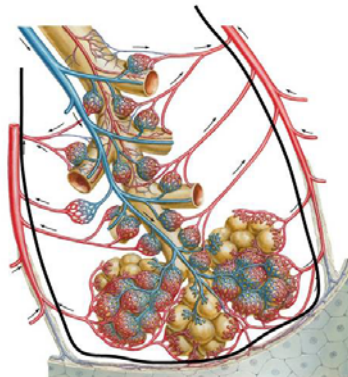
The bronchopulmonary segment (BPS) is the anatomical, functional and surgical unit of the lung. Each BPS is ventilated by a tertiary (segmental) bronchi. It receives a branch of the pulmonary artery, vein and has its own lymphatic vessels and autonomic nerve supply.

17

The Bronchopulmonary Segment

Note on this drawing how the pulmonary vein lies in the connective tissue between adjacent BPS.

Netter 199



Slide 18.

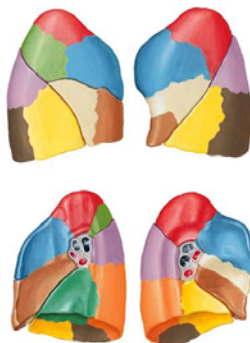The right lung has 10 BPS that can be regrouped as follows:

- Superior lobe:
 - Apical
 - Posterior
 - Anterior
- Middle lobe:
 - Lateral
 - Medial
- Inferior lobe:
 - Superior
 - Medial basal
 - Anterior basal
 - Lateral basal
 - Posterior basal

18

Right lung = 10

- Superior lobe:
 - apical
 - posterior
 - anterior
- Middle lobe:
 - lateral
 - medial
- Inferior lobe:
 - superior
 - medial basal
 - ant basal
 - lateral basal
 - posterior basal



Netter 195

Left lung = 8

- Superior lobe:
 - apical-posterior
 - anterior
- Lingula:
 - superior
 - inferior
- Inferior lobe:
 - superior
 - anteromedial basal
 - lateral basal
 - posterior basal

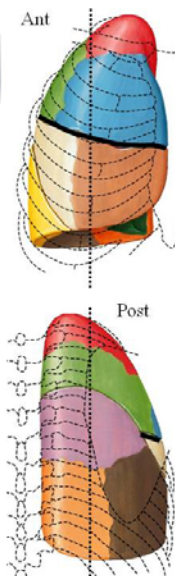
The left lung has 8 BPS:

- Superior lobe:
 - Apical-posterior
 - Anterior
- Lingula:
 - Superior
 - Inferior
- Inferior lobe:
 - Superior
 - Anteromedial basal
 - Lateral basal

Surface Markings of Right Lung

- Apex projects 1 inch above the level of the clavicle
- The anterior border starts under the sternoclavicular joint, passes downward to the sternal angle, then continue down to the level of the xiphisternal joint where it turns out laterally
- Anteriorly, the lower border is at the 6th rib (midclavicular line)
- Laterally, the lower border is at the level of the 8th rib (midaxillary line)
- Posteriorly, the lower border is at the 10th rib
- Note the horizontal fissure at the level of the 4th rib.

Netter 194



Slide 19.

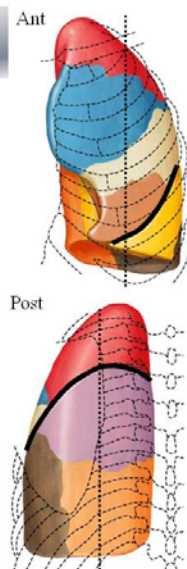
Observe the surface markings of the right lung on the thorax. Note that:

- The apex projects one inch above the level of the clavicle
- Anteriorly, the border starts under the sternoclavicular joint, then passes downward to the sternal angle, continue down to the level of the xiphisternal joint where it turns out laterally
- Anteriorly, the lower border is at the level of 6th rib (at the midclavicular line)
- Laterally, the lower border is at the level of the 8th rib
- Posteriorly, the lower border is at the 10th rib
- The horizontal fissure is at the level of the 4th rib.

Surface Markings of Left Lung

- Apex also projects 1 inch above the level of the clavicle
- The anterior border starts under the sternoclavicular joint, passes downward to the sternal angle, but deviates laterally at the level of the 4th intercostal space (4th rib)
- Forms the cardiac notch by extending for a variable distance beyond the lateral margin of the sternum
- Continues down toward the level of the xiphisternal joint to form the lingula
- Like for the left lung, the lower border can be found anteriorly at the 6th rib (midclavicular line), laterally at the 8th rib (midaxillary line) and posteriorly at the 10th rib
- Note that the oblique fissure (on both lungs) starts at the root of the spine of the scapula and runs downward, laterally and anteriorly to the 6th rib.

Netter 194



Slide 20.

Observe the surface markings of the right lung on the thorax. Note that:

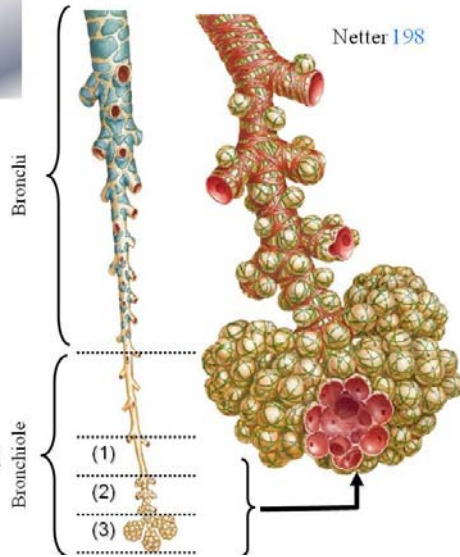
- the apex of the left lung also projects one inch above the level of the clavicle
- Anteriorly, the border starts under sternoclavicular joint, passes downward to the sternal angle, but deviates laterally at the level of the 4th intercostal space (4th rib)
- The anterior border then forms the cardiac notch by extending for a variable distance beyond the lateral margin of the sternum

- It then continues down toward the level of the xiphisternal joint to form the lingula
- Like for the left lung, the lower border can be found anteriorly at the 6th rib (midclavicular line), laterally at the 8th rib (midaxillary line) and posteriorly at the 10th rib
- Note that the oblique fissure (on both lungs) starts at the root of the spine of the scapula and runs downward, laterally and anteriorly to the 6th rib.

21

Terminal Bronchiole

- Segmental bronchi divide repeatedly when entering a BPS
- U-shaped cartilage becomes plates of cartilage
- Cartilage finally disappear at the level of the bronchiole
- Ends as terminal bronchiole (1) (no cartilage, has elastic fiber, smooth muscle and is lined by ciliated epithelium).



Slide 21.

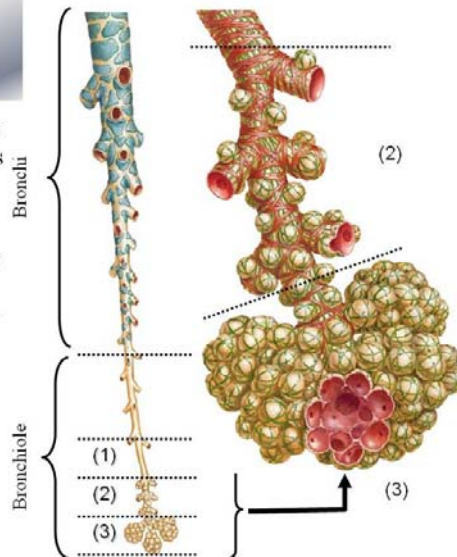
Each segmental bronchus divides repeatedly when entering a BPS. The U-shaped cartilages bars are gradually replaced by irregular plates of cartilage that finally disappear at the level of the bronchiole. At the level of the terminal bronchiole, the walls have no cartilage but consist of elastic fiber, smooth muscle and are lined by ciliated epithelium.

22

Terminal Bronchiole

- Respiratory bronchioles are terminal bronchioles presenting with alveoli in their walls
- These end by branching into alveolar ducts leading then to alveolar sacs formed of numerous alveoli
- The gaseous exchange take place through the alveolar walls.

Netter 198



Slide 22.

The respiratory bronchioles are terminal bronchioles presenting with alveoli in their walls. These terminal bronchioles end by branching into alveolar ducts that lead into tubular passages with numerous thin-walled outpouchings called alveolar sacs. Each alveolar sac consists of several alveoli opening in the central chamber. The gaseous exchange takes place between the air in the alveolar lumen and the blood in the capillaries surrounding the alveolar sacs.

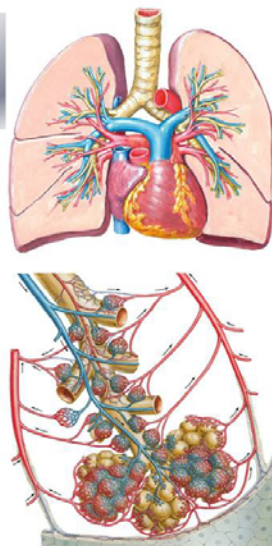
23

Intrapulmonary Blood Circulation

The pulmonary arteries (from the right side of the heart) bring the deoxygenated blood to a capillary bed in the wall of the alveoli where gaseous exchange takes place.

The pulmonary veins then return the oxygenated blood to the left side of the heart.

Netter 198 and 206



Slide 23.

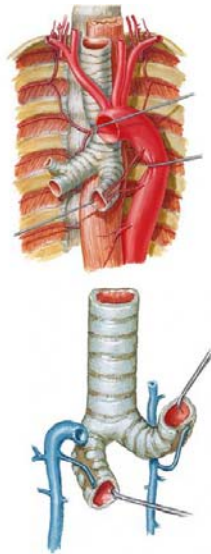
The pulmonary arteries (from the right side of the heart) bring the deoxygenated blood to a capillary bed in the wall of the alveoli where gaseous exchange takes place. The pulmonary veins then return the oxygenated blood to the left side of the heart.

Blood Supply of the Lungs

The bronchi and the connective tissue of the lungs (as well as the visceral pleura: see later) receive their blood supply from the bronchial arteries which are branches of the descending aorta.

The venous return is done by bronchial veins which drain into the azygos vein on the right side and hemiazygos vein on the left side.

Netter 201

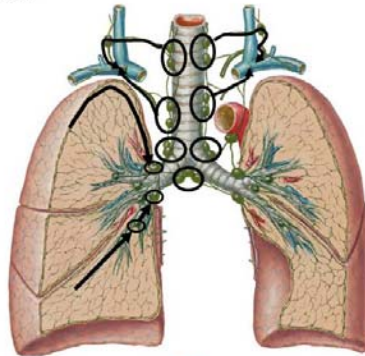


Slide 24.

The bronchi and the connective tissue of the lungs (as well as the visceral pleura: see later) receive their blood supply from the bronchial arteries, branches of the descending aorta. The venous return is done by bronchial veins, which drain into the azygos vein on the right side and hemiazygos vein on the left side.

Lymphatic Drainage of the Lungs

- Superficial plexus draining below the visceral pleura toward the hilum, in the bronchopulmonary nodes
- Deep plexus draining the bronchi and pulmonary vessels toward the hilum, in the pulmonary and then the bronchopulmonary nodes
- The lymph leaves the hilum to drain into the tracheobronchial nodes, the paratracheal nodes, and the bronchiomediastinal trunks
- These trunks drain either directly or indirectly into the brachiocephalic veins (through the inferior deep cervical nodes).



Netter 202

Slide 25.

The lymph vessels originate in the superficial and deep plexuses. Note that are not present in the alveolar wall::

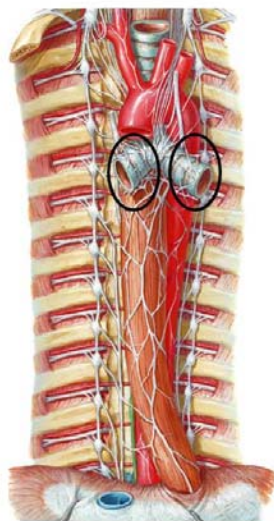- The superficial plexus drains below the visceral pleura toward the hilum, in the bronchopulmonary nodes
- The deep plexus drains the bronchi and pulmonary vessels toward the hilum, in the pulmonary and then the bronchopulmonary nodes
- The lymph then leaves the hilum to drain into the tracheobronchial nodes, the paratracheal nodes, and the bronchiomediastinal trunks
- These bronchiomediastinal trunks drain either directly or indirectly into the brachiocephalic veins (through the inferior deep cervical nodes and the jugular lymphatic trunk on the right side and the thoracic duct on the left side).

Nerve Supply of the Lungs

Observe the presence of a pulmonary plexus at the root of each lung.

Each plexus is composed of efferent and afferent autonomic fibers and is formed by branches of the sympathetic trunks and from the vagus nerves.

Netter 203



Slide 26.

In this slide, observe the presence of a pulmonary plexus at the root of each lung (each pulmonary plexus has an anterior and a posterior component). Each plexus is composed of efferent and afferent autonomic fibers and is formed by branches of the sympathetic trunks and from the vagus nerve.

Nerve Supply of the Lungs

The sympathetic efferent fibers induce bronchodilation of the bronchi and vasoconstriction.

The parasympathetic efferent fibers induce bronchoconstriction, vasodilation and increased glandular secretion.

The afferent fibers carry information from the mucous membranes and from stretch receptors in the alveolar walls to the central nervous system through both sympathetic and parasympathetic fibers.

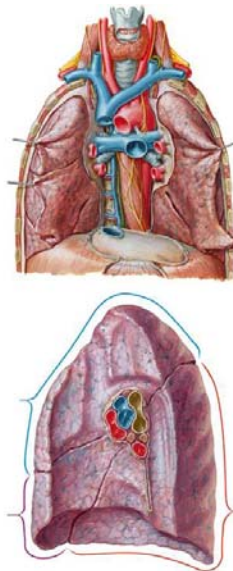
Pleurae

Netter 200
and 193

Each pleura is composed of two layers:

- a parietal pleura: lining the thoracic wall, covering the thoracic surface of the mediastinum and extending into the root of the lung
- a visceral pleura: completely covering the outer surfaces of the lung and extending into the interlobar fissures

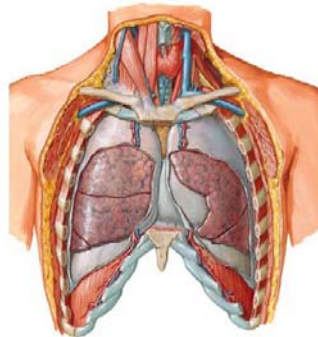
Note that these two layers become continuous with one another at the hilum of the lung, forming a pleural cuff. To allow for movement of the pulmonary vessels and bronchi during respiration, this cuff hangs down as a loose fold called the pulmonary ligament.



Costal and Parietal Pleurae

- Visceral pleura
- Parietal pleura:
 - Cervical pleura: extending up in the neck
 - Costal pleura: lining the inner surfaces of the ribs, the costal cartilages, the intercostal spaces, the sides of the vertebral bodies and the back of the sternum
 - Diaphragmatic pleura: covers the thoracic surface of the diaphragm
 - Mediastinal pleura: covers (forms) the lateral border of the mediastinum.

Netter 192



Slide 27.

The sympathetic efferent fibers induce bronchodilation of the bronchi and vasoconstriction. The parasympathetic efferent fibers induce bronchoconstriction, vasodilation and increased glandular secretion. The afferent fibers carry information from the mucous membranes and from stretch receptors in the alveolar walls to the central nervous system through both sympathetic and parasympathetic fibers.

Slide 28.

Observe how each pleura is composed of two layers:

- A parietal pleura: lining the thoracic wall, covering the thoracic surface of the mediastinum and extending into the root of the lung
- A visceral pleura: completely covering the outer surfaces of the lung and extending into the interlobar fissures.

Note that these two layers become continuous with one another at the hilum of the lung, forming a pleural cuff. To allow for movement of the pulmonary vessels and bronchi during respiration, this cuff hangs down as a loose fold called the pulmonary ligament.

Slide 29.

On this slide, observe how the visceral pleura simply covers the lungs and how the parietal pleura can be divided in:

- Cervical pleura: extending up in the neck
- Costal pleura: lining the inner surfaces of the ribs, the costal cartilages, the intercostal spaces, the sides of the vertebral bodies and the back of the sternum
- Diaphragmatic pleura: covering the thoracic surface of the diaphragm
- Mediastinal pleura: covering (forming) the lateral border of the mediastinum.

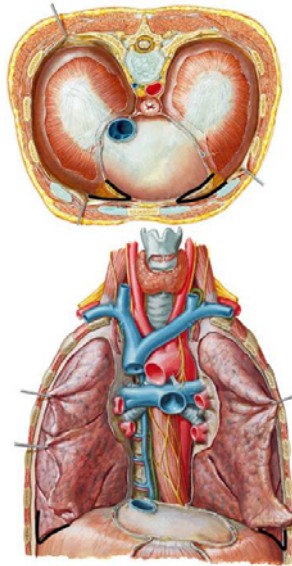
30

Pleural Cavity and Recesses

The parietal and visceral layers are separated by a slitlike space, the pleural cavity, containing a small amount of fluid called the pleural fluid. This fluid permits the two layers to move on each other.

Note the existence of the costodiaphragmatic and costomediastinal recesses.

Netter 188 and 200



Slide 30.

The parietal and visceral layers are separated by a slit-like space, the pleural cavity, containing a small amount of fluid called the pleural fluid. This fluid permits the two layers to move on each other.

Note the existence of the costodiaphragmatic and costomediastinal recesses. The costodiaphragmatic recesses are slit-like spaces between the costal and diaphragmatic pleurae. They are separated by a thin layer of pleural fluid. During inspiration, the lower borders of the lungs descend into these recesses, separating the costal and diaphragmatic pleurae. The costomediastinal recesses are slit-like spaces situated between the costal and mediastinal pleurae. During inspiration, the anterior borders of the lungs slide in these recesses.

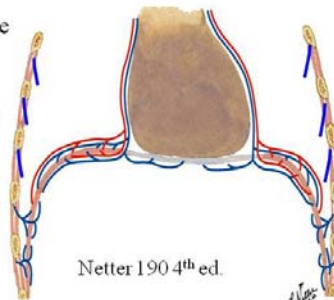
31

Nerve Supply to the Pleurae

Note that the parietal pleura is sensitive to pain, temperature, touch, and pressure. It is supplied by:

- The phrenic nerve: to the mediastinal pleura and the dome of the diaphragmatic pleura
- The intercostal nerves supply the costal pleura segmentally with the lowest 6th intercostal nerves innervating the periphery of the diaphragmatic pleura.

The visceral pleura receive autonomic innervation from the pulmonary plexuses. It is sensitive to stretch but not to temperature, pain and touch.



Netter 190 4th ed.

Slide 31.

Note that the parietal pleura is sensitive to pain, temperature, touch, and pressure. It is supplied by:

- The phrenic nerve: to the mediastinal pleura and the dome of the diaphragmatic pleura
- The intercostal nerves supply the costal pleura segmentally with the lowest 6th intercostal nerves innervating the periphery of the diaphragmatic pleura.

The visceral pleura receive autonomic innervation from the pulmonary plexuses. It is sensitive to stretch but not temperature, pain and touch.

32

Breathing

- The 2 pleurae are able to slide on one another.
 - The parietal pleura is tightly adherent to the chest wall
 - The lungs are tightly adherent to the internal aspect of the visceral pleura
- => Any movement of the chest wall will translate in change in lung size.

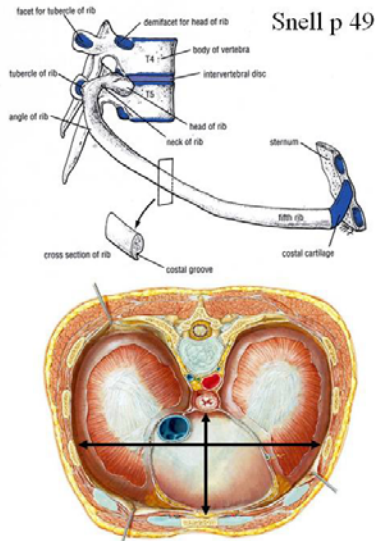
Slide 32

As already discussed in this lecture, the 2 pleurae are able to slide on one another. Due the fact that, under normal conditions, the parietal pleura is tightly adherent to the chest wall and the lungs are tightly adherent to the internal aspect of the visceral pleura, any movement of the chest wall will translate in change in lung size.

Increases

- In anteroposterior diameter by raising the sternal end of the ribs
- In transverse diameter by raising the ribs at the costo-vertebral joints
- By descending the diaphragm (see next slide).

Netter 188



Snell p 49

Slide 33.

During breathing, the muscles acting on the chest wall will increase the following:

- The anteroposterior diameter by raising the sternal end of the ribs (pump effect)
- The transverse diameter by raising the ribs at the costo-vertebral joints (bucket handle)
- The supero-inferior height by descending the diaphragm (see next slide)..

Breathing Mechanisms

By descending the diaphragm with the bifurcation of the trachea lowering as much as 2 vertebral levels. Note also the drop in the domes of the diaphragm.

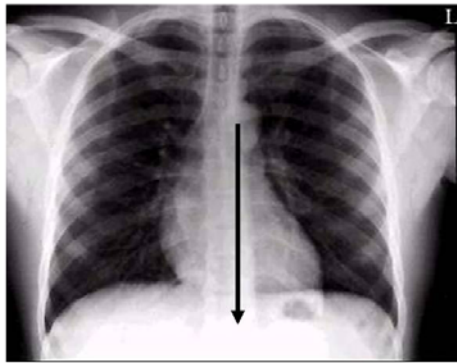


Image captured from Internet

Slide 34.

During the inspiration phase of breathing, the diaphragm will contract and descend, with the bifurcation of the trachea lowering as much as 2 vertebral levels. Note also the descent of the domes of the diaphragm. Under normal conditions, this process will decrease the pressure inside the lungs when compared to the outside atmosphere pressure and will draw air into the lungs.

Muscles in Inspiration

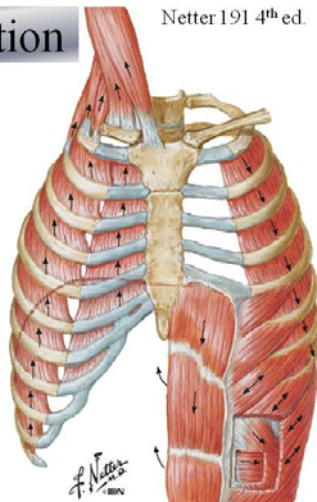
Netter 191 4th ed.

Quiet inspiration:

- Diaphragm
- Intercostals

Forced inspiration:

- SCM
- Scalenes
- Muscles stabilizing the scapula (serratus anterior, trapezius, etc).



Slide 35.

The muscles active during quiet inspiration are the diaphragm and the intercostal muscles. When necessary (i.e. increased levels of activity), additional muscles can be recruited to assist with forced inspiration: the sternocleidomastoid, the 3 scalenes (anterior, middle and posterior) and the muscles stabilizing the scapula (serratus anterior, trapezius, rhomboids, pectoralis minor).

Muscles in Expiration

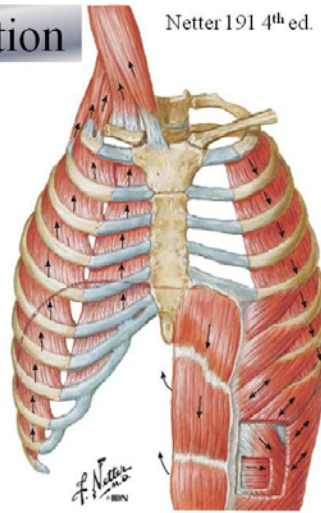
Netter 191 4th ed.

Quiet expiration:

- Is a passive mechanism (elastic recoil of the lungs)

Forced expiration:

- Intercostals
- Abdominal muscles
- Quadratus lumborum.



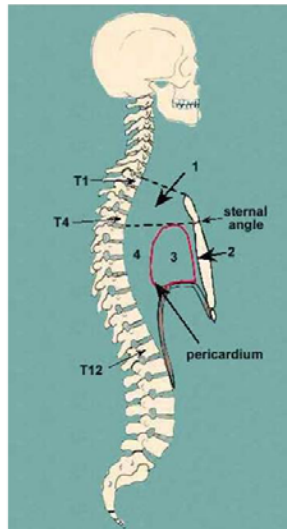
Slide 36

Quiet expiration is a passive mechanism, essentially due to the elastic recoil of the expanded lungs and associated wall structures (cartilages, ribs, etc). Additional muscles can also be recruited to assist with forced expiration: the intercostals, the abdominal muscles and the quadratus lumborum.

Mediastinum

Recall that the mediastinum is a movable partition extending superiorly to the thoracic outlet and the root of the neck and inferiorly to the diaphragm. It extends anteriorly to the sternum and posteriorly to the 12 thoracic vertebrae of the vertebral column.

The mediastinum is divided into superior (1) and inferior mediastina, with the inferior mediastinum further divided into anterior (2), middle (3) and posterior mediastina (4).



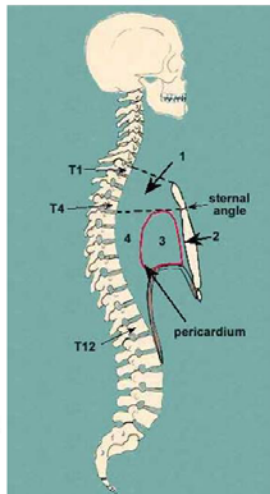<http://mywebpages.comcast.net/wnor/homepage.htm>

Slide 37.

Recall that the mediastinum is a movable partition extending superiorly to the thoracic outlet and the root of the neck and inferiorly to the diaphragm. It extends anteriorly to the sternum and posteriorly to the 12 thoracic vertebrae of the vertebral column. The mediastinum is divided into superior (1) and inferior mediastina, with the inferior mediastinum further divided into anterior (2), middle (3) and posterior mediastina (4).

Mediastinum

The superior border of the mediastinum is an imaginary line between the suprasternal notch and the upper border of T₁ thoracic vertebra, with the inferior border being the diaphragm muscle. A line between the sternal angle and the disc between the T₄ and T₅ vertebrae divides the mediastinum into the superior and inferior compartments. Note how the inferior compartment is further subdivided by the pericardium in the anterior, middle and posterior compartments.



<http://mywebpages.comcast.net/wnor/homepage.htm>

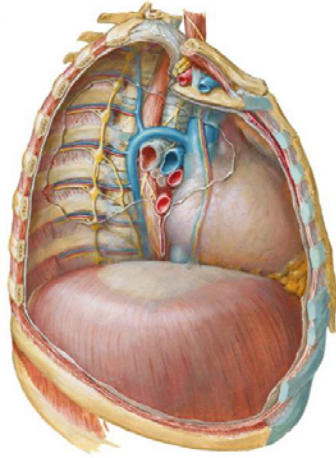
Slide 38.

The superior border of the mediastinum is an imaginary line between the suprasternal notch and the upper border of T₁ thoracic vertebra, with the inferior border being the diaphragm muscle. A line between the sternal angle and the disc between the T₄ and T₅ vertebrae divides the mediastinum into the superior and inferior compartments. Note how the inferior compartment is further subdivided by the pericardium into the anterior, middle and posterior compartments.

Mediastinum

The contents of each compartment of the mediastinum will be discussed in the next lecture.

Netter 224



Slide 39.

The contents of each compartment of the mediastinum will be discussed in the next lecture.

Slide 40.

The End.

The Heart

by Thierry Bacro, Ph.D

Center for Anatomical Studies and Education
Department of Regenerative Medicine and Cell Biology
College of Medicine
Medical University of South Carolina

2

Lecture Summary

1. Middle Mediastinum
2. Chamber & Flow Overview
3. Heart Orientation
4. Great Vessels
5. Pericardium: Fibrous vs. Parietal vs. Visceral
6. Pericardial Reflections and Sinuses
7. Posterior and Inferior Relationships
8. Chambers: RA, RV, LA, LV
9. Heart Valves: Tricuspid, Mitral, Pulmonic, Aortic
10. Coronary Vessels
11. Innervation: Sympathetics vs. Parasympathetics vs. Afferents
12. Conduction System
13. Radiologic View

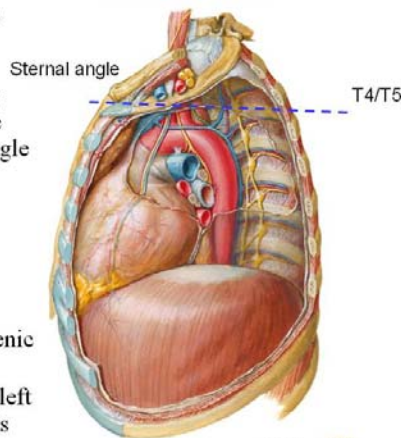
Slide 2.

In this lecture, we will start by reviewing the mediastinum. We will continue by having an introduction to the blood flow through the main chambers of the heart and will continue with a discussion of the great vessels, the pericardium, the contents of the main chambers, the coronary vessels and will finish the lecture with the innervation of the heart and its conduction system. We will end the lecture with a brief clinical discussion related to the heart.

3

Middle Mediastinum

- Part of inferior mediastinum along with anterior and posterior areas
- Between the pleural cavities and inferior to the transverse plane between the sternal angle and T₄/T₅.
- Contains:
 - Pericardium
 - Heart
 - Origins of great vessels
 - Nerves: right and left phrenic nerves, cardiac plexuses
 - Smaller vessels: right and left pericardiophrenic vessels



Slide 3.

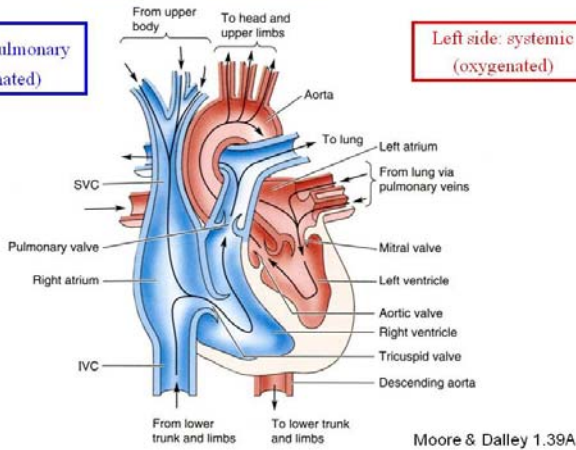
The mediastinum is the partition within the thorax between the pleural cavities inferior to the thoracic inlet (first ribs) and above the diaphragm. The mediastinum is separated into superior and inferior sections. The inferior section is further divided into anterior, middle, and posterior areas. The heart and related contents are located within the middle mediastinum. The middle mediastinum is the space inferior to the transverse plane connecting the sternal angle to the T₄/T₅ intervertebral discs and superior to the diaphragm. Contents of the middle mediastinum include the pericardium, heart, origins of the great vessels, nerves, and smaller vessels

4

Overview

Right side: pulmonary
(deoxygenated)

Left side: systemic
(oxygenated)



Moore & Dalley 1.39A

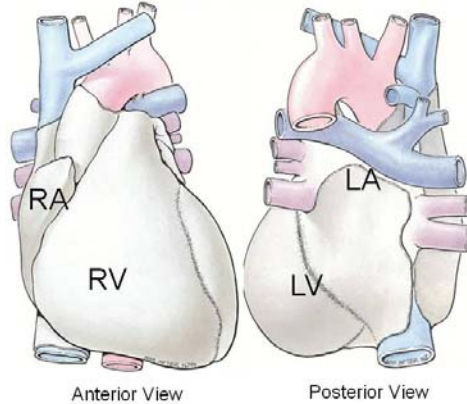
Slide 4.

The heart is composed of four chambers and four valves. The chambers are the right atrium, right ventricle, left atrium, and left ventricle. The valves are the tricuspid, pulmonic, mitral, and aortic. The deoxygenated blood enters the right atrium via the SVC, IVC, and coronary sinus (drains the coronary vessels). It passes through the tricuspid valve to enter the right ventricle and is pumped through the pulmonic valve and the pulmonary arteries to the lungs. The oxygenated blood from the lungs is carried back to the heart via the four pulmonary veins and enters the left atrium. Blood passes through the mitral valve to enter the left ventricle, and is then pumped through the aortic valve and aorta to enter systemic circulation.

5

Orientation of the Heart

- Right Atrium:
 - Right lateral margin
- Right Ventricle:
 - Anterior surface
- Left Atrium:
 - Posterior surface
- Left ventricle:
 - Diaphragmatic surface



Grant 10th ed., 1.43 A&B

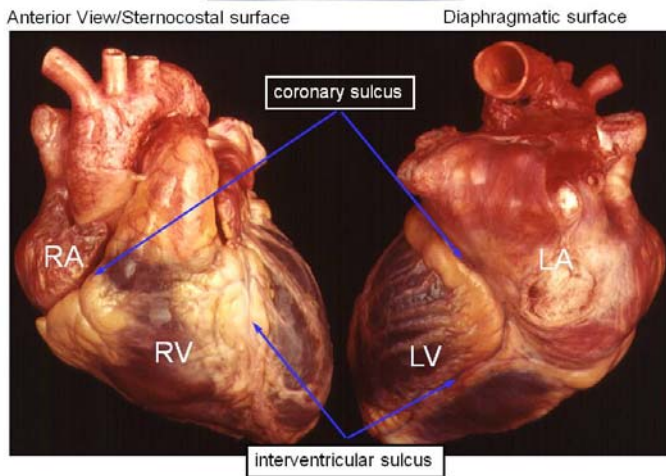
Slide 5.

Note that each chamber has its own association with a direction. The right atrium is the most right lateral border while the right ventricle makes up the majority of the anterior surface (the sternocostal surface). The left atrium is the posterior surface of the heart while the left ventricle comprises the diaphragmatic surface. The superior aspect of the anterior surface of the heart is notable for a visualization of the origins of the great vessels: superior vena cava, aorta, and pulmonary trunk. The superior aspect of the posterior surface, the left atrium, is notable for the visualization of the four pulmonary veins.

6

Orientation

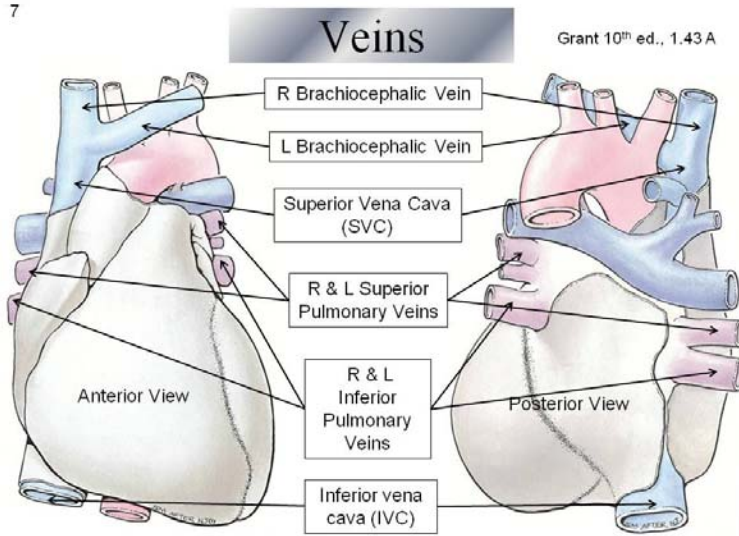
Rohen & Yokochi 252



Slide 6.

The orientation of the chambers can be further achieved by following the sulci or grooves formed from fusion of the muscular walls during development. The coronary sulcus is the groove separating the atriums from ventricles and can be seen in slide 6 running between the right auricle and the right edge of the pulmonary trunk. The anterior interventricular sulcus is the groove separating the ventricles on the anterior surface while the posterior interventricular sulcus separates the ventricles on the diaphragmatic surface.

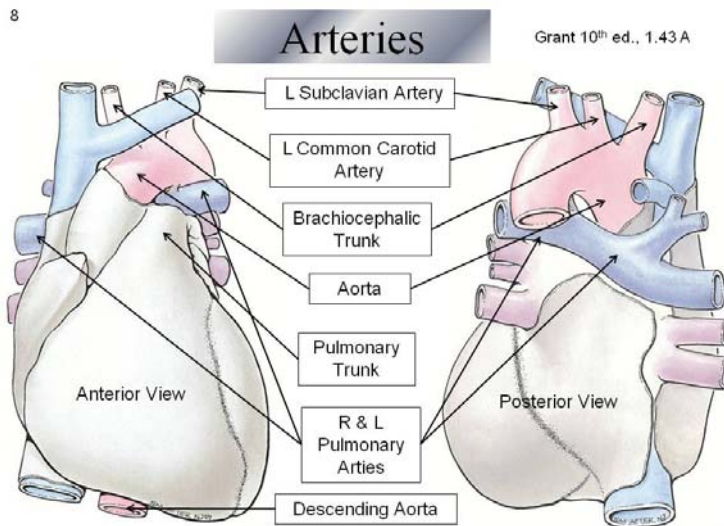
7



Slide 7.

This slide shows the anterior and posterior views of the great veins as they enter the heart. Following the order of flow, the venous return from the upper limbs and head and neck meets at the junction of the right and left brachiocephalic veins with the SVC then enters the right atrium. The venous flow from the lower limbs, abdomen, and pelvis returns through the inferior vena cava and enters the right atrium. Newly oxygenated blood returns to the left atrium via the right and left superior and inferior pulmonary veins. These veins are unique in that they carry oxygenated blood unlike other adult veins.

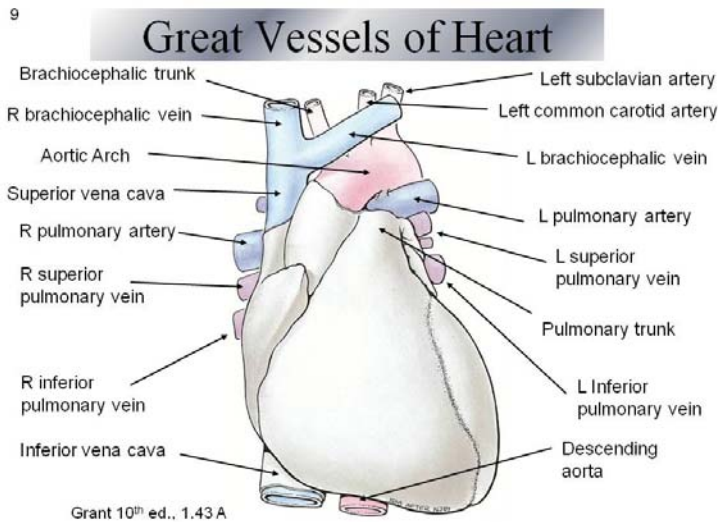
8



Slide 8.

This slide shows the anterior and posterior views of the great arteries of the heart. The deoxygenated blood leaves the heart and travels to the lungs via the pulmonary trunk and the right and left pulmonary arteries. These arteries are also unique as they are the only adult arteries carrying deoxygenated blood. The blood is returned to the systemic circulation via the aorta arch which gives rise to the brachiocephalic trunk, the left common carotid artery, and left subclavian artery. The brachiocephalic trunk supplies blood to the right upper limb and head via the right subclavian artery and right common carotid artery respectively. The left common carotid artery then supplies the left head and neck while the left subclavian artery supplies the left upper limb.

9

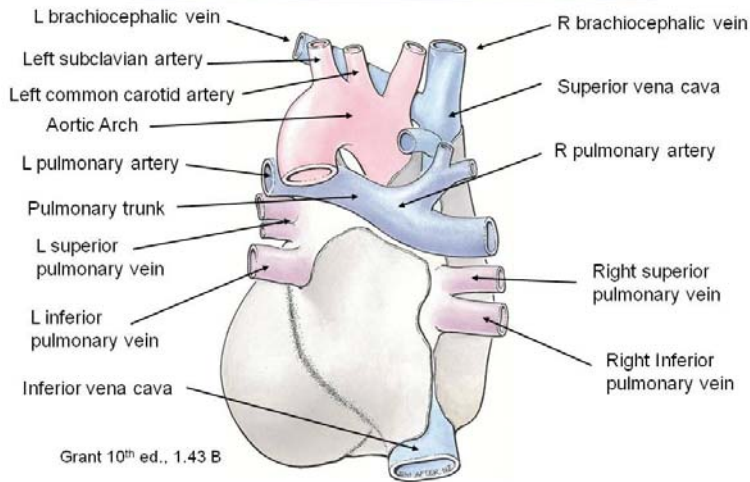


Slide 9.

This view combines the anterior view of the arteries and veins of the heart.

10

Great Vessels of Heart



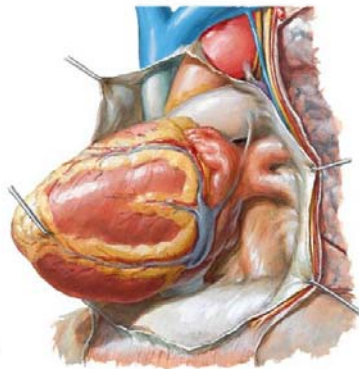
Slide 10.

This view combines the posterior view of the arteries and veins of the heart.

11

Pericardium

- 1) Outer wall:
 - Fibrous pericardium
 - Parietal layer of serous pericardium
- 2) Inner wall:
 - visceral layer of serous pericardium is on the surface of the heart and extends to proximal parts of great vessels, is continuous with the parietal layer at the great vessels to form reflections.



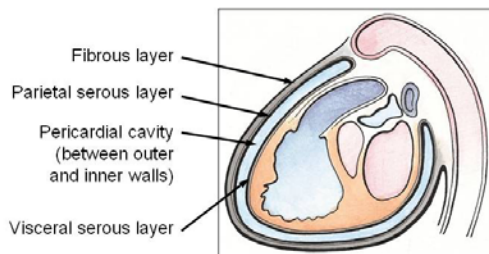
Netter 215

Slide 11.

The pericardium is a fibroserous sac containing the heart and the origins of the great vessels. It is made up of an outer wall and an inner wall separated by a pericardial cavity. The outer wall is composed of an outer connective tissue layer called fibrous pericardium fused with an inner serous layer called the parietal layer of serous pericardium. Serous tissue simply refers to a thin membrane lining a closed body cavity moistened with serous fluid. The closed body cavity in this case is the pericardial cavity separating the two fused outer wall layers with the inner wall called the visceral layer of serous pericardium. The visceral layer is the surface of the heart itself also called the epicardium. The parietal and visceral layers of serous pericardium meet and are continuous at the origins of the great vessels forming reflections.

12

Pericardium



Grant 1.60

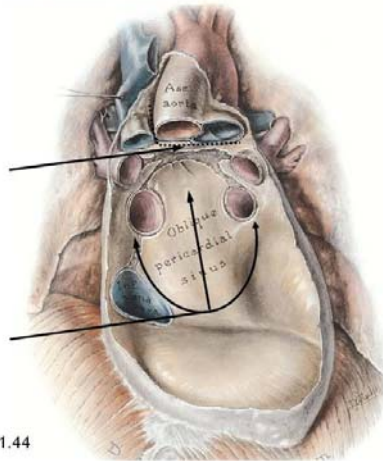
Slide 12.

On this view from Grant, visualize the layers described in the previous slide.

13

Pericardial Reflections

- Reflections in serous pericardium are revealed when heart is removed
- Arterial reflections at aorta and pulmonary trunk form the transverse sinus
- Venous reflection at SVC, IVC, and the pulmonary veins form the oblique sinus.



Grant 1.44

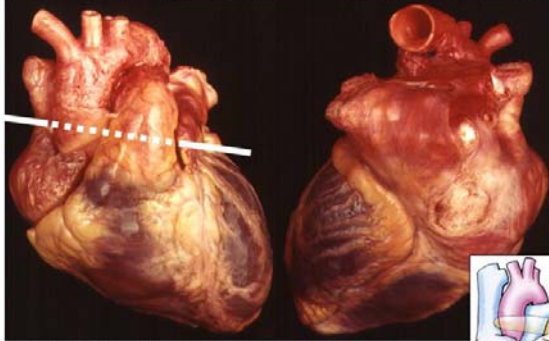
Slide 13.

The reflections of serous pericardium form a distinct space called a sinus. This can be observed in two locations around the heart. The reflections (meeting of the parietal and visceral pericardium) occurring on the aorta and pulmonary trunk form the transverse sinus. The transverse sinus is a space that can be appreciated by placing one's finger posterior to the ascending aorta and the pulmonary artery. The second space formed from serous pericardial reflections is the oblique sinus found at the origins of the great veins: SVC, IVC, and the four pulmonary veins. The oblique sinus is a pocket like space that can be appreciated by slipping one's fingers under the apex of the heart and moving upward.

14

Transverse Sinus

Anterior View/Sternocostal surface Diaphragmatic surface



Rohen & Yokochi
252

Moore & Dalley
B1.15

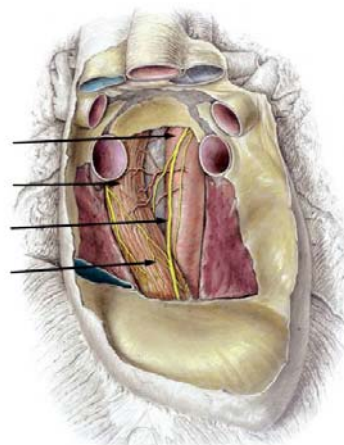
Slide 14.

When the pericardium is opened anteriorly or with the heart removed a finger can be placed in the transverse sinus to separate the aorta and pulmonary artery from the superior vena cava.

15

Posterior Relationships

- Descending aorta
- Esophagus
- Left vagus nerve
- Esophageal nerve plexus

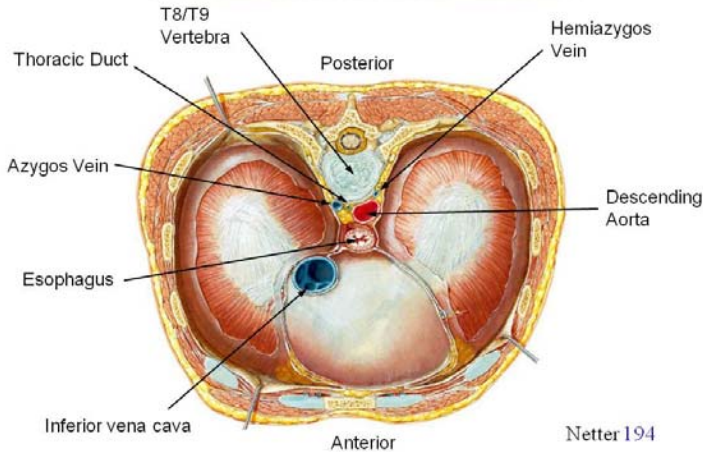


Grant 1.57A

Slide 15.

With a section of the pericardial sac removed, the relationships off the posterior surface of the heart (left atrium) can be visualized. The descending aorta, also called the thoracic aorta, has a smooth shiny reddish color and is found traveling just left of the muscular appearing esophagus. The left vagus nerve can be seen traveling with the descending aorta before it moves anterior to the esophagus to become the anterior vagal trunk. The meshwork of small nerves overlaying the esophagus is the esophageal nerve plexus. Note that this slide also allows a visual distinction between the fused outer fibrous pericardium in white with the inner parietal layer of serous pericardium in tan.

Inferior Relationships

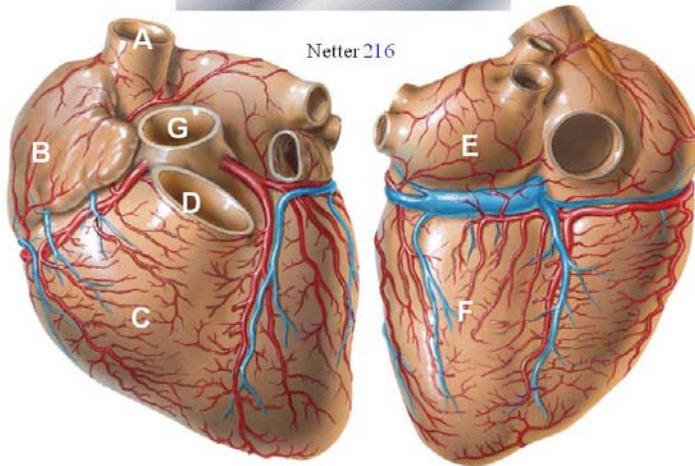


Slide 16.

Shown here are the diaphragmatic relationships of the heart at the T8/T9 vertebral level. The three leaflets of the central tendon of the diaphragm are shown. Several structures pass through the diaphragm including the inferior vena cava as it returns blood from the liver and hepatic veins. The esophagus can also be seen traveling just anterior to the descending aorta. To the right of the descending aorta is the thoracic duct allowing lymphatic drainage. Also visualized are the azygos vein and hemiazygos vein as they carry blood from the posterior wall of the thorax and abdomen before returning to the SVC and IVC.

17

Heart Chambers



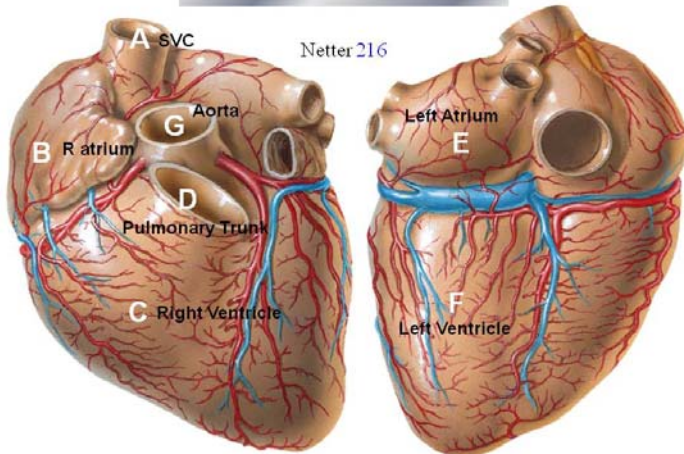
Slide 17.

Note that the labeled in the order of the blood flow:

- A) SVC
- B) right atrium
- C) right ventricle
- D) pulmonary artery
- E) left atrium
- F) left ventricle
- G) aorta

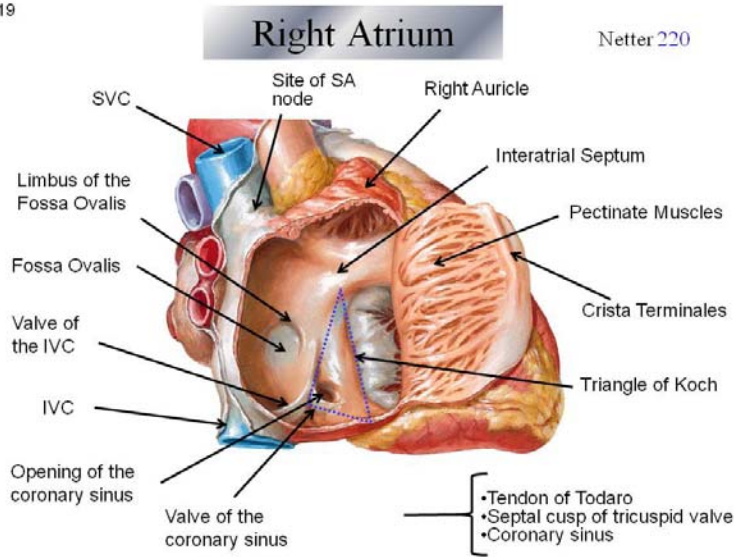
18

Heart Chambers



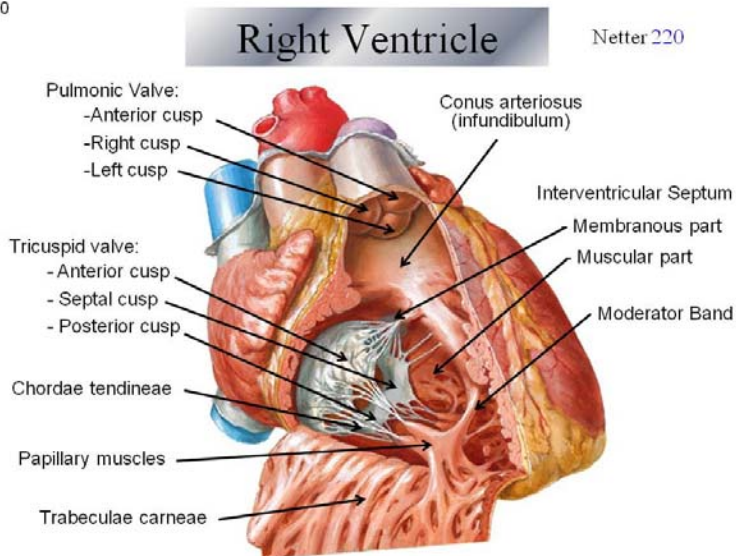
Slide 18.

Visualize the structures listed in the previous slide.



Slide 19.

The right atrium seen receives deoxygenated blood from three vessels: the superior vena cava, the inferior vena cava, and the coronary sinus. The coronary sinus returns blood from the coronary vessels supplying the heart. The free wall of the right atrium contains a conical muscular pouch called the right auricle. A smooth muscular ridge formed during development called the crista terminalis travels from the SVC to the IVC. Anterior to this ridge begin fanlike projections in the wall called pectinate muscles. Within the interatrial septum is the fossa ovalis with its limbus rim which when open during development as the foramen ovale shunted blood from the right to left atrium bypassing the non-functioning fetal lungs. On the anterior base of the SVC is the site of sinoatrial node (SA node) which begins the conduction pulse that coordinates the heart beat. That pulse travels to the atrioventricular node (AV node) contained within the Triangle of Koch whose three borders include the valve of the coronary sinus, the septal cusp of the tricuspid valve, and the Tendon of Todaro, a connective band spanning the interatrial septum.



Slide 20.

The right ventricular receives the blood from the right atrium through the tricuspid valve (anterior, posterior, and septal cusps). It then pumps it through the pulmonic valve (anterior, right, and left cusp) into the pulmonary artery and to the lungs. These valves will be discussed in further detail later in this lecture. The cusps of the tricuspid valve are attached to the papillary muscles of the wall by chordae tendineae. The papillary muscles are part of the muscular ridges and bridges along the ventricular free wall called trabeculae carneae. The moderator band is a bridge transmitting the conduction impulse from the interventricular septum to the free wall. Note that the interventricular septum contains a muscular part more anterior in the chamber and a membranous part more posterior nearer the outflow tract. The pulmonary outflow tract leading to the pulmonary trunk is called the conus arteriosus and has a smooth wall texture unlike the other wall areas of the right ventricle.

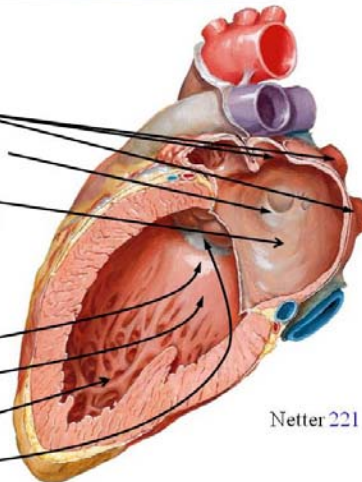
Left Atrium and Left Ventricle

Left Atrium:

- Openings for pulmonary veins (4)
- Valve of foramen ovale
- Smooth wall
 - No pectinate muscles

Left Ventricle:

- Interventricular septum
 - Membranous
 - Muscular
- Trabeculae carneae
- Aortic valve



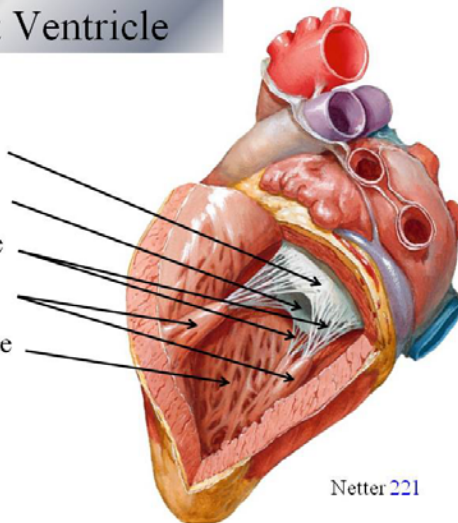
Netter 221

Slide 21.

The left atrium is supplied oxygenated blood from the lungs via the right and left superior and inferior pulmonary veins. Unlike the right atrium, the left atrium wall is smooth with the exception of the cavity of the left auricle lined with rough pectinate muscles. The left atrium does contain a thin depression in the septum called the valve of the foramen ovale opposite the fossa ovalis from the right atrium. Note that unlike the right atrium, there is no crista terminalis and no conduction nodes in the left atrium.

More Left Ventricle

- Mitral valve
 - Posterior cusp
 - Anterior cusp
- Chordae tendineae
- Papillary muscles
- Trabeculae carneae
- Aortic valve

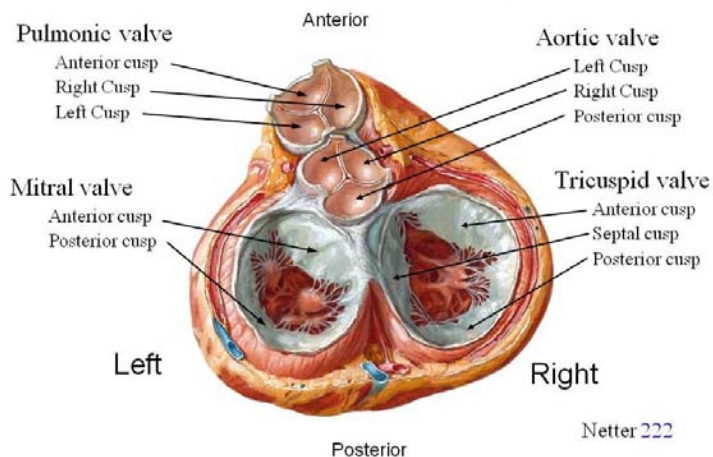


Netter 221

Slide 22.

The left ventricle receives blood from the left atrium through the mitral valve and its anterior and posterior cusps. Note that similar to the right ventricle, there are chord like projections called chordae tendineae connecting the cusps to the papillary muscles. Also similar to the right ventricle, the interventricular septum of the left ventricle contains membranous and muscular sections and the walls are lined with trabeculae carneae. Note the left ventricular wall is thicker than the right ventricular wall allowing for generation of a greater force needed to pump blood through the aortic valve into the ascending aorta and out to systemic circulation.

Valves of the Heart

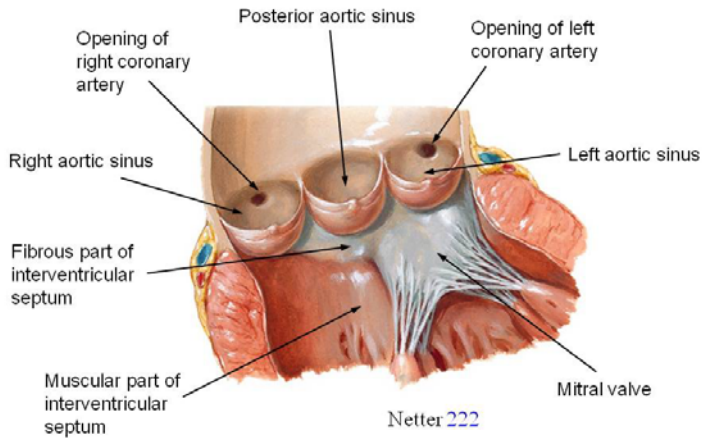


Netter 222

Slide 23.

The heart valves and their cusps are named based on their position in the heart. The tricuspid valve has an anterior, posterior and septal cusp. The blood exits the right ventricle via the pulmonic valve and its anterior, right, and left cusps. The blood from the left atrium passes through the mitral valve (anterior and posterior cusps) to the left ventricle. The blood is then pumped into the systemic circulation through the aortic valve and its posterior, right, and left cusp. Dysfunction of the heart valves causes flow irregularities leading to altered heart sounds called murmurs.

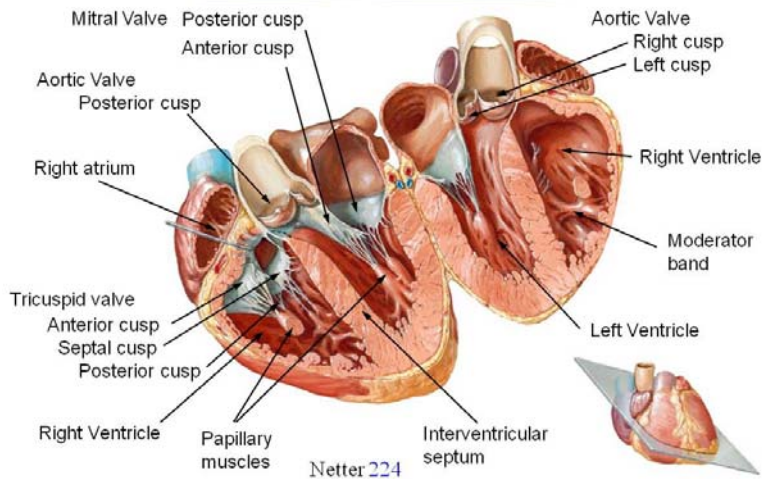
Aortic Sinus



Slide 24.

The aortic and pulmonic valves are also called semilunar valves. The cusps of these valves form pockets or spaces called sinuses. This slide is a closer view of the aortic valve and its sinuses. The right aortic sinus formed from the right cusp contains the opening of the right coronary artery. Similarly, the left aortic sinus formed from the left cusp contains the opening of the left coronary artery. These arteries will be discussed in further detail later. Note also a closer view in this slide of the muscular and membranous portions of the interventricular septum.

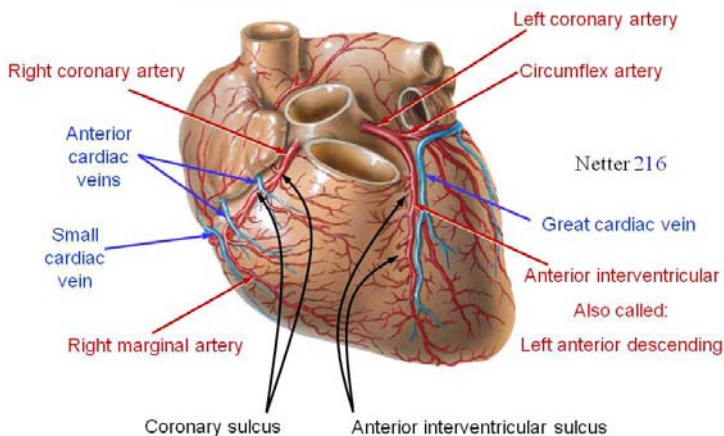
Bisected View



Slide 25.

This slide is a bisected view of the heart split down a line just posterior to the pulmonary trunk and the apex. The features described in this slide are as previously described. Note the variation in wall width between the right and left ventricles. The thickened left ventricular wall is needed by the heart to generate greater force needed to supply systemic circulation.

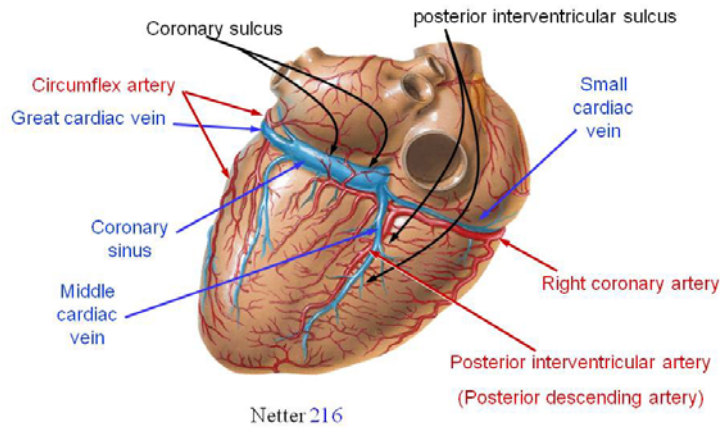
Coronary Vessels



Slide 26.

This view displays the coronary vasculature. The right coronary artery exits the right base of the ascending aorta and travels anterior to posterior within the coronary sulcus (groove separating the atria from the ventricles). The right marginal artery is then given off traveling toward the apex with the small cardiac vein. The left coronary artery exits the left base of the ascending aorta and travels between the pulmonary trunk and left auricle into the coronary sulcus and branches into the anterior interventricular artery and the circumflex artery. The anterior interventricular artery (also called left anterior descending artery) travels with the great cardiac vein in the anterior interventricular sulcus. The circumflex artery continues traveling posterior in the coronary sulcus with the great cardiac vein.

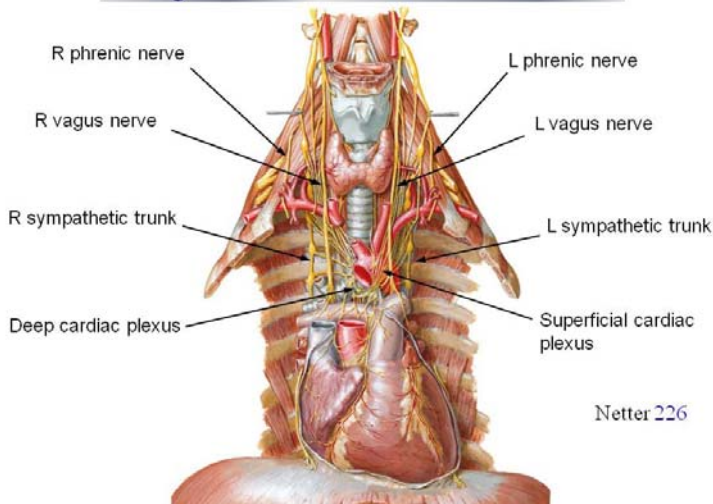
Coronary Vessels



Slide 27.

This slide displays the diaphragmatic coronary vessels. The right coronary artery traveling posterior within the coronary sulcus gives rise to the posterior interventricular artery (also called posterior descending artery) which travels with the middle cardiac vein in the posterior interventricular sulcus. The network of veins around the heart eventually drain into the coronary sinus which returns the deoxygenated blood directly to the right atrium thus completing the coronary flow cycle. Note that there are variations in branching of the coronary vessels as well as other minor branches that are not described here.

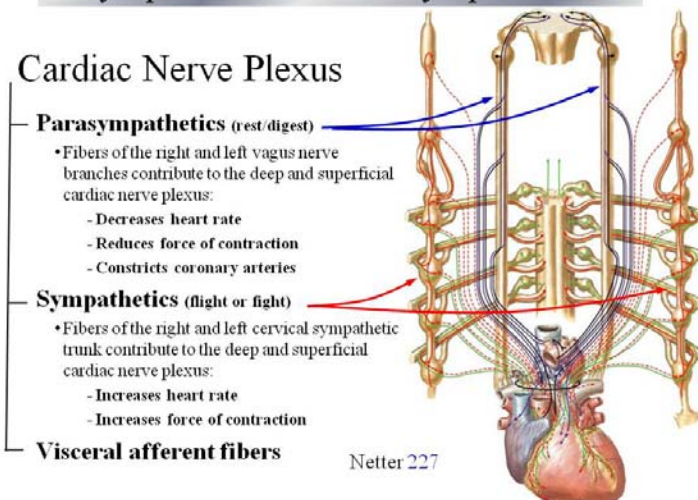
Major Nerves of the Heart



Slide 28.

The innervation to the pericardium is by fibers of the right and left phrenic nerves as they pass through the fibrous pericardium on their way to the diaphragm. The heart itself is innervated by the superficial and deep cardiac plexus which are composed of fibers traveling from the right and left vagus nerves and the right and left sympathetic trunks. The deep cardiac plexus can be found between the tracheal bifurcation and the aortic arch. The superficial cardiac plexus is located just anterior and inferior to the aortic arch. The cardiac plexus network of nerve fibers supplies the heart with sympathetic, parasympathetic, and visceral afferent nerve stimulation.

Sympathetics vs. Parasympathetics



Slide 29.

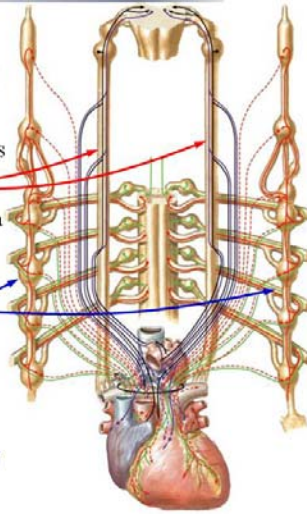
The ANS through parasympathetic and sympathetic nerve fibers controls the conduction system, coronary vessels, and cardiac musculature. The parasympathetic fibers are supplied by the right and left vagus nerves. Their stimulation causes a decrease in heart rate, reduction of the force of contraction, and constriction of the coronary arteries thus reducing coronary blood flow as well as total cardiac output. The sympathetic fibers are supplied by the right and left sympathetic trunks. Their stimulation causes an increase in heart rate and force of contraction thus increasing blood flow to the systemic and coronary circulation.

Visceral Afferent Neurons

Visceral afferent nerve fibers

- Sensation fibers within the vagal and sympathetic trunks
- Contribute to the cardiac nerve plexus
- Within vagal branches:
 - Allow cardiac reflex through sensation of blood pressure changes and blood chemistry changes
- Within sympathetic trunks:
 - Conduct pain sensation from heart
 - Detected on cellular level
 - Responsible for referred pain

Netter 227



Slide 30.

In addition to the sympathetic and parasympathetic innervation, the cardiac plexus also contains visceral afferent nerve fibers (also known as sensory neurons or receptor neurons). These fibers allow a unidirectional flow of sensory information from the heart back to the central nervous system (CNS) by way of the vagus nerves or the sympathetic trunks. The visceral afferent fibers traveling within the vagal branches allow cardiac reflex by sensation in changes in blood pressure and blood electrolyte concentrations. The visceral afferent fibers traveling back through the sympathetic trunks are responsible for pain sensation on a cellular level. These fibers arrive in the CNS through the T₁-T₄ nerve roots along with somatic sensory nerves from the left arm. The brain interprets this as pain in the left arm during a heart attack (called referred pain).

Conduction System

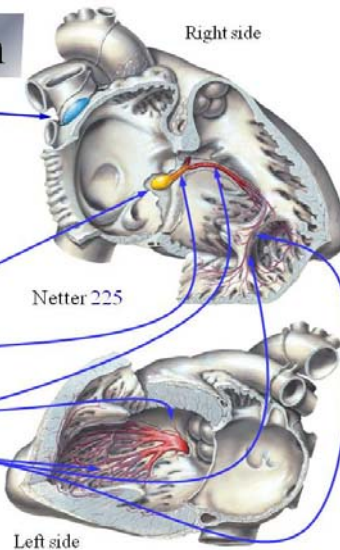
Sinatrial (SA) node

- Located on the anterior aspect of the SVC at the end of the sulcus terminalis
- "Pacemaker" that determines heart rate
- Sends a conduction wave to atria
- Blood supplied from right coronary artery

Atrioventricular (AV) node

- In triangle of Koch
- AV bundle of His: conducts to each ventricle on either side of the IVS through the right and left bundle branches
- Conduction continued along specialized cardiac muscle cells (Purkinje Fibers)
- Conduction along the moderator band to the external wall
- Blood supplied from right coronary artery

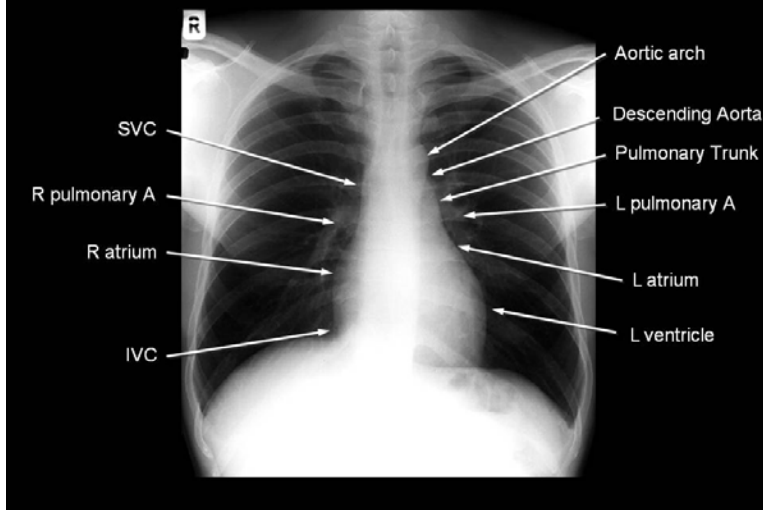
Netter 225



Slide 31.

This slide displays the cardiac conduction scheme. Once the heart is supplied by nervous innervation, the conduction system is what converts those nervous impulses into separate and unique electrical waves along the cardiac walls. This triggers contraction of the atrial and ventricular myocardium timed sequentially to allow filling and emptying of the cardiac chambers (the heart beat). The conduction begins with the firing of the sinatrial node (the pacemaker) located on the anterior aspect of the SVC. The excitation impulse is transmitted through the atria stimulating the firing of the atrioventricular node located in the Triangle of Koch previously described. The AV nodal impulse is carried through the AV bundle of His in the interatrial septum and splits into the right and left bundle branches. The conduction is carried along the interventricular septum and into specialized cardiac muscle cells called purkinje fibers and to the free walls along the specialized papillary muscles called moderator bands.

Radiographic features



Slide 32

This slide is a summary of some of the radiographic features of a normal appearing cardiac silhouette. The right margin starts superiorly with the SVC then becomes the right atrium followed by the IVC. Part of the right pulmonary artery can be visualized just lateral to the right heart border. Most of the left border of the cardiac silhouette is composed of the left ventricle and left atrium. The left superior border contains part of the aortic arch, descending aorta, and pulmonary trunk.

Slide 33.

The End

Anterior abdominal wall, inguinal region, scrotum, & testis

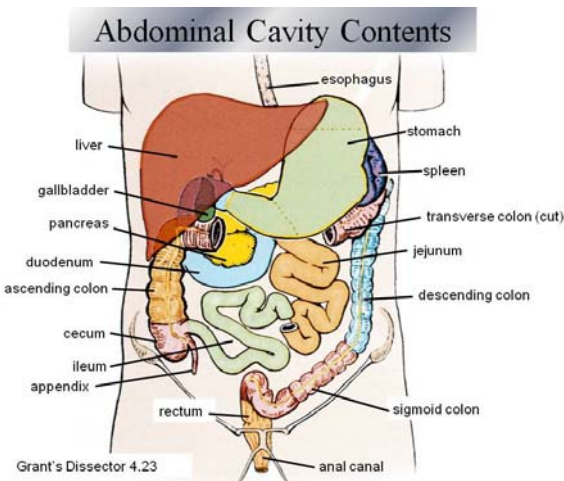
By Thierry Bacro

Center for Anatomical Studies and Education
Department of Regenerative Medicine and Cell Biology
College of Medicine
Medical University of South Carolina

Slide 1.

In this lecture, the muscular, vascular and nervous components of the anterior abdominal wall will be discussed. The abdominal wall contributes to the structure of a major feature of the inguinal region, the inguinal canal. So, the development of the inguinal canal, as well as its structure and contents will be introduced. This lecture will also feature the anatomy and some function of the scrotum and testis.

2



Slide 2.

These contents of the abdominal cavity are protected, in part, by the anterior abdominal wall.

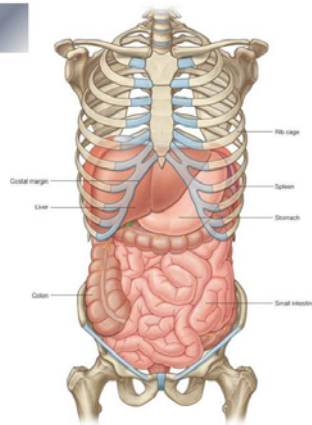
3

Abdominal Cavity

The abdominal viscera are protected and supported by:

- The thoracic cage
- The pelvic girdle
- The abdominal wall muscles

Drake 4.2

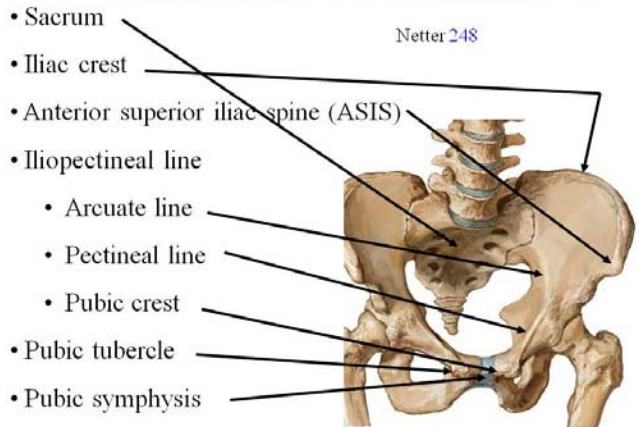


Slide 3.

The abdominal cavity is located between the thorax and the pelvis. The upper limit of the abdominal cavity is the diaphragm. The abdominal viscera nearest the diaphragm are protected by the thoracic cage. The pelvic girdle cradles and protects the abdominal viscera caudally. The viscera in the middle of the abdomen are protected and supported by the abdominal wall (muscular).

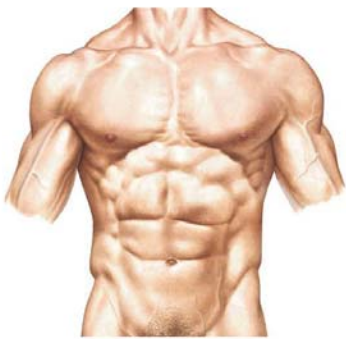4

Skeleton of Inguinal Region



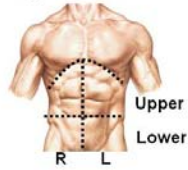
5

Surface Landmarks



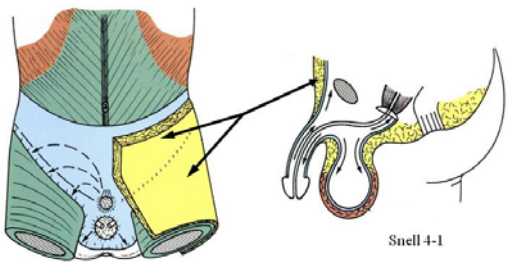
Netter 247

- Linea alba
- Linea semilunaris
- Tendinous intersections
- Umbilicus (vertebral L3/L4)
- Inguinal fold



6

Superficial Fascia



Snell 4-1

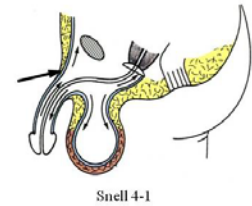
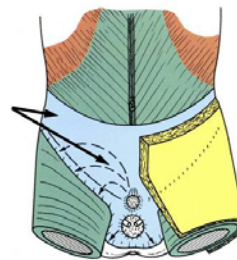
Slide 4.

The pelvis is made up of two fused pelvic bones. These bones are connected to one another by the sacrum posteriorly and the pubic symphysis anteriorly. Please note the iliopectineal line which is made up of the arcuate and pectineal lines, as well as the pubic crest. The iliopectineal line, sacrum, and pubic symphysis border the pelvic inlet. Some important features of the skeleton in relation to the inguinal region are the anterior superior iliac spine (ASIS), the pectineal line (pecten pubis), the pubic crest, and the pubic tubercle.

7

Deep Fascia

- Membranous layer
- Thin connective tissue covering on muscles



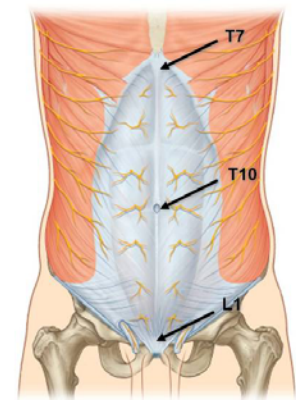
Slide 5.

Linea alba extends from the xiphoid process to the pubic symphysis. It is a midline groove over the site of fusion of the aponeuroses of anterior abdominal wall muscles. Linea semilunaris is the depression at the lateral edge of each rectus abdominis muscle. The 3-4 transverse grooves (between xiphoid process and umbilicus) represent the underlying tendinous intersections of the rectus abdominis muscle. The umbilicus is the scar of the attachment of the umbilical cord at vertebral level L₃-L₄. The inguinal fold (skin) overlies the inguinal ligament. It separates anterior abdominal wall and thigh. (Clinicians divide the anterior abdominal wall into quadrants for ease of reference.)

8

Cutaneous Nerves

- The lateral cutaneous nerves: T7 - T12
- The anterior cutaneous nerves: T7 – T12
- The iliohypogastric and ilioinguinal nerves: L1



Drake (Gray) 4.36

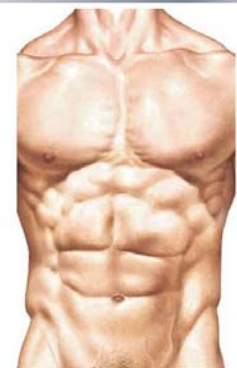Slide 6.

The anterior abdominal wall has a fatty layer of superficial fascia which is continuous with the fatty superficial fascia of the rest of the body and contains superficial vessels and nerves.

9

Muscles of Anterior Abdominal Wall

- Flat:
 - External oblique
 - Internal oblique
 - Transversus abdominis
- Vertical:
 - Rectus abdominis
 - Pyramidalis.



Netter 247

Slide 7.

The deep fascia of the anterior abdominal wall is a thin connective tissue layer which covers the muscles that form the wall.

Slide 8.

Intercostal nerves (T₇-T₁₁) leave the intercostal spaces to give rise to lateral and anterior cutaneous branches that supply the abdominal wall in a segmental pattern (see dermatomes). Subcostal nerve (T₁₂) is inferior to the 12th rib. Cutaneous innervation is segmental. Key dermatomes to remember are T₇ (at xiphoid process), T₁₀ (at umbilicus), and L₁ (at inguinal ligament and pubic symphysis).

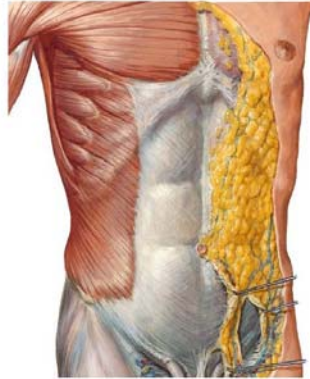
Slide 9.

The anterior abdominal wall has five muscles. These five muscles can be described as being either flat or vertical.

10

External Oblique Muscle

- Origin:
 - Lower 8 ribs
- Insertion:
 - Xiphoid process
 - Linea alba (rectus sheath)
 - Anterior ½ iliac crest and ASIS
 - Pubic crest
 - Pubic tubercle.



Netter 249

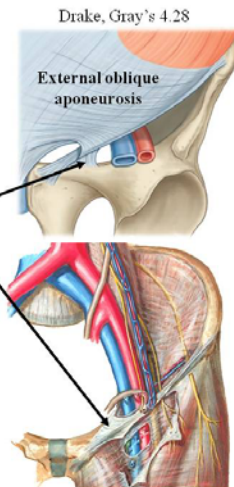
Slide 10.

The most superficial muscle of the anterior abdominal wall is the external oblique muscle. The external oblique arises from the outer surfaces of the lower 8 ribs, where it interdigitates with the serratus anterior and latissimus dorsi muscles. Most of the fibers end in a broad aponeurosis, inserting to the xiphoid process, linea alba, and pubic crest. The lower fibers insert into the anterior ½ of the iliac crest, the ASIS, as well as the pubic crest & tubercle.

11

Inguinal Ligament

- Inferolateral border of external oblique aponeurosis
- Lacunar ligament:
 - connects inguinal and pectineal ligaments
- Pectineal ligament:
 - on pectineal line of superior pubic ramus



Netter 260

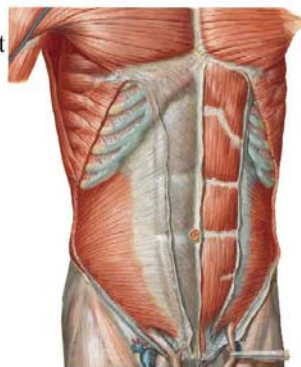Slide 11.

The inguinal ligament is formed by the inferolateral edge of the external oblique aponeurosis, which runs from the anterior superior iliac spine to the pubic symphysis. The aponeurosis is rolled onto itself creating a thickened edge. At the medial end of the inguinal ligament is a crescent-shaped extension of the external oblique aponeurosis termed the lacunar ligament. Additional fibers run along the pectineal line to form the pectineal ligament.

12

Internal Oblique Muscle

- Origin:
 - Lumbar fascia
 - Anterior 2/3 iliac crest
 - Lateral 2/3 inguinal ligament
- Insertion:
 - Lower 3 ribs
 - Xiphoid process
 - Linea alba (rectus sheath)
 - Pubic crest (conjunct tendon)



Netter 250

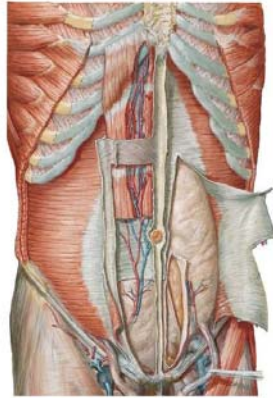
Slide 12.

The internal oblique muscle is deep to the external oblique muscle. The internal oblique muscle arises from the lumbar fascia, the anterior 2/3 of the iliac crest, and the lateral 2/3 of the inguinal ligament. The fibers of the internal oblique muscle fan out and insert into the lower 3 ribs and costal cartilages and by an aponeurosis to the xiphoid process and linea alba. The lowest fibers of this muscle insert on the pubic crest as part of the conjoint tendon deep to the plane of the superficial ring (a feature of the inguinal ligament discussed later). Note that this is one of two muscles contributing to the formation of the conjoint tendon.

13

Transversus Abdominis Muscle

- Origin:
 - Lumbar fascia
 - Lower 6 ribs
 - Anterior 2/3 of iliac crest
 - Lateral 1/3 of inguinal ligament
- Insertion:
 - Xiphoid process
 - Linea alba (rectus sheath)
 - Pubic crest (conjoint tendon)



Netter 251

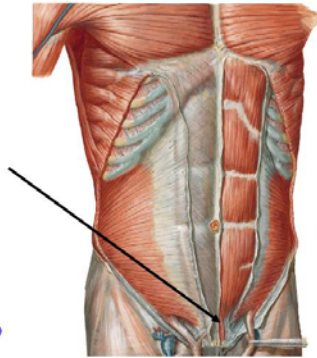
Slide 13.

The transversus abdominis muscle is a thin muscle deep to the internal oblique. The fibers of this muscle originate from the deep surface of the lower six costal cartilages, the lumbar fascia, anterior 2/3 of the iliac crest, and lateral 1/3 of the inguinal ligament. These fibers insert on the xiphoid process, and by aponeurosis into linea alba. The lowest fibers insert (as the internal oblique) onto the pubic crest as part of the conjoint tendon (a.k.a. falx inguinalis or inguinal falx).

14

Pyramidalis Muscle

- Origin:
 - Pubic crest
- Insertion:
 - Linea alba



Netter 250

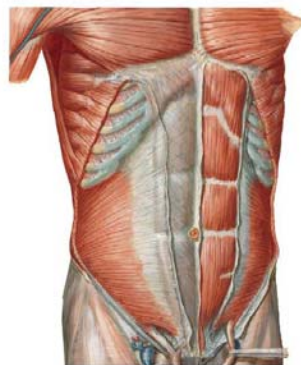
Slide 14.

The pyramidalis may be found on the inferior surface of the rectus abdominis muscle within the rectus sheath. When present, the pyramidalis muscle originates from the pubic crest and inserts into linea alba.

15

Rectus Abdominis Muscle

- Origin:
 - Front of pubic symphysis and crest
- Insertion:
 - 5th, 6th, and 7th costal cartilages
 - Xiphoid process
- Surrounded by the aponeurotic sheath



Netter 250

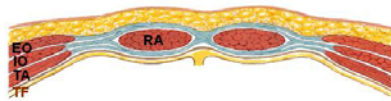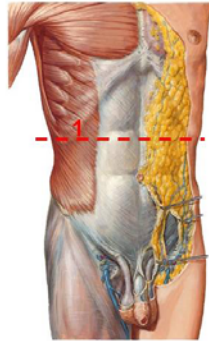
Slide 15.

The rectus abdominis muscle is a long, strap-like muscle deep to the rectus sheath. This muscle has 3 or 4 tendinous intersections found between the xiphoid process and the umbilicus. This muscle originates from the front of the pubic symphysis and pubic crest. The muscle inserts into the 5th, 6th, and 7th costal cartilages and the xiphoid process.

The Rectus Sheath

Superior to the arcuate line:

- Anterior layer: external oblique, ½ of internal oblique
- Posterior layer: ½ of internal oblique, transversus abdominis

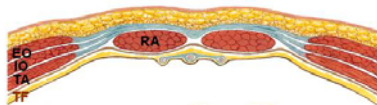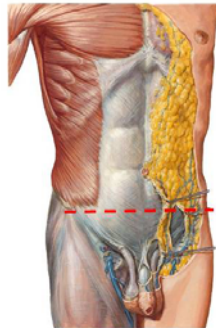


Netter 249 and 252

The Rectus Sheath

Inferior to the arcuate line:

- All 3 muscles contribute only to anterior layer of sheath
- Posterior aspect of rectus abdominis muscle contacts transversalis fascia

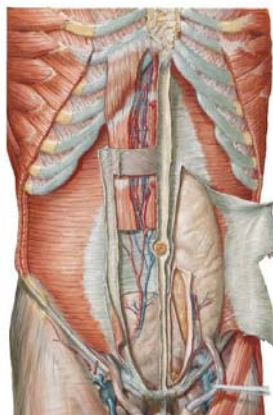


Netter 249 and 252

Posterior Rectus Sheath

With the rectus abdominis partially removed, observe:

- The inferior extent of posterior aponeurotic layer of sheath
- The arcuate line
- The transversalis fascia



Netter 251

Slide 16.

The rectus sheath is formed by the aponeuroses of the external oblique, internal oblique, and transversus abdominis muscles. The organization of the rectus sheath changes at different levels in the anterior abdominal wall. We can make a general rule about the relative contributions of these muscles to the rectus sheath by referring to the arcuate line (see slide 18) as a marker for the point at which a change occurs. Superior to the arcuate line, the anterior portion of the rectus sheath is formed by the aponeuroses of the external and ½ of internal oblique muscle. The posterior portion of the rectus sheath at this level is formed by ½ of the internal oblique and the transversus abdominis muscle.

Slide 17.

Inferior to the arcuate line, the aponeuroses of all three muscles (external oblique, internal oblique, and transversus abdominis) form the anterior portion of the rectus sheath. At this level, the posterior sheath is absent and the rectus abdominis muscle is separated from the abdominal peritoneum only by a layer of fascia that lines the abdominal cavity (transversalis fascia).

Slide 18.

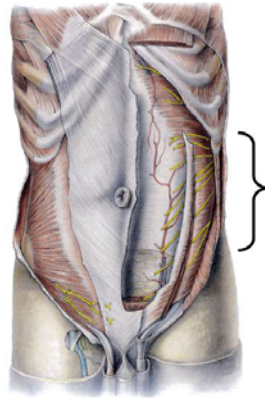
The right rectus abdominis muscle has been removed in this image to demonstrate the extent of the posterior rectus sheath. The posterior layer ends as the arcuate line. It is inferior to this point that only the transversalis fascia separates the rectus abdominis muscle from the peritoneum of the abdominal cavity.

Other Contents

- Arteries and veins:
 - superior epigastric
 - inferior epigastric
 - anastomotic connections

- Nerves:
 - T7-T11 intercostal
 - Subcostal

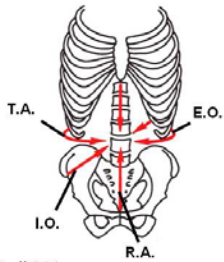
Grants 2.5



Slide 19.

The rectus sheath contains the superior epigastric artery (vein), inferior epigastric artery, lower intercostal nerves (T₇-T₁₁), and subcostal nerve (T₁₂). The superior epigastric artery is a terminal branch of the internal thoracic artery that enters the rectus sheath between the sternal and costal portions of the diaphragm and descends posteriorly to the rectus muscle along with the superior epigastric vein. The inferior epigastric artery is a branch of the external iliac artery that runs through the transversalis fascia to reach the rectus sheath at the level of the arcuate line. The superior and inferior epigastric arteries anastomose in the rectus sheath.

Innervation and Actions of Muscles



Snell 4-14

| Muscle | Nerves | Action |
|-----------------------|----------|--------------------------------|
| External oblique | T7 - L1 | |
| Internal oblique | T7 - L1 | Laterally flex, rotate trunk |
| Transversus abdominis | T7 - L1 | |
| Rectus abdominis | T7 - T12 | Flex trunk Stabilize pelvis |

- Relax during inspiration
- Contract to force expiration
- Contract to increase intra-abdominal pressure

Slide 20.

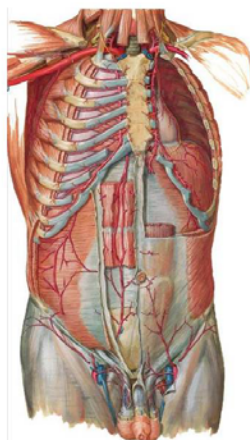The external oblique, internal oblique, and transversus abdominis muscles are supplied by intercostal nerves 7-11, the subcostal nerve (T₁₂), and the first lumbar nerve (L₁). The rectus abdominis muscle is supplied by intercostal nerves 7-11 and the subcostal nerve. The oblique muscles laterally flex and rotate the trunk. The rectus abdominis flexes the trunk and stabilizes the pelvis. Relaxation of the abdominal muscles occurs during inspiration to allow downward movement of viscera. Abdominal muscles are contracted to increase intra-abdominal pressure during forced expiration, micturition, defecation, and parturition.

Superficial Arteries

- Anterior perforating arteries
 - Superior epigastric artery
 - Inferior epigastric artery

- Lateral cutaneous arteries
 - Lower intercostal and subcostal arteries
 - Lumbar arteries

Netter 255



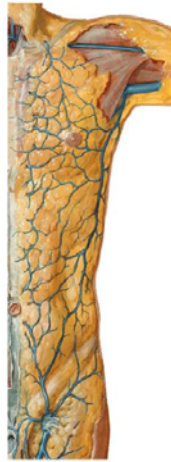Slide 21.

The superficial arteries are running within superficial fascia (Camper's fascia). The superior and inferior epigastric arteries run vertically near the midline. Anastomoses exist between the lower intercostal, subcostal, and lumbar arteries.

Superficial Veins

- The superior and inferior epigastric veins
- The thoracoepigastric vein
- The superficial inguinal veins
- The paraumbilical veins

Netter 256



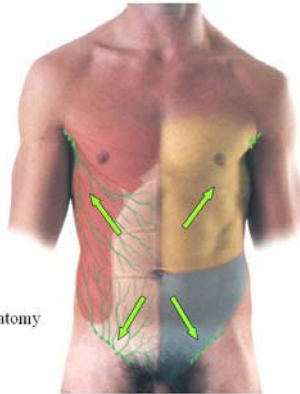
Slide 22.

Superficial veins are found within superficial fascia (Camper's fascia). Many anastomoses exist in this superficial venous network. The superior and inferior epigastric veins run alongside their arterial counterparts. Interestingly, the paraumbilical veins drain to the portal vein via the falciform ligament.

Superficial Lymphatic Drainage

- Above the umbilicus:
 - The anterior axillary nodes
- Below the umbilicus:
 - The superficial inguinal nodes.

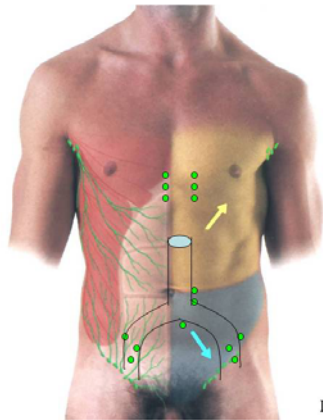
Drake, Gray's Anatomy



Slide 23.

Superficially, the anterior abdominal wall superior to the umbilicus drains to anterior axillary nodes. The region inferior to the umbilicus drains to superficial inguinal nodes.

Deep Lymphatic Drainage



Drake, Gray's Anatomy

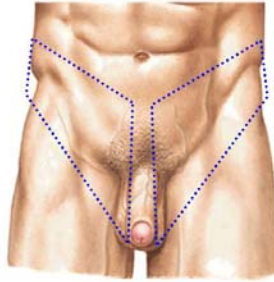
- Follow the deep arteries to:
 - The parasternal nodes (internal thoracic artery)
 - The lumbar nodes (abdominal aorta)
 - The external iliac nodes (external iliac artery).

Slide 24.

The deep lymphatic drainage of the anterior abdominal wall follows the deep arteries.

Inguinal Region

- Between the anterior superior iliac spine and the pubic tubercle
- Clinically important as sites of herniation
- The scrotum and testes are related to anterior the abdominal wall and the inguinal region.



Netter 247

Slide 25.

The inguinal region (groin) is the area where the anterior abdominal wall and thighs meet. More specifically, this region is located between the ASIS and pubic tubercle.

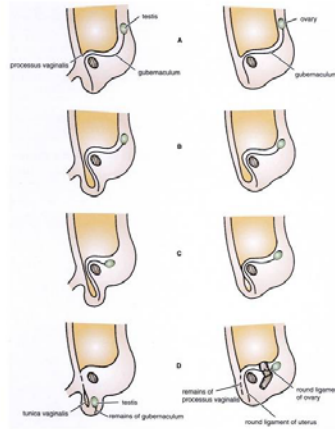
Slide 26.

During development, the initial position of the testes/ovaries is high in the posterior abdominal wall. An outpouching of the peritoneum (processus vaginalis) forms. The processus vaginalis continues to push outward through several layers: transversalis fascia, internal oblique musculature, and the aponeurosis of the external oblique muscle. As the processus vaginalis continues to push through the abdominal wall, the inguinal canal is formed. The layer of transversalis fascia becomes the deepest layer, while the aponeurosis of the external oblique muscle remains the most superficial layer. The descent of the testes/ovaries is guided by the gubernaculum. The gubernaculum (directly posterior to the processus vaginalis) pulls the testes through the inguinal canal and into the scrotum, while ovaries remain in the pelvic cavity. As the testes move through the inguinal canal, their complement of vessels, nerves, and ducts acquire the same complement of layers as the inguinal canal. The resulting structure is the spermatic cord. In females, the remnant of the gubernaculum (round ligament of the uterus) remains in the inguinal canal. Descent of the gonads is complete upon the obliteration of the processus vaginalis. If it remains patent, a weakening of the abdominal wall can occur, possibly resulting in a hernia.

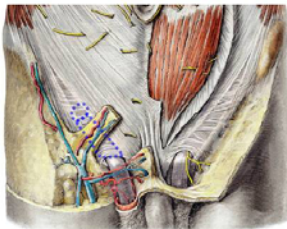
Descent of Gonads (testes and ovaries)

- Retroperitoneal
- Descent posterior to the processus vaginalis
- The gubernaculum is a guide

Snell (Systems) 19-16



Inguinal Canal



Grant 2.4

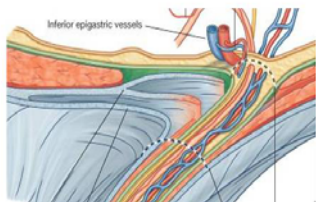
- Parallel and superior inguinal ligament
- Runs from the superficial to the deep inguinal ring

Slide 27.

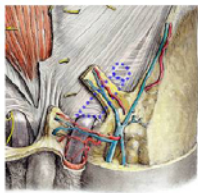
The inguinal canal is situated parallel and superiorly to the inguinal ligament. The canal is a tube formed during gonad development which spans the region between the deep and superficial inguinal rings.

Deep Ring of Inguinal Canal

- Between the ASIS and the pubic symphysis
- Lateral to the inferior epigastric vessels
- Start of as an evagination of transversalis fascia, forms the internal spermatic fascia (male)



Drake, Gray's 4-47



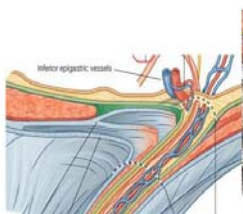
Grant 2-4

Slide 28.

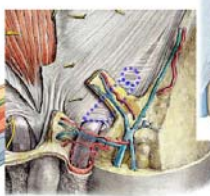
The deep ring of the inguinal canal is found half-way between ASIS and pubic symphysis. It is lateral to the inferior epigastric vessels. As previously described, this ring of the inguinal canal results from an evagination of the transversalis fascia, a contributor to the formation of the internal spermatic fascia in males.

Superficial Ring of Inguinal Canal

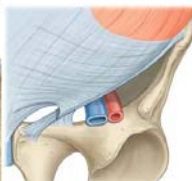- Found at the end of the inguinal canal
- Opening in external oblique aponeurosis
- Note: the lateral and medial crura, and the Intercrural fibers.



Drake, Gray's 4-47



Grant 2-4



Drake, Gray's 4-28

Slide 29.

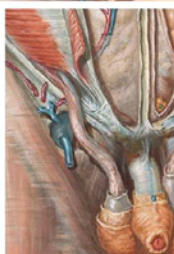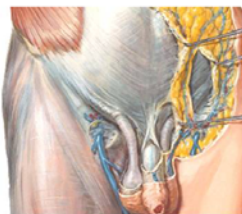The superficial ring of the inguinal canal is found at the lower end of the canal. It is an opening in the external oblique aponeurosis. The superficial ring is arch-like in shape. The lateral and medial crura (attaching to the pubic symphysis and pelvic tubercle, respectively) form the sides of the arch. These tendinous crura are joined at the apex of the arch by the intercrural fibers. The base of the arch is the pubic crest.

Borders of Inguinal Canal

Netter 249

- Anterior wall:
 - The external oblique aponeurosis
- Roof:
 - The internal oblique
 - The transversus abdominis.

Netter 251



Slide 30.

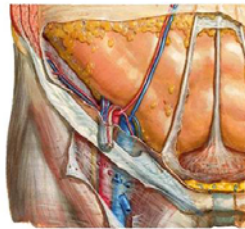
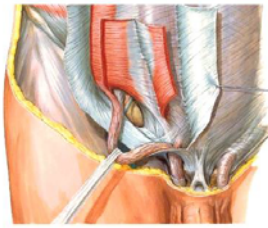
The inguinal canal has borders. The anterior wall of the inguinal canal is the external oblique aponeurosis. The roof is made up of the internal oblique and transversus abdominis muscles.

31

Borders of Inguinal Canal

- Posterior wall:
 - The transversalis fascia
 - Medially reinforced by the conjoint tendon
- Floor:
 - The inguinal ligament
 - The lacunar ligament.

Netter 259



Netter 262

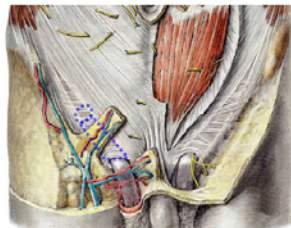
Slide 31.

The posterior wall of the inguinal canal is made up of transversalis fascia. Medially, the posterior wall is reinforced by the conjoint tendon. The floor of the canal is formed by the inguinal and lacunar ligaments.

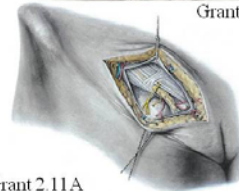
32

Contents of Inguinal Canal

- Observe the:
- Ilioinguinal nerve
 - In males: the spermatic cord
 - In females: the round ligament of uterus.



Grant 2.4



Grant 2.11A

Slide 32.

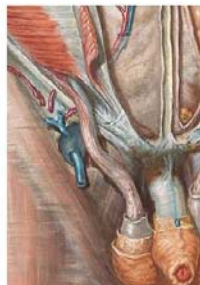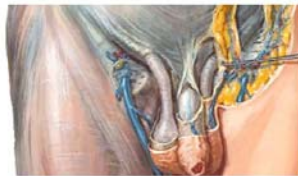The inguinal canal contains the ilioinguinal nerve. In males it also contains the spermatic cord, whereas in females it contains the round ligament of the uterus.

33

Spermatic Cord

- Begins at the deep inguinal ring
- Pass through the inguinal canal
- Exits superficially at the inguinal ring
- Ends in the scrotum.

Netter 249



Netter 251

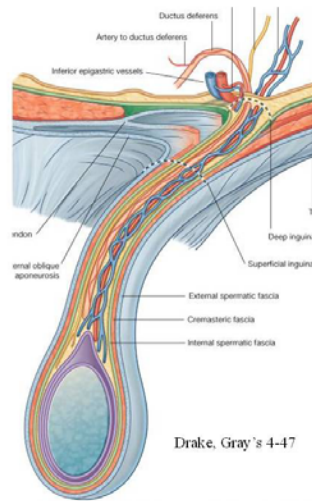
Slide 33.

The spermatic cord begins at the deep inguinal ring, runs through the inguinal canal, exits the inguinal canal via the superficial inguinal ring, and ends in the scrotum.

34

Fascia Coverings

- The internal spermatic fascia is formed by the transversalis fascia at the deep inguinal ring
- The cremasteric fascia is formed the fascia of internal oblique (cremaster muscle)
Note the genital branch of genitofemoral N (L_{1,2})
- The external spermatic fascia is formed by the external oblique aponeurosis and fascia.



Drake, Gray's 4-47

Slide 34.

The three fascia coverings of the spermatic cord are derived from layers of the anterior abdominal wall. These layers were acquired during development with the descent of the processus vaginalis (now the tunica vaginalis within the scrotum) through the layers of the abdominal wall. The internal spermatic fascia is derived from the transversalis fascia. The cremasteric fascia and muscle were derived from the internal oblique muscle. The cremasteric muscle is innervated by the genital branch of the genitofemoral nerve (L_{1,2}). The external spermatic fascia was derived from the external oblique aponeurosis and fascia.

35

Layers of Spermatic Cord from Layers of Abdominal Wall

| Layers of Abdominal Wall | Fascia of Spermatic Cord |
|--------------------------|-----------------------------|
| External oblique | External spermatic fascia |
| Internal oblique | Cremaster fascia and muscle |
| Transversus abdominus | |
| Transversalis fascia | Internal spermatic fascia |
| Peritoneum | |

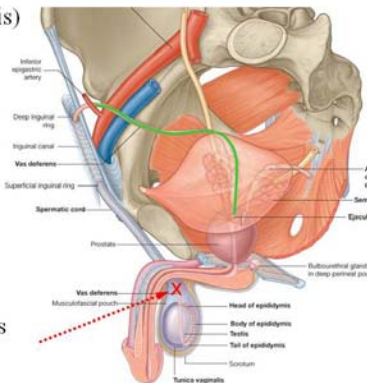
Slide 35.

This table summarizes the relationship between layers of the abdominal wall and the fascia of the spermatic cord. Note that not all of the layers of the abdominal wall contribute to the spermatic cord, i.e. transversus abdominis muscle and peritoneum.

36

Vas Deferens (Ductus Deferens)

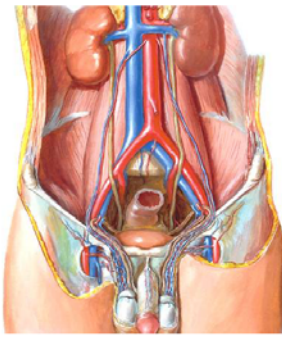
- Testis (tail of epididymis)
- Spermatic cord
- Superficial ring
- Inguinal canal
- Deep ring
- Through pelvis (retroperitoneal)
- Vasectomy:
 - male sterilization
 - ligation and cut of vas deferens.



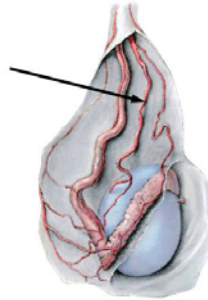
Slide 36.

The vas deferens is the duct responsible for transporting sperm from the epididymis to the ejaculatory duct. This structure is easily palpated in the lab. The duct begins at the tail of the epididymis and passes up the spermatic cord through the inguinal canal, through the deep ring and lateral to the inferior epigastric vessels. The vas descends into the pelvic cavity to empty into the prostatic urethra. A vasectomy is the ligation and cutting of the vas deferens within the spermatic cord inferior to the superficial inguinal ring (within the scrotum).

Testicular Artery



Netter 401



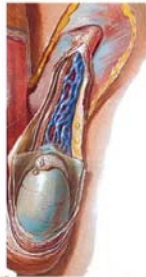Grant 2.17A

Slide 37.

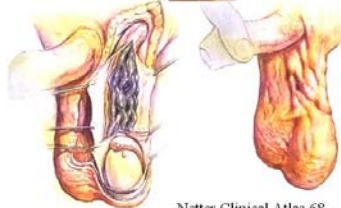
The testicular artery supplies the testis and epididymis. It originates from the anterior surface of the abdominal aorta, just inferior to the origin of the renal arteries. As the testis descends retroperitoneally during development, it carries blood supply with it to the scrotum.

Pampiniform Plexus

- Plexus of up to 12 veins from testis and epididymis in spermatic cord
- Countercurrent exchange
- Coalesces at inguinal canal to form a single testicular vein
- Varicocele:
 - enlargement of plexus
 - palpable in scrotum
 - “bag of worms”



Netter 387



Netter Clinical Atlas 68

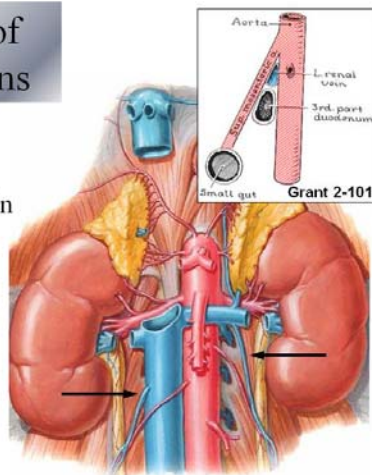
Slide 38.

The pampiniform plexus is a venous network responsible for draining blood from the testis and epididymis. The veins act to cool the structures they envelop, such as the vas deferens & testicular artery. These veins allow the contents of the spermatic cord to maintain the cooler temperatures needed for spermatogenesis. The plexus converges at the inguinal canal (one on each side of body) to form a right or left testicular vein. If a testicular vein is obstructed, the plexus becomes enlarged. This condition is called “varicocele,” and it is palpable in the scrotum.

Termination of Testicular Veins

- On right: to the IVC
- On left: to left renal vein
- Left renal vein crossed by superior mesenteric artery (SMA)
- Left renal vein can be clamped by SMA.

Netter 332



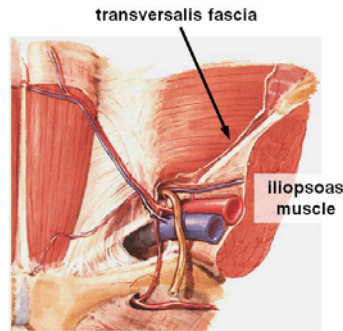
Slide 39.

The right testicular vein drains directly into the inferior vena cava (IVC), whereas the left testicular vein drains into the left renal vein. (A similar pattern of drainage is in place for ovaries in females.) The superior mesenteric artery (SMA) descends over and anterior to the left renal vein between the IVC and the termination of the left testicular vein. The left renal vein can be compressed between the SMA, anteriorly, and the abdominal aorta, posteriorly. This could cause higher pressure in the left renal vein and restrict flow from the left testicular vein, resulting in varicoceles on the left side. (>90% of varicoceles occur on the left side)

40

Spermatic Cord: Relationships

- Begins at deep inguinal ring
- Vas deferens and testicular vessels converge
- Lateral to inferior epigastric vessels on anterior wall.



Netter 259

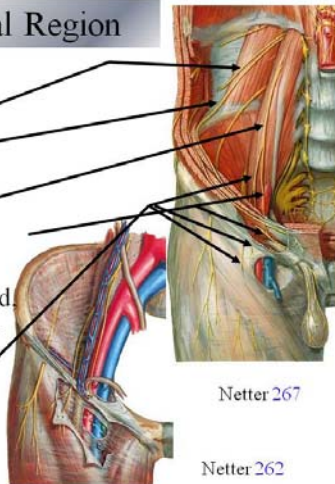
Slide 40.

The spermatic cord contains arteries, veins, ducts, nerves, and lymphatic vessels. The cord begins at the deep inguinal ring. When viewing structures entering the posterior side of the deep inguinal ring, one can see that the vas deferens and testicular vessels are passing through the spermatic cord. This occurs just laterally to the inferior epigastric vessels.

41

Nerves of Inguinal Region

- Iliohypogastric (L₁)
- Ilioinguinal (L₁)
- Genitofemoral (L_{1,2}):
 - genital branch enters deep inguinal ring, passes in spermatic cord to supply the cremaster muscle
 - femoral branch to skin of thigh



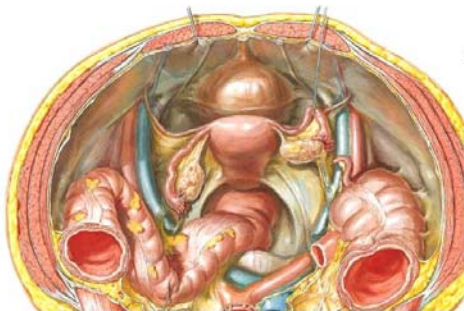
Slide 41.

The genitofemoral nerve descends on the anterior surface of the psoas muscle, dividing just above the inguinal ligament into a genital branch (entering the spermatic cord through the deep inguinal ring) and a femoral branch (entering the thigh by passing posterior to the inguinal ligament). The genital branch is motor to the cremaster muscle, and the femoral branch is sensory to the skin of the superior anteromedial thigh.

42

Deep Ring in Females

- Round ligament of uterus
- Lateral to inferior epigastric vessels



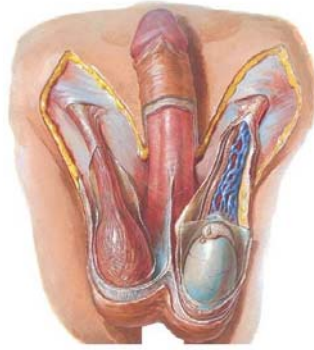Netter 362

Slide 42.

In females, the round ligament of the uterus passes through the transversalis fascia at the deep inguinal ring, lateral to the inferior epigastric vessels. The round ligament of the uterus (a developmental derivative of the gubernaculum), is attached to the uterus near the uterine tubes. It passes out of the pelvis through the deep inguinal ring, in a path similar to the vas deferens in the male.

Scrotum

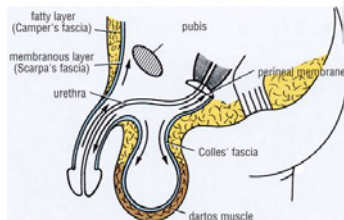
- Cutaneous sac
- Contents:
 - Spermatic cord
 - Epididymis
 - Testis
- Sperm production
- Scrotal septum
- Scrotal raphe
- 2 layers:
 - Skin
 - Tunica dartos (smooth muscle)



Netter 387

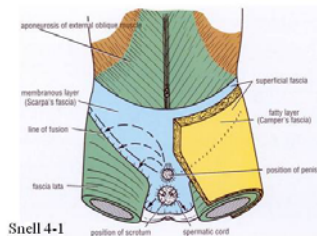
Slide 43.

The scrotum is a cutaneous pouch that contains the testis, epididymis, and lower end of the spermatic cord. Its position outside the body permits the lower temperature necessary for sperm production. An incomplete scrotal septum divides the scrotum into right and left halves. The scrotum has two layers, the skin and tunica dartos. Tunica dartos is closely applied to the skin, contains little or no fat, consists largely of smooth muscle fibers, and causes wrinkling of the scrotal skin. Deep to tunica dartos are layers continuous with external spermatic fascia, cremasteric fascia, and internal spermatic fascia that cover the testis outside the parietal layer of the tunica vaginalis.



Scrotal Layers

- Fatty layer of anterior abdominal wall superficial fascia (Camper's fascia) replaced by dartos muscle (smooth muscle) in scrotum
- Scarpa's fascia continuous with Colle's fascia in perineum, including scrotum



Snell 4-1

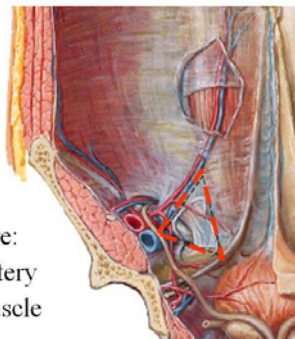
Slide 44.

The fatty layer of the superficial fascia of the lower anterior abdominal wall (Camper's fascia) is continuous with the tunica dartos layer of the scrotum, where it is replaced by smooth muscle. The membranous layer in the abdomen (Scarpa's fascia) is continuous with Colle's fascia in the perineum, including the scrotum.

Hesselbach's Triangle and Inguinal Hernias

The borders of inguinal triangle are:

- Lateral: inferior epigastric artery
- Medial: rectus abdominis muscle
- Inferior: inguinal ligament.



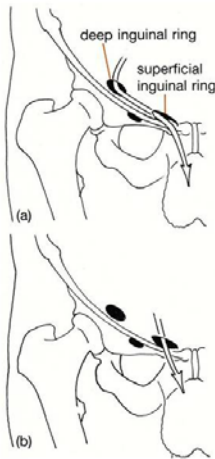
Netter 253

Slide 45.

In the case of an inguinal hernia, there is a protrusion of the peritoneal sac through a weakened region of the anterior abdominal wall. Hesselbach's triangle is a potential site for the occurrence of a direct inguinal hernia.

Inguinal Hernias

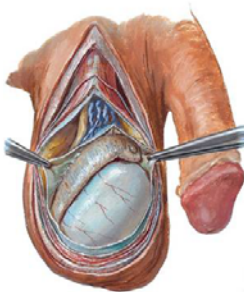
- Indirect inguinal hernia:
 - through deep ring
 - anterior to Hesselbach's triangle
 - through superficial ring
- Direct inguinal hernia:
 - through Hesselbach's triangle
 - through superficial ring



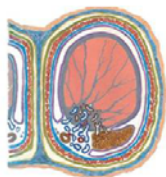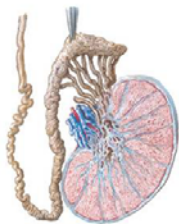Testis

The coverings of testis in scrotum are:

- The external spermatic fascia
- The cremasteric fascia
- The internal spermatic fascia
- The Tunica vaginalis, with parietal and visceral layers.



Netter 387



Netter 390

Slide 46.

Indirect inguinal hernias are the most common type of hernia to occur in the inguinal region. This occurs when the peritoneal sac passes into the inguinal canal via the deep inguinal ring. The sac continues to protrude through the superficial ring and can reach as far as the scrotum. The indirect hernias are considered to be “congenital” because patency of the processus vaginalis can lead to this condition. Indirect hernias are considered “acquired.” With a weakened abdominal wall, a protrusion of the peritoneal sac can occur at the site of Hesselbach’s triangle. This type of hernia leaves the abdomen and enters the scrotum by passing through the superficial ring.

Slide 47.

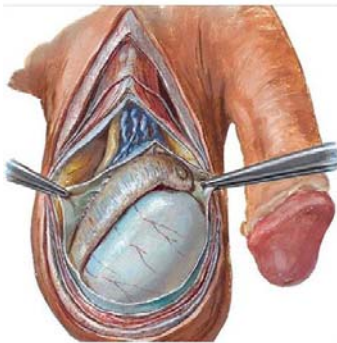
The testis is made up of seminiferous tubules and encased in connective tissue. Tunica albuginea is a thick connective tissue layer found on the surface of the testis just deep to the tunica vaginalis. The testis is contained within the same layers as the spermatic cord: internal spermatic fascia, cremasteric fascia, and internal spermatic fascia.

Slide 48.

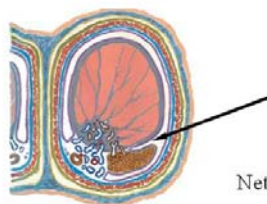
The tunica vaginalis is a double-walled serous sac with an outer parietal layer and an inner visceral layer directly applied to the surface of the testis and the epididymis. The visceral layer is thin and transparent and fused to the thick, white connective tissue capsule of the testis, the tunica albuginea. In cross section, the visceral layer covers the anterior, lateral, and medial surfaces of the testis, but not the posterior surface. This is because the testis descends posterior to but not within the processus vaginalis. The parietal layer lies immediately internal to the internal spermatic fascia. The cavity between the testis and the epididymis is the sinus of the epididymis.

Tunica Vaginalis

- Posterior to serous sac
- Two layers, parietal layer and visceral layer
- Reflection between epididymis and testis forms sinus of epididymis.



Netter 387

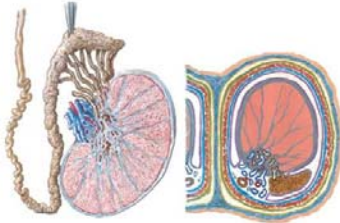


Netter 390

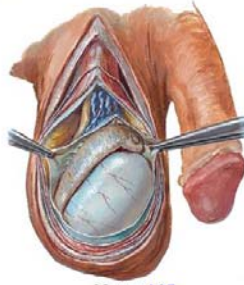
Epididymis

Is Posterolateral to testis:

- ≈ 20 feet, coiled tube
- Storage of sperm
- Efferent ductules to head
- Tightly coiled body
- Vas deferens begins at tail



Netter 390

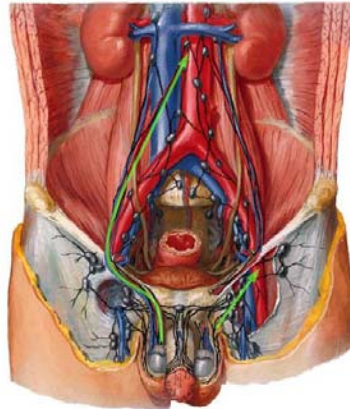


Netter 387

Lymphatic Drainage

- Scrotum: to the superficial inguinal nodes and then into the deep inguinal nodes, to the external iliac nodes
- Testis: directly to the lumbar (para-aortic) nodes.

Netter 408



The End.

Slide 49.

The epididymis is a long and coiled duct posterolateral to the testis, whereas the seminiferous tubules of the testis produce sperm. The primary function of the epididymis is sperm storage. The duct is extremely long. The efferent ductules are coiled to form a mass as the head of the epididymis. The head of the epididymis drains into the body of the epididymis (i.e. the true epididymis). The tail of the epididymis is where the vas deferens begins.

Slide 50.

Lymph from the scrotum drains directly to superficial inguinal node, located just inferior to the inguinal ligament near the drainage of the great saphenous vein into the femoral vein. However, lymph from the testis follows its blood supply to the posterior abdominal wall to drain to lumbar (or para-aortic) nodes.

Slide 50.

The end.

Abdominal Esophagus, Stomach and Small Intestine

By Thierry Bacro, Ph.D

Center for Anatomical Studies and Education
 Department of Regenerative Medicine and Cell Biology
 College of Medicine
 Medical University of South Carolina

Introduction.

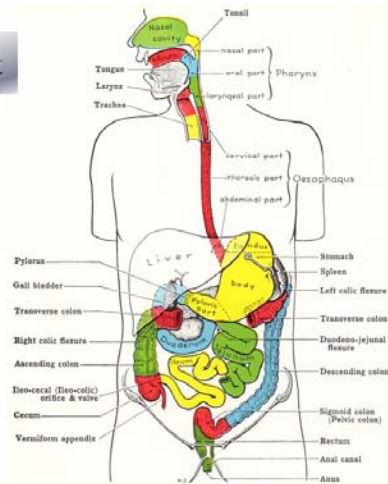
Slide 1: In this lecture, we will the essential features of the abdominal esophagus, stomach and small intestine. We will also discuss the blood supply, the innervation and the lymphatic drainage of these structures.

2. **Digestive Tract**

Consists of: Mouth, pharynx, esophagus, stomach, small intestine and large intestine

Solid food: become chyme in stomach, processed several hours before passing through pyloric sphincter into small intestine.

Snell



Slide 2.

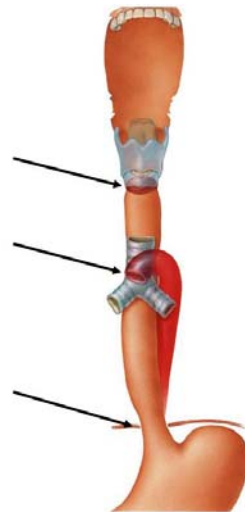
The digestive tract consists of the mouth, pharynx, esophagus, stomach, small intestine, and large intestine. Solid food is made into the semi-liquid chyme in the stomach by mixing gastric secretions with the solid food. Solid food is usually processed for several hours in the stomach before passing (as chyme) through the pyloric sphincter into the small intestine. Liquids that are swallowed pass quickly through the stomach to reach the small intestine.

3. **Esophagus**

Has 3 constrictions:

- C₆ vertebrate level
- Posterior to left main bronchus
- Entrance to diaphragm at the T₁₀ level

Netter 233



Slide 3.

The esophagus has three constrictions:

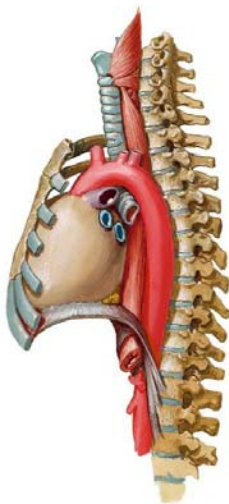
1. At its beginning at the C₆ vertebral level (narrowest of the 3)
2. As it passes posterior to left main bronchus
3. As it passes through the diaphragm at the T₁₀ vertebral level.

4

Topography of the Esophagus

The esophagus ends 1/2 inch below the diaphragm at the T₁₁ vertebral level when it enters the cardiac portion of the stomach.

Netter 233

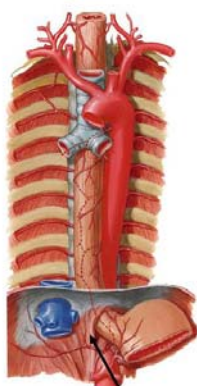

Slide 4.

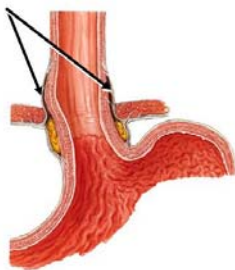
The esophagus ends about 1/2 inch below the diaphragm at the T₁₁ vertebral level when it enters the cardiac portion of the stomach. This opening in the wall of the stomach is the cardiac orifice.

5

Phrenicoesophageal Ligament



Phrenicoesophageal ligament



Netter 236 and 237

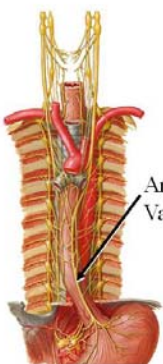
Right crus of the diaphragm

Slide 5.

The esophagus has a physiological sphincter at its lower end, but such is not demonstrable anatomically. The inferior fascia of the diaphragm is attached to the esophagus by the phrenicoesophageal ligament. This ligament extends superiorly for several centimeters through the esophageal hiatus and also inferiorly toward the cardioesophageal junction. This ligament is important in preventing hiatal herniation and allowing independent movement of the esophagus and diaphragm during swallowing and breathing.

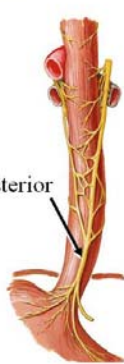6

Nerves of the Esophagus

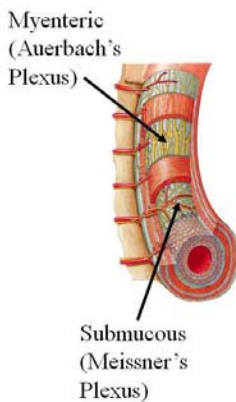


Anterior view

Anterior & Posterior Vagal Trunks



Posterior view



Myenteric (Auerbach's Plexus)

Submucous (Meissner's Plexus)

Netter 240

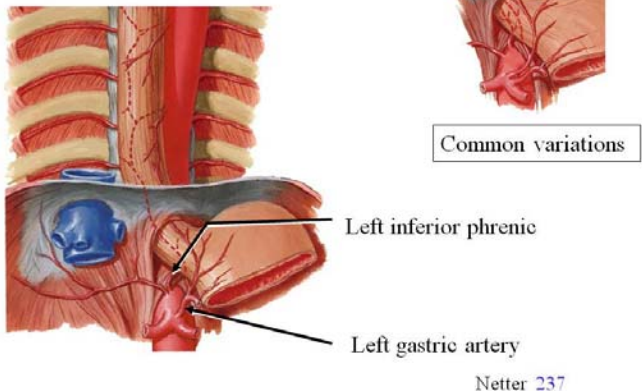
Slide 6.

The nerves that pass through the esophageal opening of the diaphragm are the anterior and posterior vagal trunks. These may be singular or multiple trunks as evident in this slide. Postganglionic parasympathetic neuron cell bodies are located in the wall of the digestive tract. There are two locations for aggregations of these cell bodies:

1. Between the longitudinal and circular layers of muscle is the myenteric plexus (Auerbach's plexus) which is mostly concerned with regulation of the muscle fibers of these two layers
2. In the submucosa is the submucosal plexus (Meissner's plexus) which is mostly concerned with the regulation of glands of the mucosa and the smooth muscle of the muscularis mucosae.

7

Arterial Supply



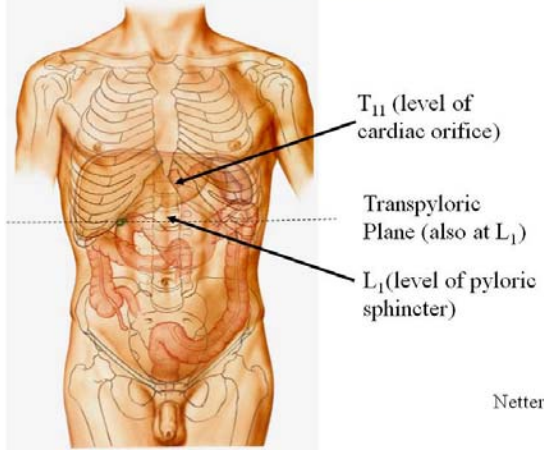
Netter 237

Slide 7.

The arterial supply to the abdominal portion of the esophagus is by branches of the left gastric and left inferior phrenic arteries, coming from the abdominal aorta. The veins (not shown) of the abdominal portion of the esophagus drain into the left gastric vein.

8

Regions and Planes of Abdomen



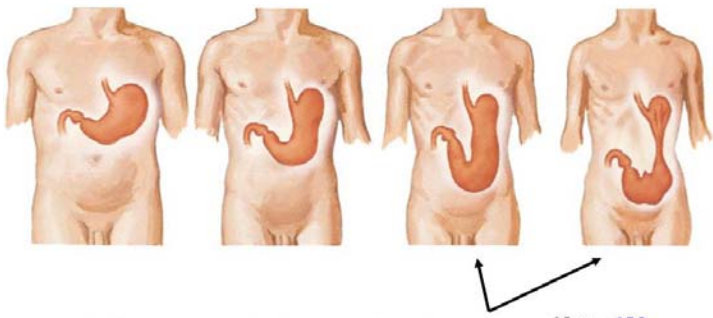
Netter 286

Slide 8.

The stomach lies mainly under the cover of the ribs and costal cartilages in the upper portion of the left side of the abdomen. The cardiac orifice is at the T₁₁ vertebral level and the pyloric sphincter is at the L₁ vertebral level (transpyloric plane). The stomach is anchored at its two ends but is otherwise fairly mobile. The representation of the position of the stomach in this slide is what one would see in a person of average height.

9

Position and Contour Variations of the Stomach



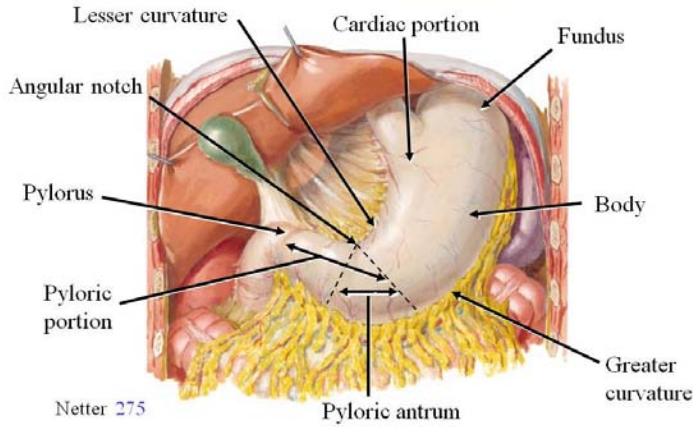
Tall thin people tend to have a J-shaped stomach. Netter 275

Slide 9.

Tall, thin individuals tend to have a J-shaped stomach as seen in this slide. In some cases the most dependent portion of the stomach may be as low as the level of the pubic symphysis.

10

Subdivisions of Stomach



Netter 275

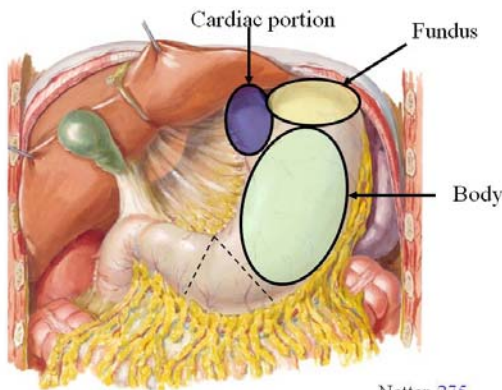
Slide 10 and 11

The gross subdivisions of the stomach are:

1. Cardia: the portion around the esophageal opening
2. Fundus: the portion above the esophageal opening
3. Body: the portion between the esophageal opening and the angular notch of the lesser curvature
4. Pyloric portion: to the right of the angular notch
 - A. Pyloric antrum: gradually narrowing portion just to the right of the angular notch
5. Pylorus: narrow portion with thick muscular wall (pyloric sphincter) and narrowed lumen (pyloric canal)

11

Subdivisions of Stomach

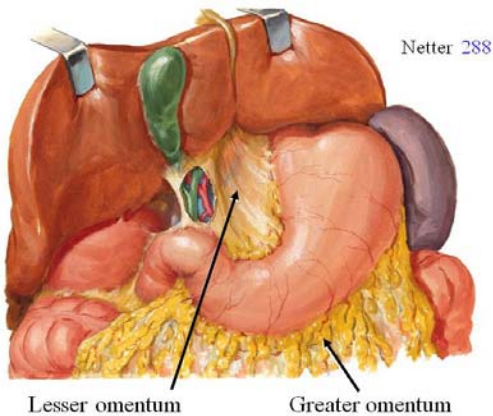


Netter 275

The stomach also possesses two surfaces, anterior and posterior, and two curvatures, greater and lesser. The lesser curvature is to the right, and the greater curvature is to the left.

12

Greater and Lesser Omenta

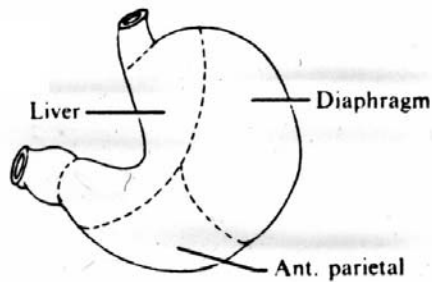


Netter 288

Slide 12.

Attached to the greater curvature is the greater omentum and attached to the lesser curvature is the lesser omentum.

Anterior Surface of Stomach



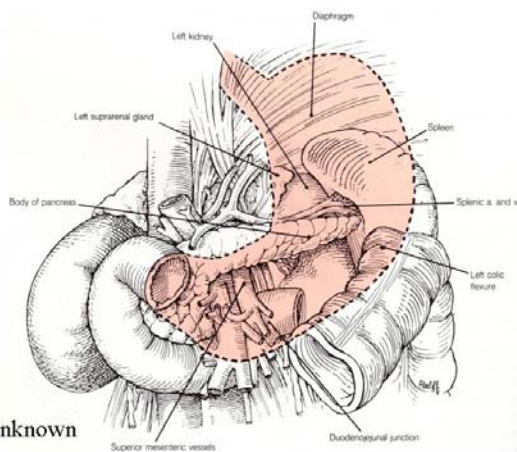
Author Unknown

Slide 13.

The anterior surface of the stomach is related as follows:

- Right portion: left and quadrate lobes of the liver
- Left portion: upper part is related to the diaphragm
- Lower part is related to the anterior abdominal wall

Structures Forming the Bed of the Stomach



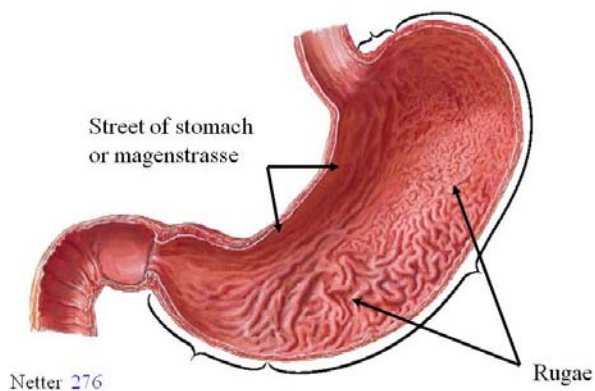
Author Unknown

Slide 14.

The posterior surface (plus peritoneum) forms the anterior wall of the omental bursa. The stomach is related to the following structures on the posterior wall of the omental bursa which forms the bed of the stomach when in the supine position:

- Diaphragm
- Spleen
- Left suprarenal gland
- Left kidney
- Pancreas
- Left colic flexure
- Transverse mesocolon

Mucosa of Stomach

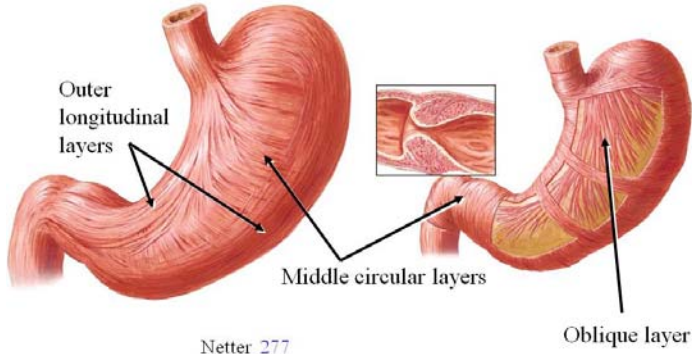


Netter 276

Slide 15.

The mucosa of the stomach is thrown into folds which are named rugae. These rugae are organized into longitudinal folds most conspicuously along the lesser curvature of the stomach. This channel along the lesser curvature is the street of the stomach or *magenstrasse*.

Muscular Layers of the Stomach



Slide 16.

The muscle layers of the stomach can be divided from outside inward into:

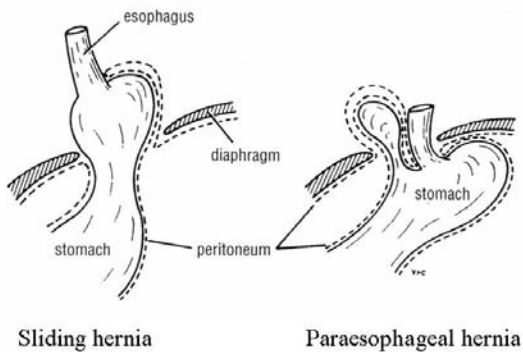
- Longitudinal layer: best developed along the curvatures
- Circular layer: principal part of the muscular layer and best developed at the pyloric sphincter
- Oblique layer: radiates from the cardia over the anterior and posterior surfaces of the stomach and is continuous with the deepest circular muscle fibers of the esophagus

Slide 17.

This slide depicts two types of hiatal hernias:

1. Sliding hiatal hernia: where both the abdominal part of the esophagus and the upper portion of the stomach enter the diaphragm through the esophageal hiatus
2. Paraesophageal hernia: where a portion of the upper stomach enters the esophageal hiatus to parallel the course of the lower esophagus

2 Types of Hiatal Hernias



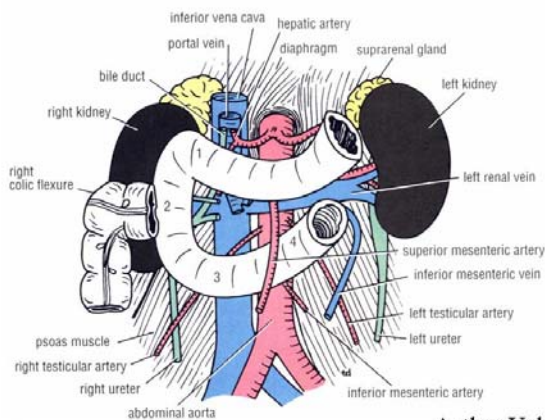
Author Unknown

Slide 18.

The duodenum is the portion of the small intestine that is the first to receive the contents of the stomach. It is principally a secondarily retroperitoneal organ that is not retroperitoneal at its beginning (first inch or so) nor at its last inch or less near the duodenojejunal flexure. The tubular duodenum is C-shaped with the open side of the C facing left. The duodenum is 10" long and is divided into 4 parts:

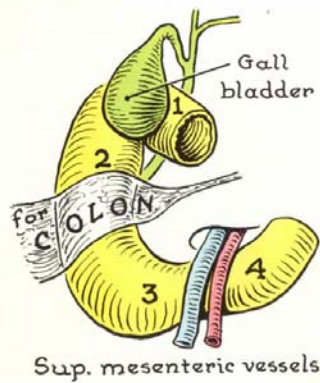
- First part (superior part): about 2" long.
- Second part (descending part): about 3" long and receives the common bile duct and the main pancreatic duct (sometimes there is also a minor pancreatic duct).
- Third part (horizontal or inferior part) is about 3 inches long and passes anterior to the aorta at the L₃ vertebral level. It is crossed anteriorly by the superior mesenteric artery.
- Fourth part (ascending part): about 2" long and ends at the upper border of the 2nd lumbar vertebra at the duodenojejunal flexure. There is a fibromuscular band, the ligament of Treitz, that attaches superiorly to the right crus of the diaphragm and inferiorly to the duodenojejunal junction.

4 Parts of the Duodenum



Author Unknown

Important Relationships of the Duodenum

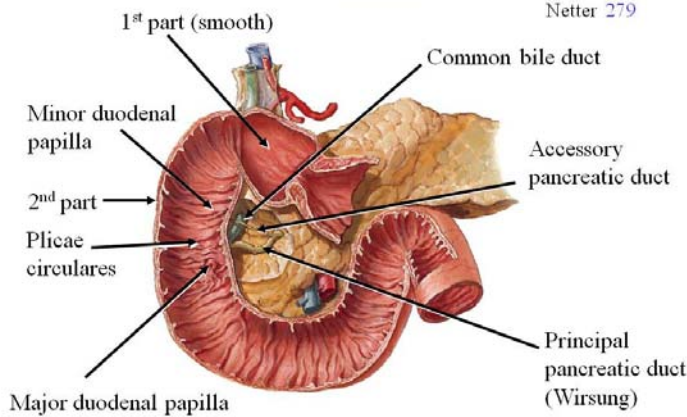


Author Unknown

Slide 19.

Some important relationships of the duodenum are shown. The gall bladder lies just anterior to the 1st part and the upper portion of the 2nd part of the duodenum. The transverse mesocolon attaches anterior to the middle of the 2nd part of the duodenum. The superior mesenteric vessels pass anterior to the 3rd part of the duodenum.

Mucosa of Duodenum

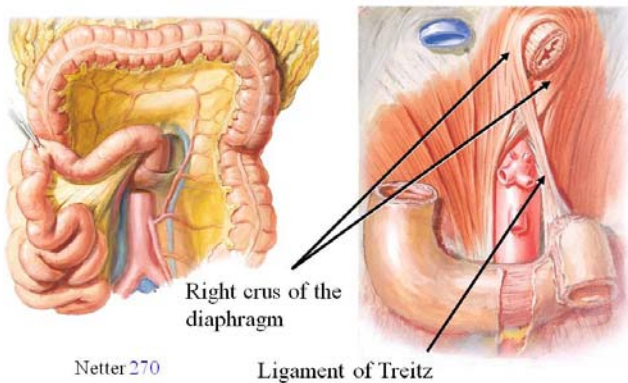


Netter 279

Slide 20.

This slide shows the interior of the pyloric portion of the stomach and the duodenum. In the first part of the duodenum, note that the mucosa is smooth; whereas, in the second part (also 3rd and 4th parts) there are circular folds (plicae circulares). In the 2nd part of the duodenum at a point two thirds of the way down its posteromedial wall there is an elevation, the greater (major) duodenal papilla, where the main pancreatic and common bile ducts empty into the duodenum. There is a hood-like fold over the major duodenal papilla and a longitudinal (vertical) fold of the mucosa below the papilla. Sometimes there is a lesser (minor) duodenal papilla on the anteromedial wall of the duodenum about an inch above the major duodenal papilla. The minor papilla indicates the position of the opening of the accessory pancreatic duct. The accessory pancreatic duct was the duct of the dorsal pancreas, and it enters the duodenum superior to the common bile duct and the main pancreatic duct (duct of the ventral pancreas).

Duodenojejunal Junction



Netter 270

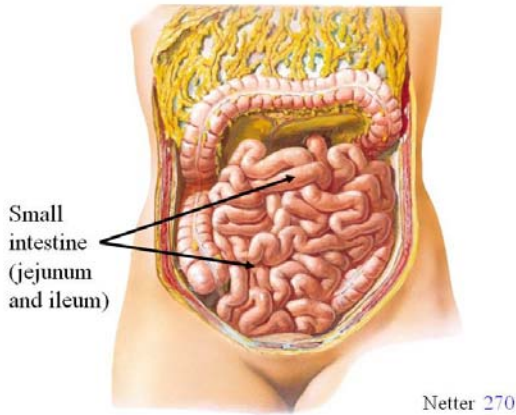
Ligament of Treitz

Slide 21.

Note the duodenojejunal junction with the ligament of Treitz (suspensory ligament of the duodenum).

22

Small Intestine

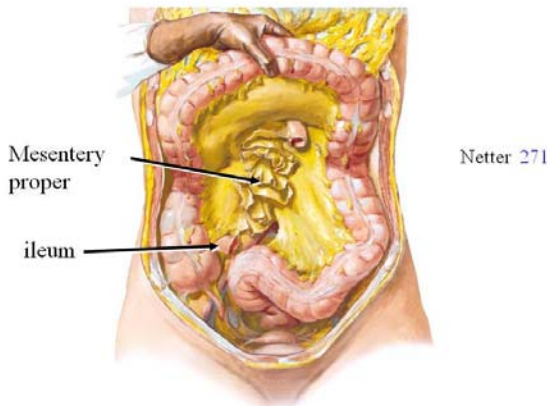


Slide 22.

The small intestine is about 21 feet long on average and is composed of three parts. The first part, the duodenum, is the shortest (about 10” long) and has already been discussed. The second part is the jejunum and is about eight feet long. The third part is the ileum and is about twelve feet long. There is no distinct boundary between the jejunum and the ileum; thus, the two together are referred to as the jejunioileum. The jejunioileum can be divided into thirds, upper, middle, and lower. The upper third is in the upper left quadrant of the abdomen, the middle third is in the middle of the abdomen, and the lower third is in the lower right abdominal quadrant and the pelvis. The ileum ends at the ileocecal junction. In summary, the successive parts of the small intestine are longer as one proceeds from its beginning to its end.

23

Mesenteric Relations of Intestines

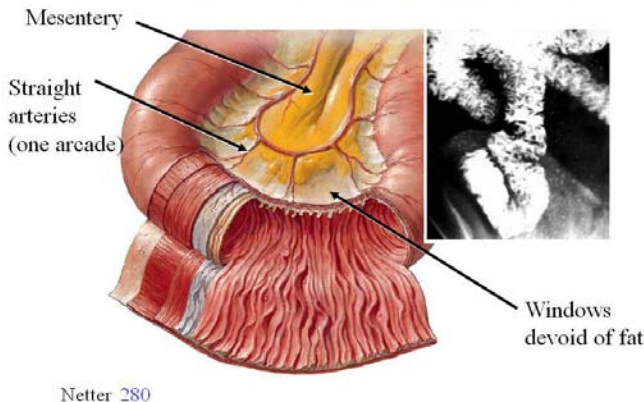


Slide 23.

The jejunum and ileum are completely covered by peritoneum; thus, they are intraperitoneal throughout their lengths. The mesentery proper anchors the jejunioileum to the posterior body wall. The upper end of the mesentery proper is attached to the posterior abdominal wall at a point just to the left of the L₂ vertebral body and overlying the 4th part of the duodenum. The mesentery proper extends downward and to the right until it ends at the level of the right sacroiliac joint. This lowest end of the mesentery proper attaches to the last part of the ileum. The total length of the posterior attachment of the mesentery proper is about six to seven inches. The mesenteric portion attaching to the left of the aorta fans out to the jejunum and that attaching to the right of the aorta, attaches to the ileum. The mesentery proper quickly fans out so that it is about 20 feet long when it attaches to the jejunioileum.

24

Mesentery, Arterial, Muscular Characteristics of Jejunum

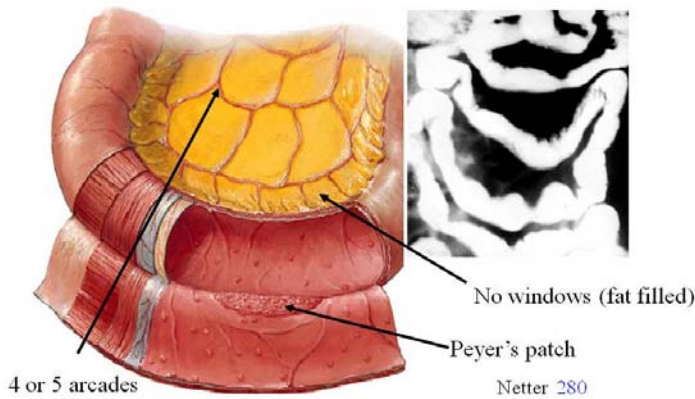


Slide 24.

This slide shows some of the characteristics of the jejunum and its mesentery. The jejunum has a greater diameter than the ileum, is thicker walled, and in life, is redder than the ileum. The mesentery proper has “windows” adjacent to the jejunum that are devoid of fat. The vasa recta are long, and there are only one or two arcades of vessels in the jejunal portion of the mesentery proper.

25

Mesentery, Arterial, Muscular Characteristics of Ileum

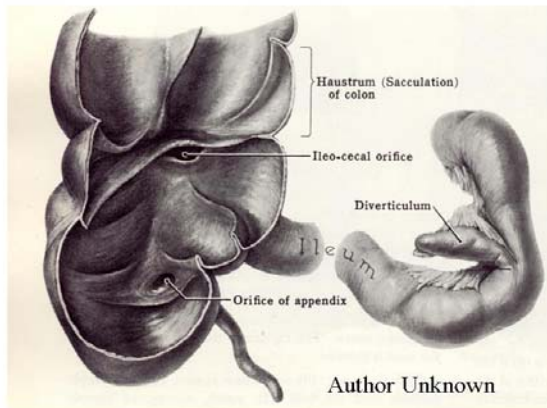


Slide 25.

This slide illustrates the characteristics of the ileum and its mesentery. The ileum, when compared to the jejunum, is thinner-walled, has a smaller diameter, and in life, is paler in appearance. There are also aggregations of lymph tissue, Peyer's patches, in the submucosa of the ileum. The plicae circulares are smaller and become less numerous as one passes toward the ileocecal junction. In the last portion of the ileum, there are no plicae circulares. There are no "windows" in the mesentery adjacent to the ileum because it is filled with fat. In the mesentery, there are usually four or five arcades of vessels and the vasa recta are short.

26

Ileal Diverticulum

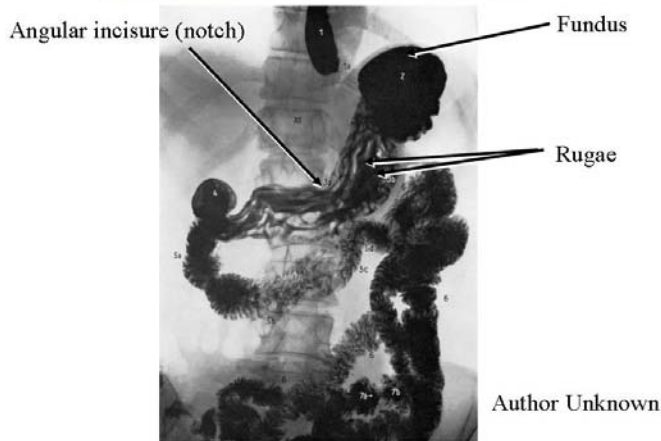


Slide 26.

Rarely, there is an outpouching of the ileum, Meckel's diverticulum, near its termination, which is the remains of the prenatal vitelline duct. This ileal diverticulum is often within 2 feet of the ileocecal junction, but may be as far as 5 1/2 feet from the ileocecal junction. The outpouching is usually less than two inches long and occurs in less than 2% of individuals. An easy way to remember the above facts is to think 2-2-2: within 2 feet of the ileocecal junction, 2 inches long, and in less than 2% of individuals.

27

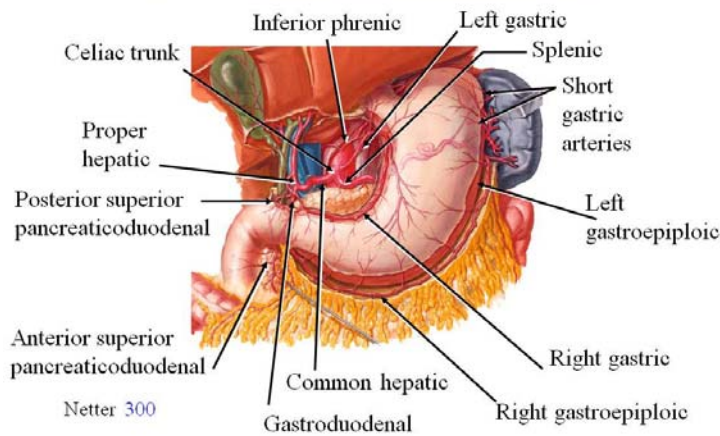
Upper GI Radiograph



Slide 27.

This is an upper GI film with contrast material to demonstrate some of the features of the stomach and small intestine. Note the fundus, the angular incisure and rugae of the stomach, the duodenal bulb, and the plicae circulares of the small intestine.

Arteries of Stomach, Liver, Duodenum, Pancreas and Spleen

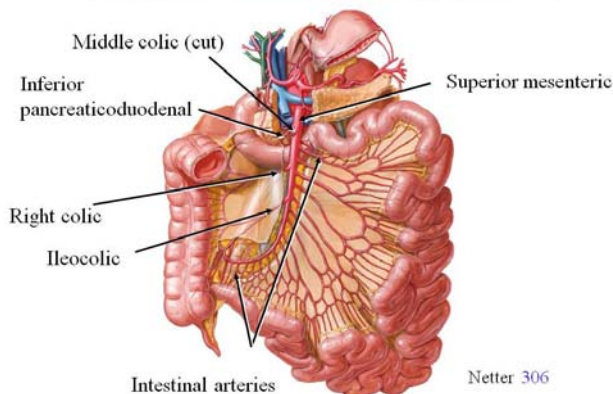


Slide 28.

The blood supply of the foregut is from the celiac artery (arises at the upper portion of the L₁ vertebral body or between T₁₂ and L₁), which supplies the lower 1/3 of the esophagus, the stomach, and the upper duodenum down to the level of the greater duodenal papilla. The celiac artery also has branches that supply the liver, gall bladder, pancreas, and spleen. The celiac artery is very short and gives rise usually to three branches; left gastric, splenic, and common hepatic. If you were looking at the face of a clock, the left gastric artery arises at one o'clock, the splenic artery at three o'clock, and the common hepatic artery at nine o'clock.

The left gastric supplies the stomach adjacent to the left portion of the lesser curvature of the stomach and the lower 1/3 of the esophagus. The splenic artery supplies pancreas, spleen, and the left portion of the stomach adjacent to the greater curvature by its branches. The short gastric arteries supply the fundus, and the left gastroepiploic (gastro-omental) supplies the left portion of the body of the stomach. The common hepatic artery ends when it branches into the gastroduodenal and the proper hepatic arteries. The proper hepatic artery usually gives rise to the right gastric artery, which supplies the right portion of the stomach adjacent to the lesser curvature. The gastroduodenal artery ends by dividing into the right gastro-omental (gastroepiploic), which supplies the right portion of the stomach adjacent to its greater curvature and the anterior superior pancreaticoduodenal artery which supplies the duodenum down to the level of the major duodenal papilla and the adjacent pancreas. The posterior superior pancreaticoduodenal artery arises from the gastroduodenal artery before it bifurcates into its two terminal branches and supplies the posterior portion of the duodenum down to the level of the greater duodenal papilla and also supplies the adjacent pancreas. Often, there is a supraduodenal artery arising from the gastroduodenal artery that supplies the first part of the duodenum.

Arteries of the Small Intestine

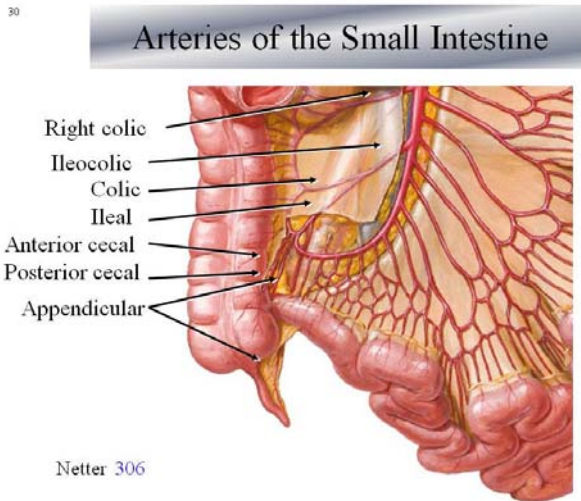


Slide 29.

The artery of the midgut is the superior mesenteric (arises at the lower portion of the L₁ vertebral body). The usual branches of the superior mesenteric artery are:

- Inferior pancreaticoduodenal: has anterior and posterior branches that supply the 3rd and 4th parts of the duodenum and the lower inch of the 2nd part of the duodenum. This vessel also supplies the adjacent portion of the pancreas.
- Intestinal: 12 to 20 branches supply the jejunoleum and can be subdivided into jejunal and ileal arteries by their terminations. These intestinal branches arise from the left side of the superior mesenteric artery.
- Middle colic artery: It enters the transverse mesocolon and branches into a right and left branch which supply the transverse colon via their straight branches (vasa recta).
- Right colic artery: It supplies the ascending colon.

- Ileocolic artery: It arises from the right side of the superior mesenteric artery and passes inferior toward the ileocecal junction behind the peritoneum.



Slide 30.

Near the ileocecal junction, the ileocolic artery divides into five branches: ileal, ascending colic, anterior cecal, and appendicular. Note the anterior cecal artery is in the superior ileocecal fold and the appendicular artery is in the posterior part of the mesoappendix.

Slide 31.

The venous drainage from the abdominal esophagus, stomach, duodenum and jejunioileum is through the portal system of veins. The veins parallel the arteries near the viscera but diverge in some cases when leaving the vicinity of the viscera. The veins drain as follows:

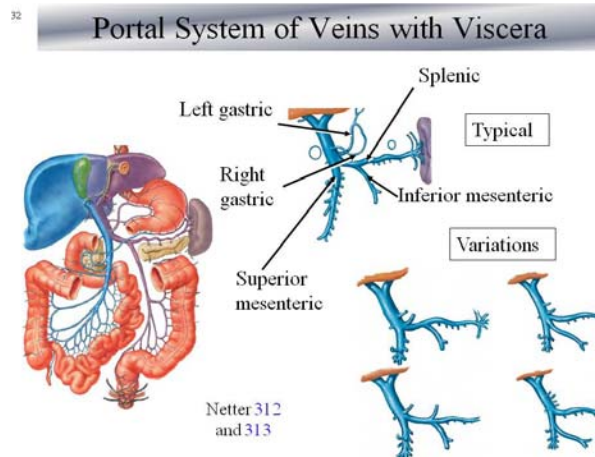
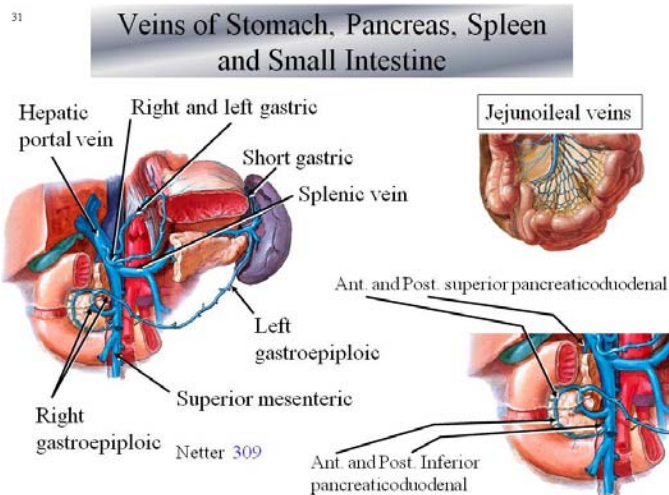
- Stomach veins:

- Right and left gastric veins drain into the portal vein.
- Right gastroepiploic vein drains into the superior mesenteric vein.
- Left gastroepiploic and short gastric veins drain into the splenic vein

- Duodenal veins:

- Anterior superior pancreaticoduodenal vein drains into the right gastroepiploic vein
- Posterior superior pancreaticoduodenal vein drains directly into the portal vein
- Anterior and posterior inferior pancreaticoduodenal veins drain into the superior mesenteric vein either directly or indirectly

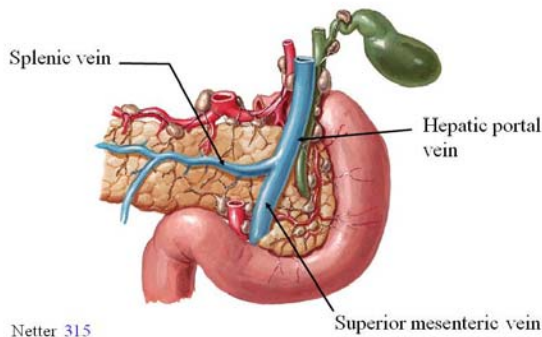
- Jejunioileal veins: These veins are named the same as the arteries they accompany, and they all drain either directly or indirectly into the superior mesenteric vein.



Slide 32. This shows the portal system of veins with viscera. There are a couple of variations from the normal in this slide in that the right gastroepiploic vein is entering the junction of the splenic with the superior mesenteric vein and the splenic vein is anterior and superior to the pancreas.

33

Posterior View of Formation of Portal Vein



Netter 315

Slide 33.

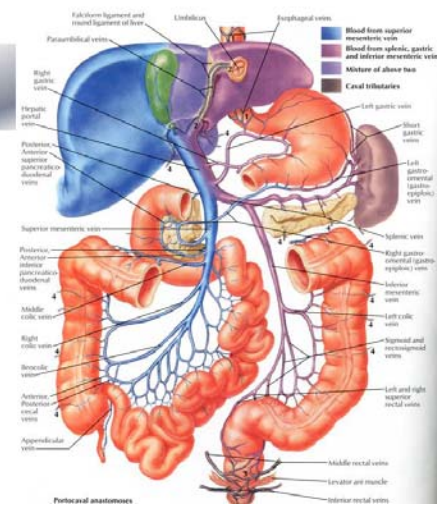
This is a posterior view illustrating the formation of the portal vein behind the neck of the pancreas by the joining of the splenic and superior mesenteric veins.

34

Portal Systemic Anastomoses

1. Esophageal
2. Paraumbilical
3. Rectal
4. Retroperitoneal

Netter 312



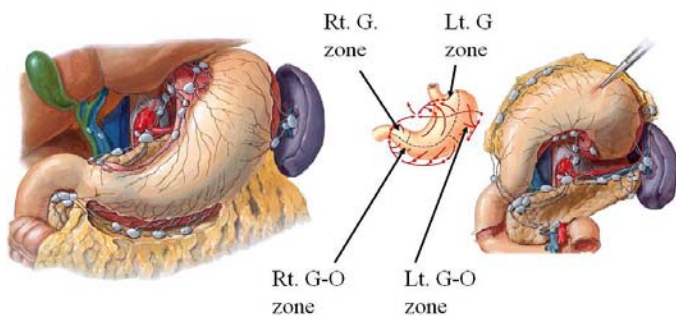
Slide 34.

Portal systemic anastomoses occur at these sites:

- Esophagus
- Anterior abdominal wall
- Rectum and anal canal
- Posterior abdominal wall
- Liver

35

Lymph Vessels and Nodes of Stomach



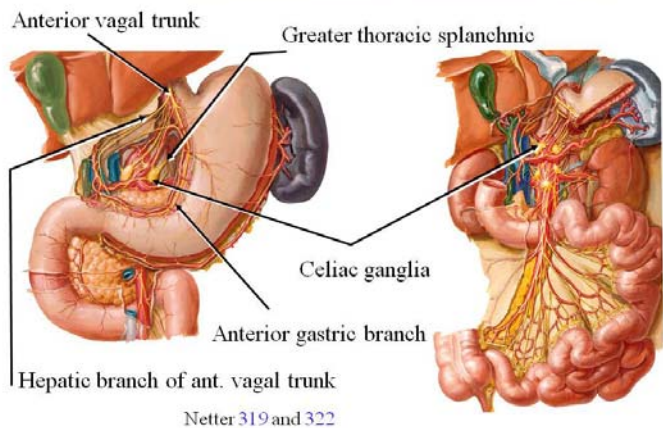
Netter 314

Slide 35.

The lymphatic drainage of the stomach can be divided into four zones, which are also the zones of arterial supply. These zones correspond to the zones of arterial supply by the right and left gastric arteries and the right and left gastroepiploic arteries. The lymphatics accompany the corresponding arteries to nodes along their course and all lymph from these channels eventually reach the celiac nodes.

36

Nerves of Stomach and Small Intestine

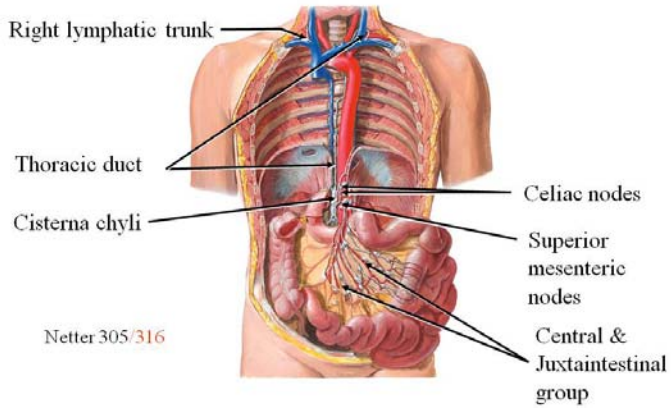


Slide 36.

The nerve supply of the stomach and small intestine is parasympathetic and sympathetic. The stomach and upper portion of the duodenum receive direct branches from the anterior and posterior vagal trunks and also branches from the celiac plexus; thus, preganglionic parasympathetic fibers reach the stomach by three routes, anterior vagal trunk, posterior vagal trunk, and celiac plexus and blood vessels. The parasympathetic fibers to the celiac ganglion come mainly from the posterior vagal trunk through its celiac branch. The preganglionic sympathetic fibers reach the celiac ganglion by way of the greater splanchnic nerves. The preganglionic sympathetic fibers synapse in the celiac ganglion and postganglionic sympathetic fibers travel with blood vessels to the abdominal esophagus, stomach and small intestine. The preganglionic parasympathetic fibers from the celiac plexus also accompany these same blood vessels to the abdominal esophagus, stomach, and small intestine.

38

Lymph Vessels and Nodes of the Small Intestine



Slide 37.

The thoracic duct receives the lymphatic drainage from the abdominal esophagus and stomach after it passes through the celiac nodes and enters the intestinal trunk which then empties into the cisterna chyli, if present, or the left lumbar trunk (if there is no cisterna chyli)

Slide 38.

The end.

The End.

Liver, gallbladder, pancreas, and spleen.

By Thierry Bacro

Center for Anatomical Studies and Education
Department of Regenerative Medicine and Cell Biology
College of Medicine
Medical University of South Carolina

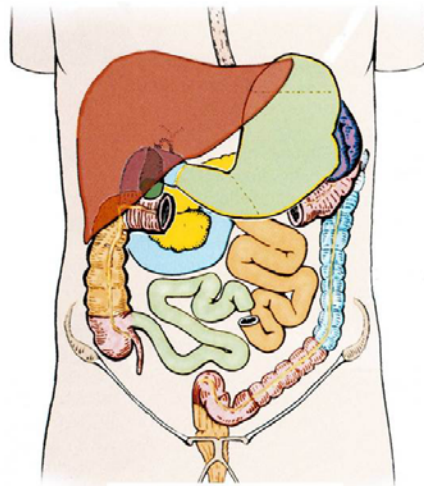
Slide 1.

In this lecture we will describe the liver, gallbladder, pancreas, and spleen. For each of these organs, characteristic anatomical features, blood supply, venous supply, and lymphatic drainage will be described. In addition, basic information will be provided about the function of each organ.

2

Liver

- Is the largest internal organ and gland
- Is found in the upper right quadrant
- Its functions are:
 - glycogen storage
 - bile production
 - detoxification



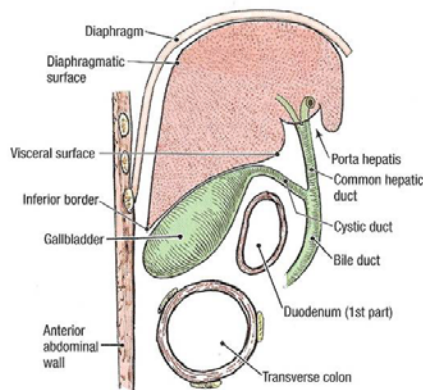
Grant's dissector 4.23

Slide 2.

The abdominal viscera involved in digestion are comprised of a series of tubes, i.e. G.I. tract, and accessory glands. One of these glands is the liver. The liver is the largest internal organ, in the body, as well as the largest gland. This large organ, located in the upper right quadrant, has multiple functions. Briefly, the liver is responsible for glycogen storage, bile production (to aid in digestion), and detoxification.

3

Liver Relationships



Grant's dissector 4.26

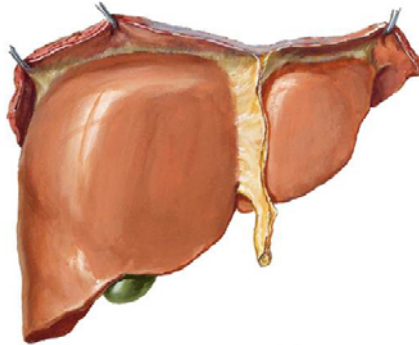
Slide 3.

This sagittal section of the abdomen demonstrates the relationship of the liver to the diaphragm and nearby organs. The diaphragmatic surface of the liver is convex, whereas the visceral surface of the liver is concave.

Liver Anterior View

Note the following:

- The right and left lobes
- The fundus of the gallbladder
- The falciform ligament
- The round ligament of the liver
- The sharp inferior border

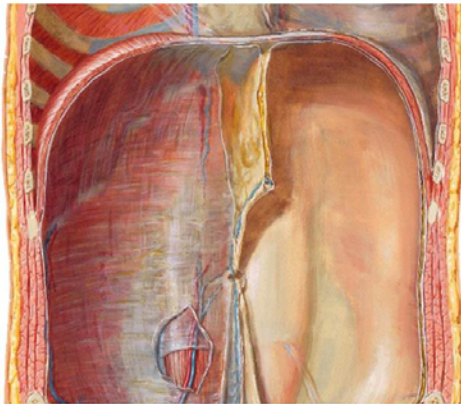

Netter 277

Slide 4.

In this anterior view of the liver, it is evident that the majority of the liver is covered by visceral peritoneum. Note the right and left functional lobes of the liver. At certain locations, folds or reflections of peritoneum forms ligaments, one of which is featured here. The falciform ligament anchors the liver to the anterior abdominal wall. In addition, the round ligament (ligamentum teres), the remnant of the umbilical vein, is ensheathed in the free margin of the falciform ligament. Note the sharp inferior border of the anterior surface of the liver where the diaphragmatic and visceral surfaces meet. The fundus of the gallbladder projects from under the sharp inferior border of the liver.

Falciform Ligament



Netter 247

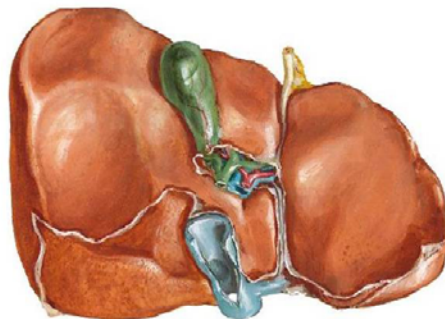
Slide 5.

In this posterior view of the anterior abdominal wall, one can appreciate the relationships between the falciform ligament, ligamentum teres, and the diaphragm. Try to imagine the situation of the liver in this space.

Visceral Surface

Note the following:

- The gallbladder
- The ligamentum teres hepatis
- The porta hepatis
- The IVC
- The hepatic veins



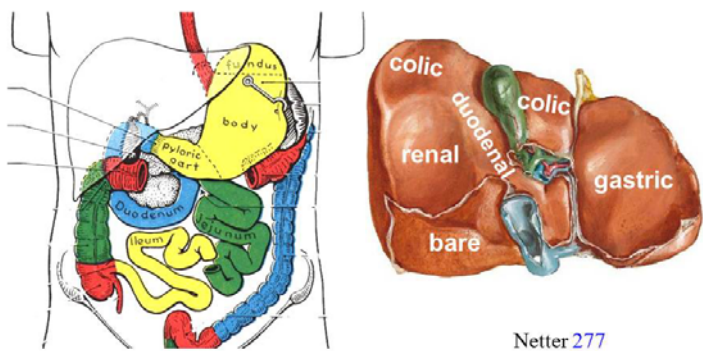
Netter 277

Slide 6.

When viewing the visceral surface of the liver, note the positions of the gallbladder, porta hepatis, inferior vena cava, and hepatic veins. The contents of the porta hepatis include the portal vein, hepatic artery, and hepatic ducts. In addition, you should be able to recognize the ligamentum teres and ligamentum venosum.

7

Relationships



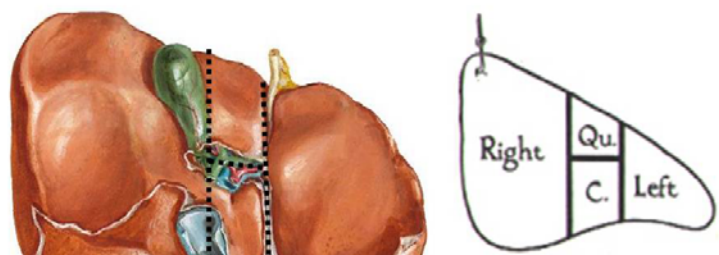
Grant 2-26

Netter 277

Slide 7.
 The liver is in such close proximity to the adjacent viscera that the organs make impressions in the liver's visceral surface. Note the gastric impression on the visceral surface of the left lobe of the liver. The gastric impression is formed by the esophagus and stomach. The visceral surface of the right lobe of the liver has duodenal, renal, and colic impressions indicative of the duodenum, right kidney/adrenal gland, and colon, respectively. In addition, spaces of the visceral surface of the liver are occupied by the gallbladder and inferior vena cava.

8

4 Anatomical Lobes



Netter 277

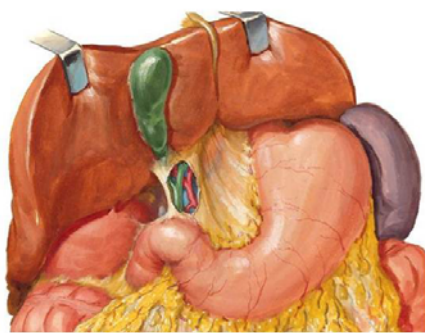
Grant's atlas 2-54C

Slide 8.
 When viewing the visceral surface of the liver, one can divide the organ into four anatomical lobes based on these structures. If you draw a line through the gallbladder and inferior vena cava, through the fissures for ligamentum teres and ligamentum venosum, and a transverse line at the level of the porta hepatis, the resultant "H" demarcates the four lobes. The quadrate lobe has four sides. The caudate lobe is tail-like in appearance.

9

4 Anatomical Lobes

- Observe the following lobes:
- Left
 - Right
 - Quadrate
 - Caudate (posterior to lesser omentum)



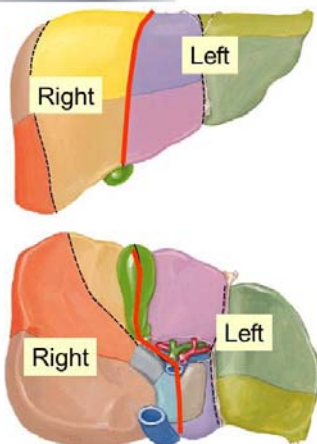
Netter 278

Slide 9.
 You can use these relationships to identify the four anatomical lobes *in situ* (in the body). The left lobe is medial to the fissure for ligamentum teres. The right lobe is lateral to the gallbladder. The quadrate lobe is anterior and between the gallbladder and ligamentum teres. The caudate lobe is posterior to porta hepatis, and, in this view, is posterior to the lesser omentum.

10

2 Functional Lobes

- Diaphragmatic surface: separated by a line from the fundus of gallbladder to the IVC
- Visceral surface: separated by a line through the gallbladder bed to the IVC fossa



Netter 289 4th ed.

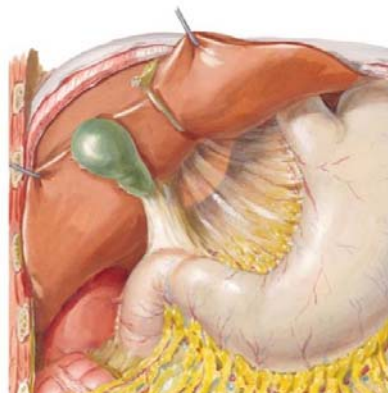
Slide 10.

We have been defining the four anatomical lobes. The liver can alternatively be divided into functional lobes and segments. When looking at the diaphragmatic surface of the liver, the line from the fundus of the gallbladder to the inferior vena cava separates the right and left functional lobes. From the visceral surface, a line can be drawn through the gallbladder to the bed of the inferior vena cava to delineate the two functional lobes.

11

Peritoneal Ligaments

- Observe the:
- Falciform ligament
 - Hepatogastric ligament
 - Hepatoduodenal ligament



Netter 267

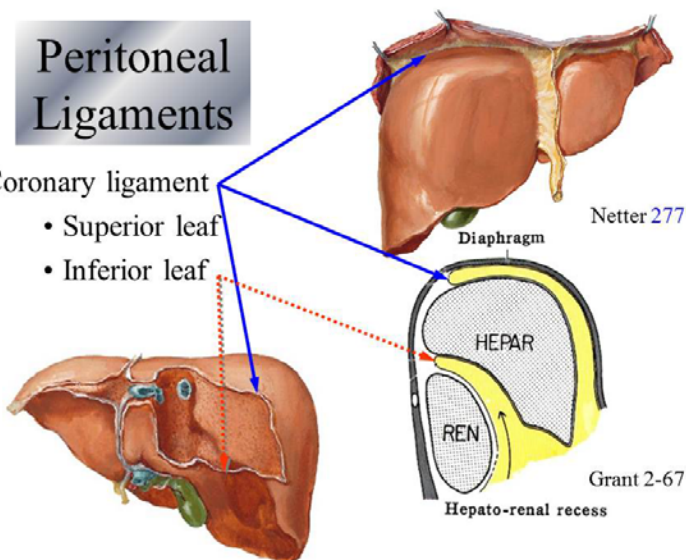
Slide 11.

As mentioned before, the liver is covered with visceral peritoneum. And, as you have seen in previous lectures, this thin tissue layer can form folds or ligaments connecting organs to one another, as well as compartmentalizing the abdominal cavity. Here you can see the falciform ligament which we just saw is also attached to the anterior abdominal wall. In addition, we can see here that the liver is connected to the lesser curvature of the stomach via the hepatogastric ligament. It is also connected to the first part of the duodenum by the thicker hepatoduodenal ligament. Together, the hepatogastric and hepatoduodenal ligaments form the lesser omentum.

12

Peritoneal Ligaments

- Coronary ligament
 - Superior leaf
 - Inferior leaf



Netter 277

Grant 2-67

Hepato-renal recess

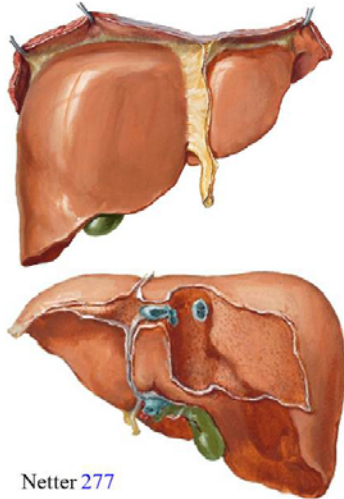
Slide 12.

The coronary ligament is the point of reflection of peritoneum from the diaphragm to the liver, anteriorly. The superior leaf marks the location where the peritoneum covering the inferior diaphragmatic surface reflects to cover the superior surface the right lobe of the liver. The inferior leaf is the point where the visceral peritoneum covering the inferior surface of the liver reflects onto the right kidney.

13

Triangular Ligaments

- Left triangular ligament: to the left of the falciform ligament
- Right triangular ligament: joining of the superior and the inferior leaves of the coronary ligament.



Slide 13.

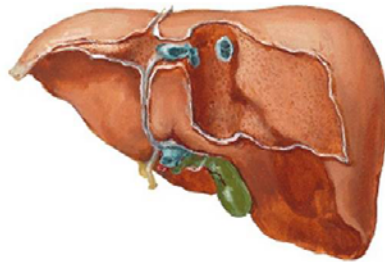
The left triangular ligament is found to the left of the falciform ligament. The right triangular ligament is present at the junction of the superior and inferior leaves.

14

Bare Area of the Liver

The bare area of liver is:

- on the posterior surface
- not covered by visceral peritoneum
- surrounded by the coronary ligaments.



Slide 14.

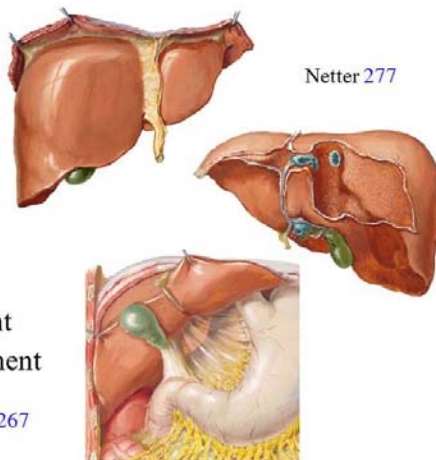
The bare area of the liver is a rather large area on the posterior surface of the liver which is not covered by visceral peritoneum. The bare area is bordered by the superior and inferior leaves.

15

Peritoneal Ligaments: Summary

- Falciform ligament
- Coronary ligament:
 - Superior leaf
 - Inferior leaf
- Triangular ligaments:
 - Right
 - Left
- Hepatogastric ligament
- Hepatoduodenal ligament
- Bare area

Netter 267



Slide 15.

Summary of peritoneal ligaments of the liver.

16

Gallbladder

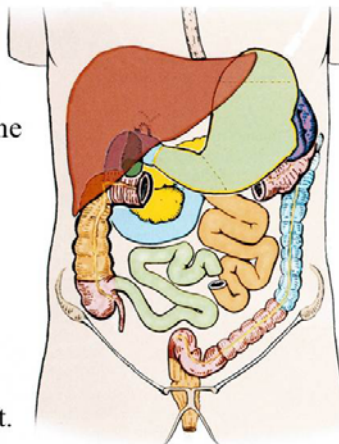
Note the following:

- Is in the upper right quadrant
- Is on the visceral surface of the liver

Its Functions are:

- To store the bile
- To concentrates the bile

Note that gallstones can cause pain in the upper right quadrant.



Grant's Dissector 4.23

Slide 16.

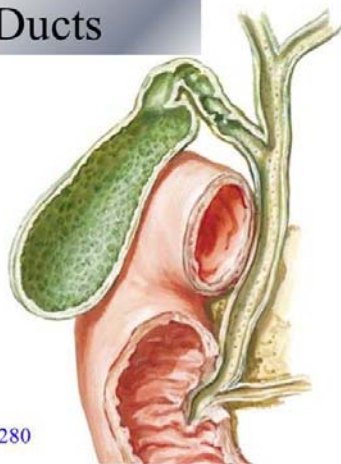
The gallbladder is located along the visceral surface of the liver. The gallbladder is a small sack which functions to store and concentrate bile. (Recall that bile is made by the liver.) At times, components of the bile can form rock-like structures called gallstones. Gallstones can cause pain in the upper right quadrant.

17

Gallbladder and Biliary Ducts

Observe the following:

- Fundus
- Body
- Neck
- Cystic duct
- Right hepatic duct
- Left hepatic duct
- Common hepatic duct
- Common bile duct.



Netter 280

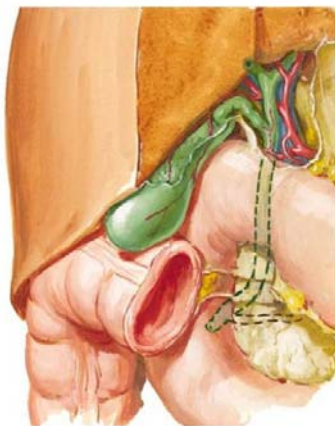Slide 17.

The gallbladder itself can be divided into three parts: the fundus, body, and neck. The fundus is the most distal portion of the gallbladder. The neck is attached to the cystic duct. The gallbladder is connected to the liver and duodenum by a system of ducts. Bile travels via right and left hepatic ducts from the right and left lobes of the liver. The right and left hepatic ducts merge to form the common hepatic duct. At this point, the bile can either continue to the duodenum via the common bile duct, or it can back up into the valvular cystic duct and into the gallbladder. The latter occurs when the sphincter of the hepatopancreatic ampulla (Sphincter of Oddi) is closed.

18

Gallbladder Relationships

- In contact with the anterior visceral surface of the liver with no visceral peritoneum between the two structures
- The fundus is in contact with the anterior abdominal wall
- The duodenum is in contact with the posterior surface of the gallbladder
- The hepatic flexure of the colon is found posterior and inferior to the body of the gallbladder.



Netter 280

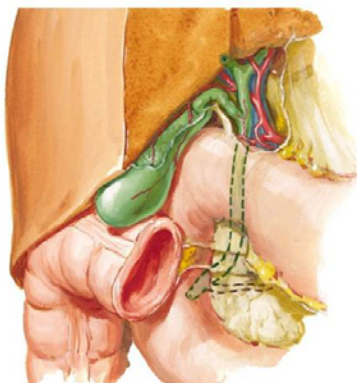
Slide 18.

The anterior surface of the gallbladder is in contact with the visceral surface of the liver. The fundus of the gallbladder is the portion that is typically depicted as protruding anteriorly from the inferior border of the liver. The posterior surface of the gallbladder is contact with the duodenum. A portion of the colon is found posteriorly and inferiorly to the body of the gallbladder.

Biliary Ducts Relationships

The common bile duct is:

- Posterior to 1st part of duodenum and head of pancreas
- Joined by the major pancreatic duct to form the hepatopancreatic ampulla emptying in the duodenum.

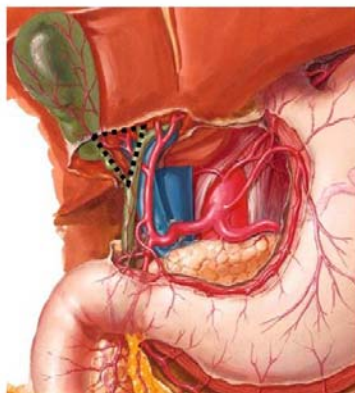


Netter 280

Blood Supply

The blood supply is by the:

- Celiac trunk
- Common hepatic artery
- Gastroduodenal artery
- Proper hepatic artery
- Right hepatic artery
- Left hepatic artery
- Cystic artery (Note the Cystic triangle of Calot).

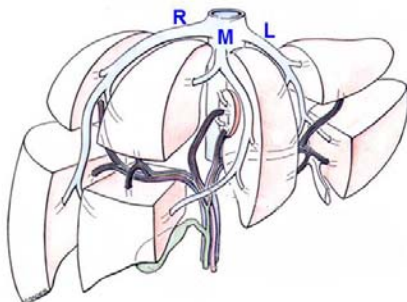


Netter 283

Hepatic Veins

Observe the following:

- The 3 hepatic veins: right, middle, left
- Location between the functional segments
- NOT associated with the porta hepatis
- Drains into the IVC within liver.



Moore & Dalley 2-53A

Slide 19.

The common bile duct runs posteriorly to the duodenum and head of the pancreas. The infraduodenal portion of the common bile duct is joined by the major pancreatic duct to form the hepatopancreatic ampulla. This tube then empties into the duodenum by way of the Sphincter of Oddi.

Slide 20.

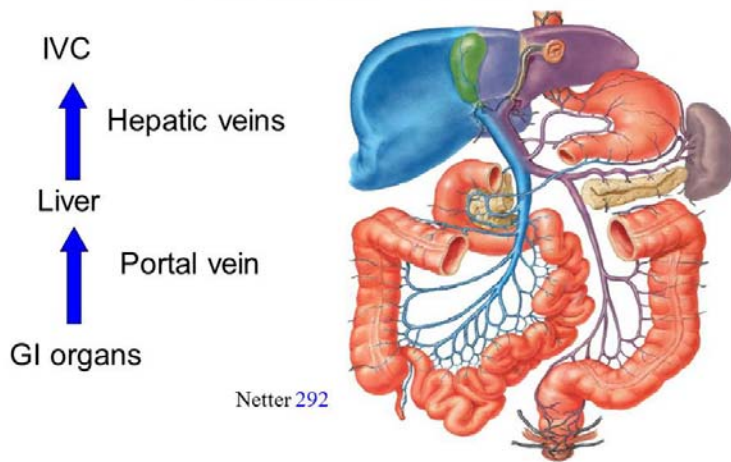
The common hepatic artery supplies blood to the liver. This is a branch off of the celiac artery or celiac trunk. The common hepatic artery runs along the superior border of the pancreas. The gastroduodenal artery branches off of the common hepatic artery and runs inferiorly. The gastroduodenal artery runs posteriorly to the duodenum with the common bile duct. After the gastroduodenal artery branches off of the common hepatic artery, it continues toward the porta hepatis as the proper hepatic artery. The proper hepatic artery divides into the right and left hepatic arteries which supply the right and left functional lobes of the liver, respectively. The cystic artery, which supplies the gallbladder, is usually a branch of the right hepatic artery within the cystic triangle of Calot. The cystic triangle of Calot has three borders: the liver (superiorly), the common hepatic duct (left), and the cystic duct (right).

Slide 21.

Hepatic veins drain blood from the liver to the inferior vena cava. There are usually three major hepatic veins: right, middle, and left. The right hepatic vein is found within the right functional lobe. The middle hepatic vein is found between the right and left functional lobes. The left hepatic vein is found within the left functional lobe.

22

Portal Venous System



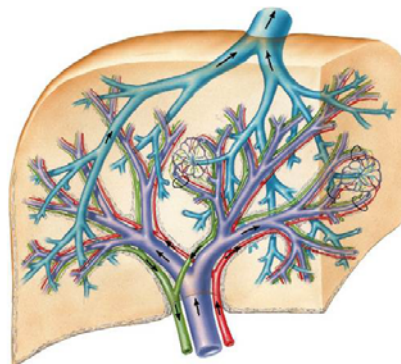
Slide 22.

Blood drains from the portal system into the liver before returning to the inferior vena cava. The liver acts as a sort of filter, detoxifying the blood on its way back from organs of the GI tract.

23

Summary of Fluid Flow

- Proper hepatic artery
- Common hepatic duct
- Hepatic portal vein
- Hepatic vein



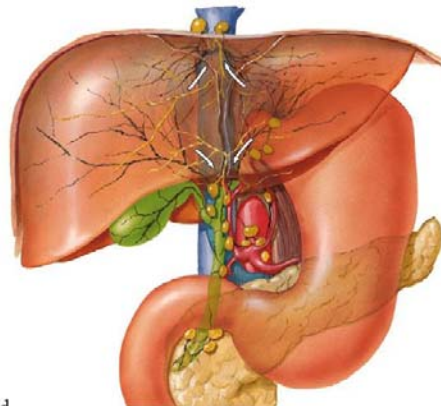
Slide 23.

This illustration demonstrates the direction of the flow of major fluids in relation to the liver. The proper hepatic artery supplies the liver with blood. Bile exits the liver via the common hepatic duct. Blood drains into the liver from the hepatic portal vein. Blood from the liver drains into the hepatic veins and, eventually, the inferior vena cava.

24

Lymphatic Drainage

- Follows blood supply to hepatic nodes in porta hepatis, then to celiac nodes
- Other drainage through diaphragm to posterior mediastinal nodes.



Slide 24.

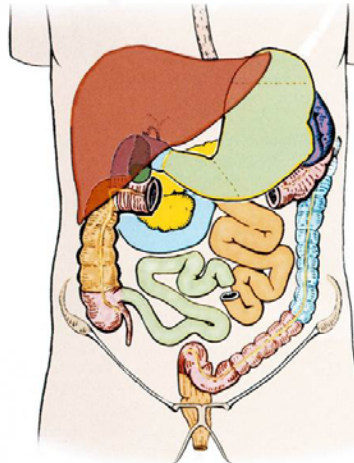
The liver and gallbladder share lymphatic drainage to the hepatic, celiac, and posterior mediastinal nodes.

25

Pancreas

- Is found on the posterior abdominal wall
- Is mostly retroperitoneal

Grant's Dissector 4.23



Slide 25.

The pancreas is an organ located in the posterior abdominal wall. It is mostly retroperitoneal.

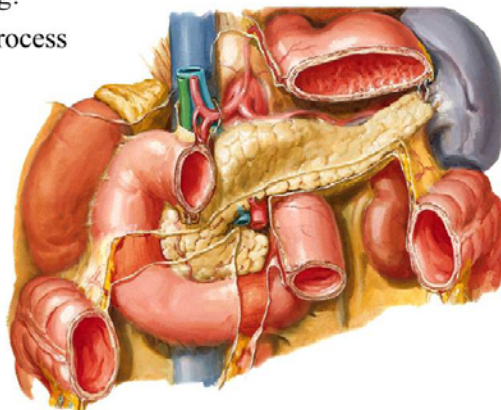
26

Pancreas

Note the following:

- The uncinete process
- The head
- The neck
- The body
- The tail.

Netter 281



Slide 26.

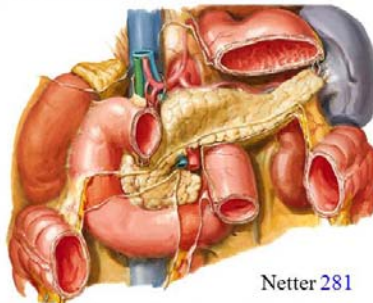
The pancreas has five parts: the uncinete process, head, neck, body, and tail. The tail is the only part of the pancreas that is not retroperitoneal.

27

Pancreas Relationships

- From the duodenum to the spleen
- Is across midline at L₁-L₂ vertebrae
- Found in "bed" of stomach (posterior wall of the omental bursa)
- Is mostly retroperitoneal (except the tail, found in the lienorenal ligament)

Netter 281



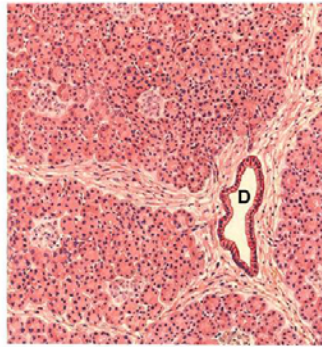
Slide 27.

The pancreas runs between the duodenum and the spleen. The pancreas is found at L₁ and L₂ vertebral levels. The stomach lies anteriorly to the pancreas. The superior mesenteric artery and vein are located anteriorly to the uncinete process and posterior to the neck of the pancreas.

Note how the superior mesenteric vessels are anterior to the uncinete process but posterior to the neck.

Pancreas: 2 Glands in 1

- Exocrine gland: empties into duct system, digestive enzymes (trypsin, chymotrypsin) and then in the duodenum
- Endocrine gland: insulin and glucagon from the Islets of Langerhans, empties into the circulatory system.



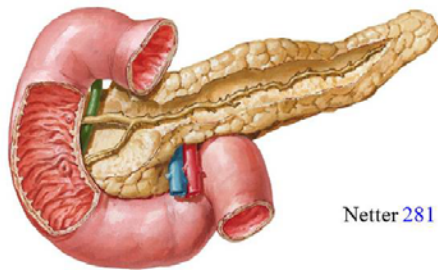
Netter 298 4th ed.

Slide 28.

The pancreas is a glandular organ that functions as both an exocrine and an endocrine gland. Exocrine glands empty their products into ducts, whereas endocrine glands empty their products into the bloodstream. In brief, the exocrine pancreas secretes digestive enzymes. The endocrine pancreas (Islets of Langerhans) secretes insulin and glucagon. These hormones are integral to the homeostatic regulation of blood sugar levels.

Pancreatic Ducts

- Major pancreatic duct to the greater duodenal papilla
- Minor pancreatic duct to the lesser duodenal papilla



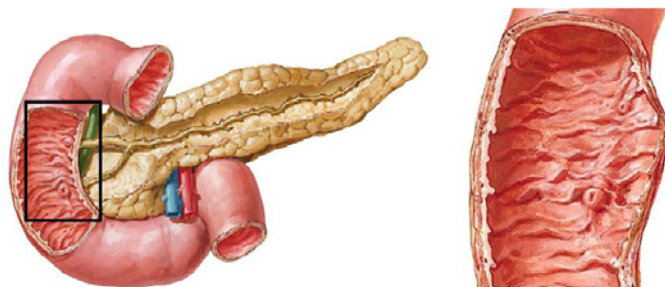Netter 281

Slide 29.

The digestive enzymes produced by the exocrine pancreas are dumped into the duodenum via pancreatic ducts. The ends of these ducts can be seen within the duodenum as greater and lesser duodenal papillae.

Papillae

- Lesser duodenal papilla
- Greater duodenal papilla



Netter 281

Netter 280

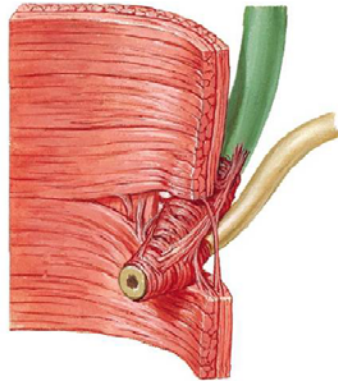
Slide 30.

Note the lesser and greater duodenal papillae formed where the minor and major pancreatic ducts empty the products of the exocrine pancreas into the duodenum.

Sphincters

Note the following:

- The bile duct sphincter
- The pancreatic duct sphincter
- The sphincter of the hepatopancreatic ampulla (Sphincter of Oddi).



Netter 280

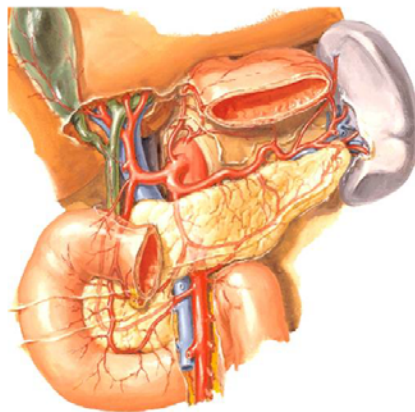
Slide 31.

In this view, the common bile duct and major pancreatic duct come together to empty their contents into the duodenum (greater duodenal papilla). At the point where the two ducts become one, the structure is called the hepatopancreatic ampulla. The release of bile and digestive enzymes from these ducts is regulated by the smooth muscle sphincters: the bile duct sphincter, the pancreatic duct sphincter, and the sphincter of the hepatopancreatic ampulla (Sphincter of Oddi).

Arterial Supply of the Pancreas

Is from 2 sources:

- The celiac artery
- The superior mesenteric artery.



Netter 284

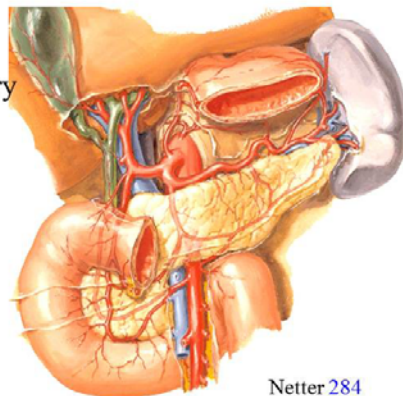
Slide 32.

The blood supply to the pancreas stems from two major arteries: the celiac artery and the superior mesenteric artery.

Arterial Supply of the Pancreas

Note the following:

- The splenic artery
- The gastroduodenal artery
- The superior pancreaticoduodenal artery
- The dorsal pancreatic artery
- The inferior pancreaticoduodenal artery.



Netter 284

Slide 33.

The celiac artery gives rise to the splenic artery, whose characteristically tortuous path renders it easy to identify. The splenic artery runs from right to left along the superior border of the pancreas. The gastroduodenal artery is a branch from the common hepatic artery. The gastroduodenal artery runs posteriorly to the duodenum and gives rise to the superior pancreaticoduodenal artery. The dorsal pancreatic artery is a branch of the splenic artery. The superior mesenteric artery gives rise to the inferior pancreaticoduodenal artery. Please note that there are a number of anastomoses involving the arteries supplying the pancreas.

34

Arterial Supply Summary

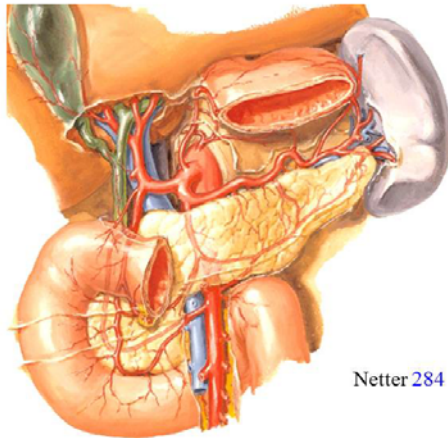
1. Celiac A to splenic A to dorsal pancreatic A
2. Celiac A to common hepatic A to superior pancreaticoduodenal A
3. Superior mesenteric A to inferior pancreaticoduodenal A

Slide 34.

This is a summary slide of the different paths of pancreatic blood supply that we just reviewed.

35

Arterial Supply Summary

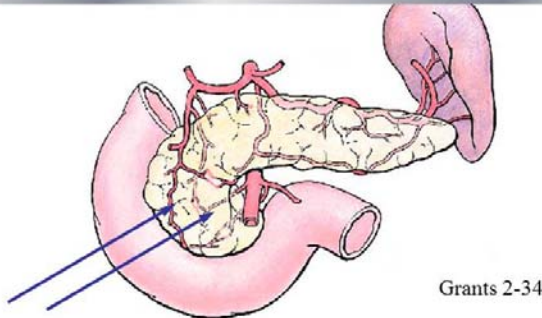


Slide 35.

Use this slide to review the path of blood from the celiac artery (or trunk) to the dorsal pancreatic artery.

36

Pancreaticoduodenal Arcades



Slide 36.

Note how the anterior and posterior branches of the superior and inferior pancreaticoduodenal arteries anastomose to form the anterior and posterior pancreaticoduodenal arcades.

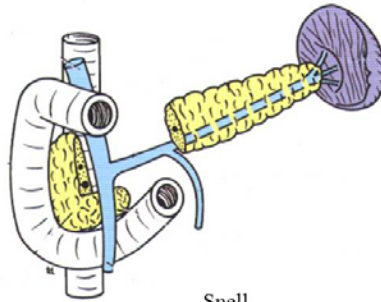
The anterior and posterior branches of the superior and inferior pancreaticoduodenal arteries anastomose to form the anterior and posterior pancreaticoduodenal arcades.

37

Venous Drainage of Pancreas

Is by the:

- Portal vein
- Superior mesenteric vein
- Splenic vein
- Inferior mesenteric vein



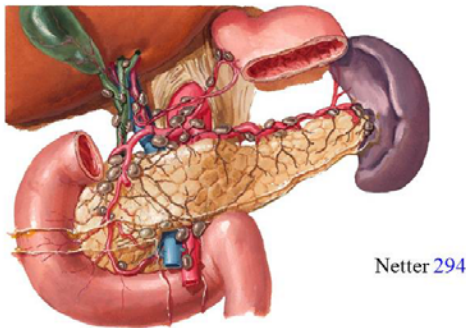
Slide 37.

The portal vein rises posteriorly to the neck of the pancreas. The splenic vein runs posteriorly to the body of the pancreas. The superior mesenteric vein rises anteriorly to the uncinuate process and joins the splenic vein. The splenic and superior mesenteric veins form the portal vein. Inferior mesenteric vein drains into the splenic vein just before the splenic vein joins the superior mesenteric vein.

38

Lymphatic Drainage of Pancreas

- Celiac nodes
- Superior mesenteric nodes.



Slide 38.

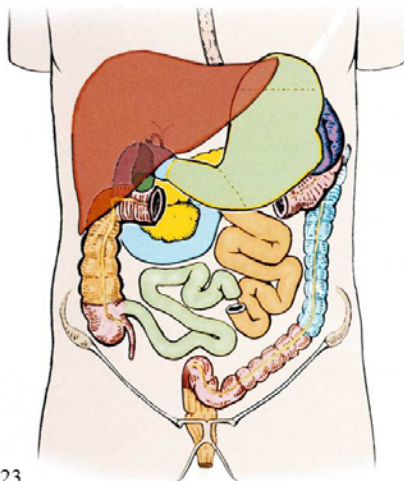
The lymphatic drainage of the pancreas follows the arterial supply to the celiac and superior mesenteric nodes.

39

Spleen

- Is a mobile ovoid lymphatic organ
- Found in the upper left quadrant
- Is intraperitoneal
- Is protected by ribs 9-11
- Located under the diaphragm (by the costodiaphragmatic recess).

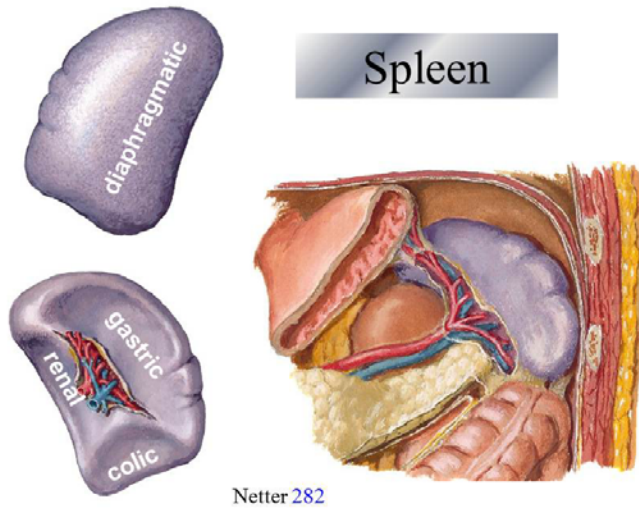
Grant's Dissector 4.23



Slide 39.

The spleen is a mobile, ovoid organ situated in the upper left quadrant of the abdominal cavity. This intraperitoneal organ is found adjacent to the costodiaphragmatic recess, and it is protected by ribs 9-11.

40



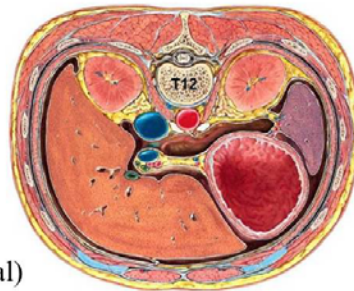
Slide 40.

The diaphragmatic surface of the spleen is convex. The visceral surface of the spleen is concave with impressions of different visceral organs evident (similarly to liver). Note the impressions made by the stomach (gastric), left kidney (renal), and colon (colic). The superior/anterior border of the spleen is notched in appearance.

41

Spleen

- Intraperitoneal except at the hilum
- Peritoneal ligaments: the splenorenal (lienorenal) with tail of pancreas and the gastrosplenic (gastrolienal)
- Ligaments of spleen limit the extent of omental bursa.



Slide 41.

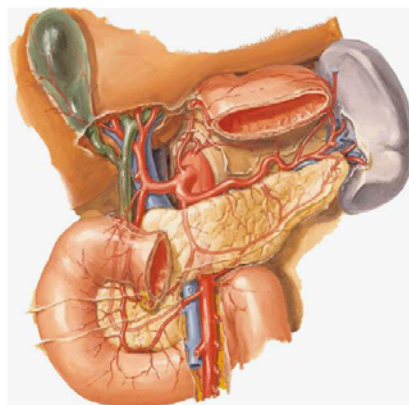
This transverse section through the abdomen shows the position of the spleen relative to some other viscera. The spleen is intraperitoneal, i.e. covered in peritoneum, except at the hilum. The spleen is suspended by two peritoneal ligaments. The splenorenal (lienorenal) ligament crosses from the spleen to the left kidney. The tail of the pancreas is also involved in this ligament. The gastrosplenic ligament travels from the posterior surface of the stomach to the spleen.

42

Blood Supply of the Spleen

The splenic artery and vein are with the tail of pancreas in the splenorenal ligament (dissected here in this view).

Netter 284

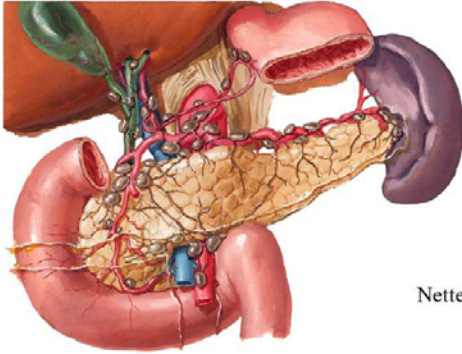


Slide 42.

The splenic artery supplies blood to the spleen.

Lymphatic Drainage of the Spleen

- Celiac nodes
- Superior mesenteric nodes



Netter 294

The End.

Slide 43.

The lymphatic drainage of the spleen follows the arterial supply to the celiac and superior mesenteric nodes.

Note that the pancreas and spleen have identical patterns of lymphatic drainage.

Slide 44.

The end.

The Diaphragm, Posterior Abdominal Wall, Lumbar Plexus and Autonomic Nervous System of the Abdomen.

By Thierry Bacro, Ph.D

Department of Regenerative Medicine and Cell Biology
Center for Anatomical Studies and Education
College of Medicine
Medical University of South Carolina

I. Introduction.

Slide 1:

In this lecture, we will start by reviewing the anatomical structures related to the diaphragm and the posterior abdominal wall. We will continue by studying the features of the lumbar plexus, the blood vessels of the posterior wall and we will end by studying the kidneys and suprarenal glands.

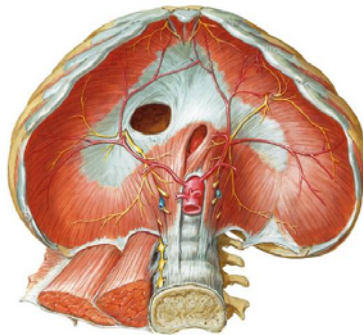
II. The diaphragm.

2

Diaphragm

- Muscle of inspiration
- Dome-shaped muscle
- Central tendinous part
- Peripheral muscular part
- Muscular part has 3 origins:
 - Sternal: 2 bands
 - Costal: 6 lowest ribs
 - Vertebral: 2 crura.

Netter 189



Slide 2.

The diaphragm is the primary muscle of respiration. It is a large dome-shaped muscle, closing the aperture found between the thorax and the abdomen. It consists of a central tendinous part and a peripheral muscular part. The muscular origins of the diaphragm are:

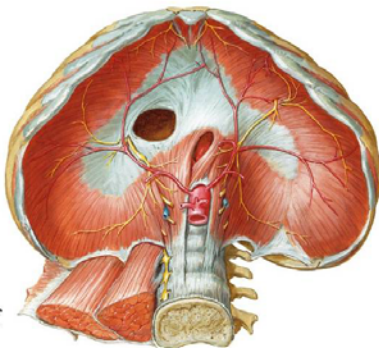
- The sternal origin, formed by two small muscular bands arising from the posterior aspect of the xiphoid process
- The costal origin, formed by muscular bands arising from the most internal aspect of the lower six ribs and matching costal cartilages
- The vertebral part, formed by 2 vertical columns or crura.

3

Associated Structures

- Right crus: from 1st 3 lumbar
- Left crus: from the 1st 2 lumbar
- Median arcuate ligament
- Medial arcuate ligament: from the body of the 2nd lumbar vertebra to tip of TP of the 1st lumbar vertebra
- Lateral arcuate ligament: from the tip of TP of the 1st lumbar vertebra to the lower border of the 12th rib

Netter 189



Slide 3.

On this Netter plate, note how the vertebral origin of the diaphragm consists of a right crus and a left crus. The right crus arises from the antero-lateral aspect of the bodies of the first 3 lumbar vertebrae and corresponding discs whereas the left crus is from the antero-lateral aspect of the bodies of the first 2 lumbar vertebrae (and corresponding discs). Note that a

ligament, the median arcuate ligament, connects the medial borders of the 2 crura, crossing over the anterior surface of the aorta. Other structures associated with the 2 crura are the:

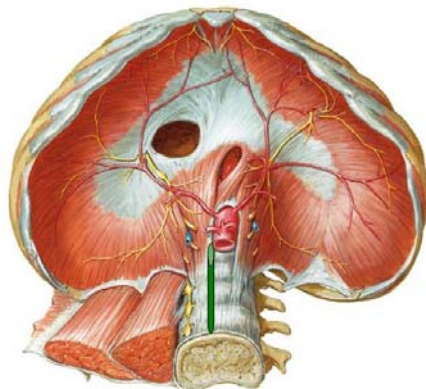
- The medial arcuate ligament, a thickening of the upper margin of the fascia covering the psoas muscle. This medial ligament extends from the side of the vertebral body of the 2nd lumbar to the tip of the transverse process of the 1st lumbar vertebra
- The lateral arcuate ligament, a thickening of the upper margin of the fascia covering the anterior surface of the quadratus lumborum muscle. The lateral ligament extends from the tip of the transverse process 1st lumbar vertebra to the lower border of the 12th rib.

4

Openings

- Caval opening at T₈: inferior vena cava and the terminal branches of the right phrenic nerve
- Esophageal opening at T₁₀: esophagus, the ant and post vagus nerves and the esophageal branches of the left gastric vessels
- Aortic opening at T₁₂: aorta and the thoracic duct.

Netter 189



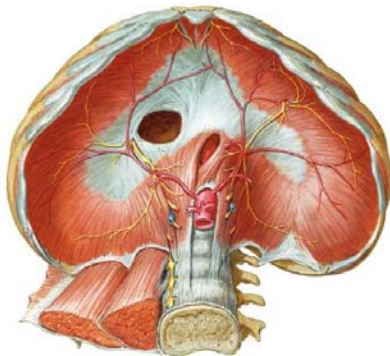
Slide 4.

The diaphragm presents 3 main openings for the passage of 3 important anatomical structures:

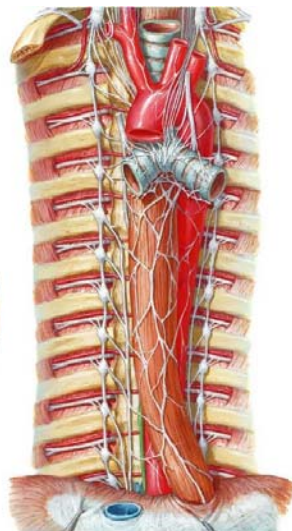- The caval opening, at the level of the 8th thoracic vertebra and in the central tendon, transmitting the inferior vena cava and the terminal branches of the right phrenic
- The esophageal opening, found anterior to the 10th thoracic vertebra, transmits the esophagus, the ant and post vagus nerves and the esophageal branches of the left gastric vessels. Note that the edges of this opening are formed by the sling of muscle fibers derived from the right crus
- The aortic opening, found immediately anterior to the 12th thoracic vertebra allows the passage of the aorta and the thoracic duct.

5

Posterior Structures



Netter 189 and 203



Slide 5.

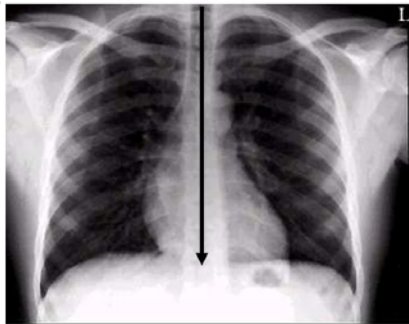
On the Netter plates, observe the other structures passing downward at this level:

- The greater, lesser and least splanchnic nerves piercing the crura on both sides
- The sympathetic trunks passing posterior to the medial arcuate ligament on both sides
- The left phrenic nerve piercing the left dome of the diaphragm.

Function

- Primary m. of respiration
- Increase vertical diameter
- Increase abdominal pressure and help in
 - In urination, defecation and parturition
 - In supporting the vertebral column during heavy lifting
 - In the thoracoabdominal pump.

[Image captured from Internet](#)



Slide 6.

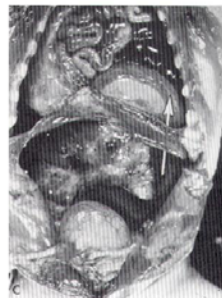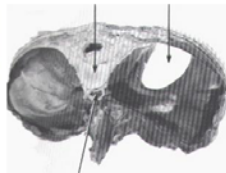
In terms of action, the diaphragm is the primary muscle of inspiration. During contraction, the diaphragm pulls down the central tendon using its muscular origins, increasing the vertical diameter of the thorax cavity (image captured from the internet). Recall that the left dome (lower border of the fifth rib) is slightly lower than the right dome (upper border of the fifth rib). Note that the diaphragm also plays a role in increasing the intra-abdominal pressure:

- In urination, defecation and parturition
- In supporting the vertebral column during heavy lifting
- In the thoracoabdominal pump, facilitating the movement of lymph upward in the thoracic duct.

Diaphragmatic Herniae

- 1 out of 2000 newborns have a defect in the diaphragm
- Due to the lack of fusion of the embryological origins of the diaphragm (septum transversum, dorsal mesentery and pleuroperitoneal membranes of body wall)
- Allows the passage of abdominal contents in the thorax cavity
- Bochdalek's hernia (foramen).

Moore Fig 9-10 and 9-11 page 167-168



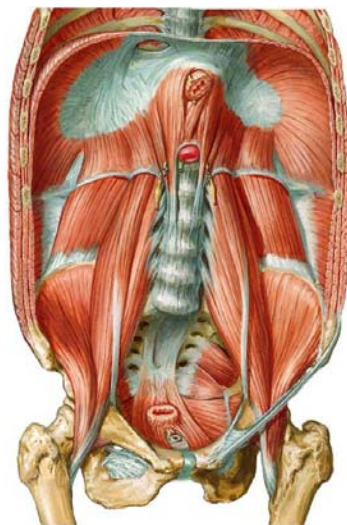
Slide 7.

Due to the fact that the diaphragm is the product of the fusion of 3 separate embryological entities (septum transversum, dorsal mesentery and pleuroperitoneal membranes of body wall), it can occasionally be the site of a congenital malformation called congenital diaphragmatic hernia. In 1 out of 2000 newborns, a defect in the diaphragm, due to the lack of fusion of the embryological origins of the diaphragm, allows the passage of abdominal contents in the thorax cavity (Bochdalek's hernia) (Moore Fig 9-10 and 9-11 page 167-168).

Posterior Wall

- Five lumbar vertebrae and associated intervertebral discs in the midline
- Laterally and superiorly by the 12th rib
- Inferiorly by the upper part of the bony pelvis
- Posteriorly a set of muscles: psoas, iliacus, quadratus lumborum muscles.

Netter 256



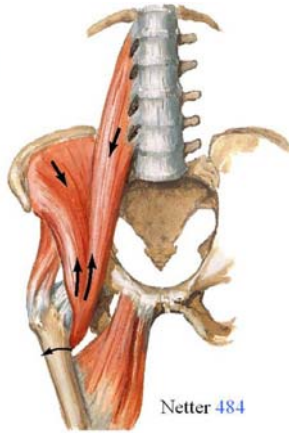
Slide 8.

Several structures of the posterior wall were already mentioned while studying the diaphragm muscle. The posterior abdominal wall is formed by the five lumbar vertebrae and associated intervertebral discs in the midline, laterally and superiorly by the 12th rib, inferiorly by the upper part of the bony pelvis (coxal bone), and posteriorly a set of muscles. These muscles are the psoas major, the iliacus and the quadratus lumborum. Often, a fourth muscle, the psoas minor can be found.

9

Psoas Major

- Origin: from the 12th to the 5th lumbar vertebrae (TP, bodies and IVD)
- Insertion: on the lesser trochanter of the femur (with iliacus muscle)
- Action: flexes the thigh at the hip (on the trunk). Can flex the trunk over the thigh (at the hip) when fixed distally
- Innervation: by a branch of the lumbar plexus.



Slide 9.

The psoas major muscle originates from the 12th to the 5th lumbar vertebrae (transverse processes, sides of the vertebral bodies and corresponding intervertebral discs) and inserts by a common tendon with the iliacus muscle (see next slide) on the lesser trochanter of the femur. Its muscle fibers leave the abdomen by passing downward and posterior to the inguinal ligament. The psoas is covered by a fibrous sheath, the psoas fascia, which thickens superiorly to form the medial arcuate

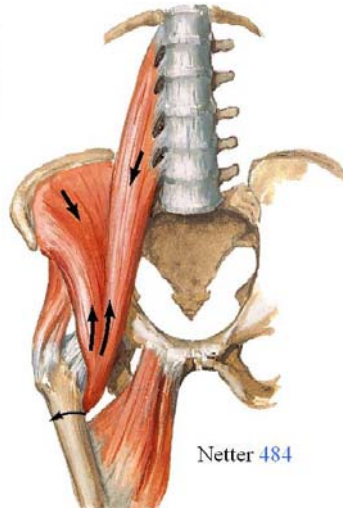
ligament. The psoas muscle is innervated by a branch of the lumbar plexus (see later in this lecture).

Its action is to flex the thigh at the hip (on the trunk). It can flex the trunk over the thigh (at the hip), if the lower extremity is fixed distally (when performing sit-ups). Note that in about 40% of patients, a fourth muscle, the psoas minor muscle, can be found anterior to the psoas major. It is not functionally important but can be observed in the cadaver lab.

10

Iliacus

- Origin: iliac fossa
- Insertion: on the lesser trochanter of the femur (with psoas muscle)
- Action: flexes the thigh at the hip (on the trunk). Can flex the trunk over the thigh (at the hip) when fixed distally
- Innervation: by the femoral nerve (from lumbar plexus).



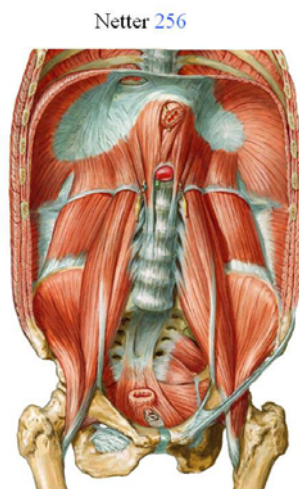
Slide 10.

Found lateral to the psoas muscle, the iliacus muscle originates from the iliac fossa of the pelvic bone to insert by a tendon common with the psoas major muscle on the lesser trochanter. The iliacus, which is also covered by a fibrous sheath, the iliacus fascia, is innervated by the femoral nerve (lumbar plexus: see later in this lecture). Its action is similar to the psoas major.

11

Quadratus Lumborum

- Origin: iliolumbar ligament, iliac crest and tip of the transverse process of the 5th lumbar vertebra
- Insertion: lower border of the 12th rib, tip of the transverse processes of the upper 4 lumbar vertebrae
- Action: flexes laterally the trunk and fixes/depresses the lowest rib during forced expiration
- Innervation: by a branch of the lumbar plexus.



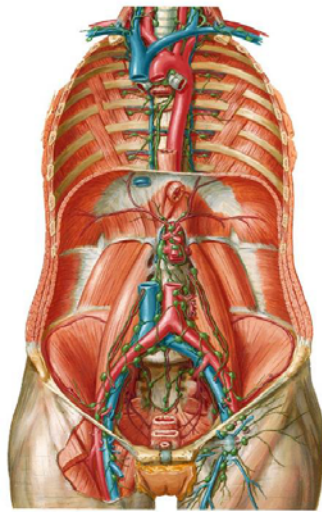
Slide 11.

The quadratus lumborum muscle is a flat, quadrangular shaped muscle originating inferiorly from the iliolumbar ligament, the iliac crest and the tip of the transverse process of the 5th lumbar vertebra. Superiorly, it inserts in the lower border of the 12th rib and the tip of the transverse processes of the upper 4 lumbar vertebrae. The quadratus fascia, covering the internal aspect of this muscle, thickens superiorly to form the lateral arcuate ligament. With a nerve supply by a branch of the lumbar plexus, this muscle flexes laterally the trunk and fixes/depresses the lowest rib during forced expiration.

Posterior Wall

- Aorta and its branches
- Vena cava and associated structures
- Lymphatic system, including the cisterna chyli
- Lumbar plexus.

Netter 259



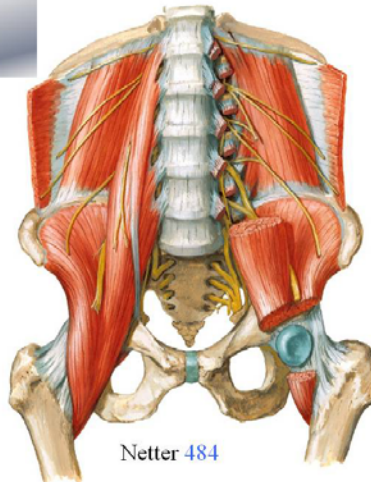
Slide 12.

Several important anatomical structures can be found anterior to the muscular posterior wall: the aorta and its branches, the inferior vena cava and associated structures, and the lymphatic system, including the cisterna chyli. Note that an important plexus supplying the lower limb, the lumbar plexus forms within the posterior abdominal wall, specifically the psoas muscle.

Lumbar Plexus

- Formed by anterior rami of the upper 4 lumbar nerves
- Forms within the psoas major
- Possible connection from anterior ramus of 12th thoracic in some cases
- Anterior ramus of the 4th lumbar nerve emerges medial to psoas to form the lumbosacral trunk (with the 5th lumbar nerve).

Netter 484



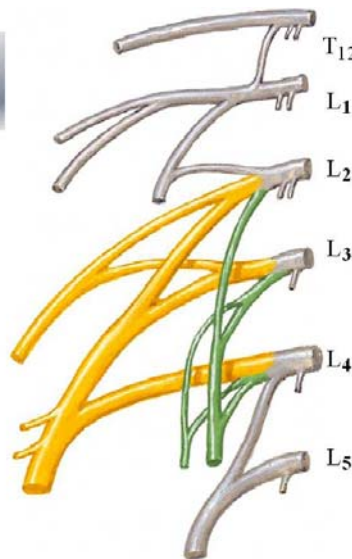
Slide 13.

The lumbar plexus is formed in the psoas muscle from the anterior rami of the upper 4 lumbar nerves. The branches from the plexus emerge from the lateral and medial borders of this muscle as well as from its anterior surface. The anterior ramus of the 12th thoracic nerve also contributes to the lumbar plexus in most instances. Part of the anterior ramus of the 4th lumbar nerve emerges from the medial border of the psoas and joins with the 5th lumbar nerve to form the lumbosacral trunk. This trunk then passes inferiorly to contribute to the sacral plexus (see later).

Lumbar Plexus

- (Subcostal nerve T₁₂)
- Iliohypogastric nerve (L₁)
- Ilioinguinal nerve (L₁)
- Genitofemoral nerve (L₁₋₂)
- Lateral femoral cutaneous nerve of the thigh (L₂₋₃)
- Femoral nerve (L₂₋₄)
- Obturator nerve (L₂₋₄) and accessory obturator nerve (when present).

Netter 486



Slide 14.

On this Netter plate, we can observe the following nerves emerging from the lumbar plexus (from top to bottom in this order):

- (Subcostal nerve T₁₂)
- Iliohypogastric nerve (L₁)
- Ilioinguinal nerve (L₁)
- Genitofemoral nerve (L₁₋₂)
- Lateral femoral cutaneous nerve of the thigh (L₂₋₃)
- Femoral nerve (L₂₋₄)
- Obturator nerve (L₂₋₄)

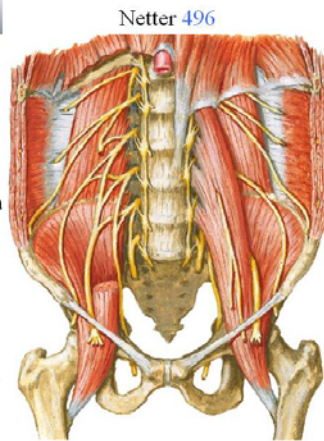
Lumbar Plexus

- Subcostal, iliohypogastric and ilioinguinal nerves enter the abdominal wall
- Genitofemoral nerve emerges and divides into a femoral branch and a genital branch on the anterior surface of the psoas muscle
- Lateral femoral cutaneous nerve passes anteriorly to the iliacus muscle, enters the thigh behind the lateral end of the inguinal ligament
- Femoral nerve
- Obturator nerve.

Note the Sympathetic trunks.

- The femoral nerve, the largest branch of the lumbar plexus, passes laterally and downward between the psoas and the iliacus muscles. It finally passes under the inguinal ligament and stays lateral to the femoral vessels. Note it supplies the iliacus muscle in the abdomen
- The obturator nerve and the portion of the 4th lumbar nerve contributing to the lumbosacral trunk are the only ones merging medial to the psoas muscle. The obturator nerve crosses the pelvic brim in the front of the sacroiliac joint. It leaves the pelvic region by passing through the obturator foramen (see lower limb unit).

Note also the presence of the sympathetic trunks on the posterior wall. The right sympathetic trunk is positioned under the inferior vena cava whereas the left sympathetic trunk is found on the left border of the aorta.



Netter 496

Slide 15.

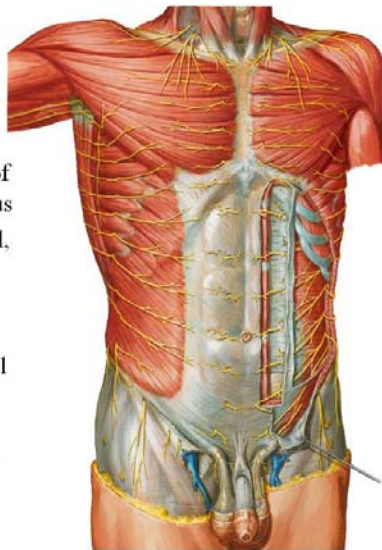
On the anterior aspect of the posterior wall, note the following:

- The subcostal, iliohypogastric and ilioinguinal nerves enter the abdominal wall
- The genitofemoral nerve emerges and divides into a femoral branch and a genital branch on the anterior surface of the psoas muscle
- The lateral femoral cutaneous nerve passes anteriorly to the iliacus muscle and enters the thigh behind the lateral end of the inguinal ligament

Lumbar Plexus

- Subcostal above the lateral iliac crest and on the anterior aspect of the abdomen, below the umbilicus
- Iliohypogastric to the lateral wall, immediately above the lateral portion of the iliac crest and anteriorly
- Genitofemoral below the inguinal ligament and to a scrotal branch
- Lateral cutaneous nerve of the thigh, to the lateral border of the thigh.

Netter 251



Slide 16.

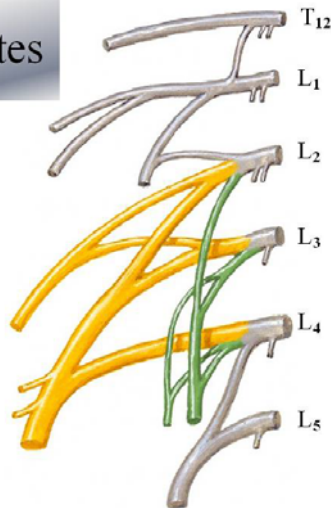
On this anterior view of the abdominal wall, observe:

- The subcostal nerve, above the lateral iliac crest, supplying cutaneous innervation on the anterior aspect of the abdomen, below the umbilicus
- The iliohypogastric nerve supplying cutaneous innervation to the lateral wall, immediately above the lateral portion of the iliac crest and anteriorly, below of the area innervated by the subcostal nerve
- The genitofemoral nerve supplying cutaneous innervation to the skin of the thigh immediately below the inguinal ligament. Note also the genital branch passing through the spermatic cord to supply the cremasteric muscle (involved in the cremasteric reflex)
- The lateral cutaneous nerve of the thigh, supplying cutaneous innervation to the lateral border of the thigh.

Rami Communicantes

Note also that only T₁₂ to L₂ send white rami communicantes to the sympathetic trunk with gray rami communicantes from the sympathetic trunk leaving from T₁₂ to L₅.

Netter 486



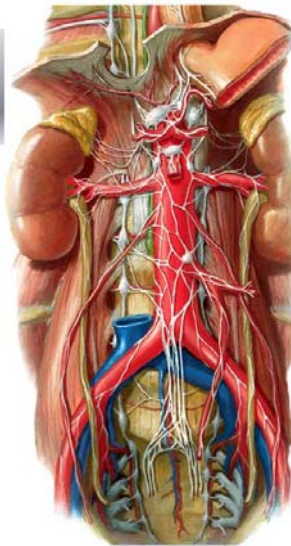
Slide 17.

Note also that only T₁₂ to L₂ send white rami communicantes to the sympathetic trunk with gray rami communicantes from the sympathetic trunk leaving from T₁₂ to L₅.

Autonomic System in Abdomen

In general, organs of the body receive fibers from both the sympathetic and parasympathetic systems. It is thought that the balance of the activity of the two systems regulates the organ.

Netter 297



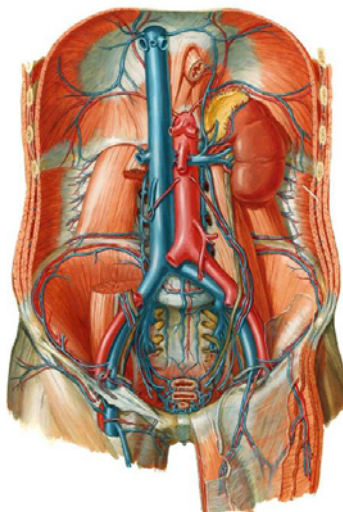
Slide 18.

Some organs of the body receive fibers from both the sympathetic and parasympathetic systems while some are believed to receive only one. It is thought that when both systems are present, the balance of the activity of the two systems regulates the organ. If only one system is present, the level of activity of the system regulates the organ.

Blood Vessels

- Aorta and its branches
- Vena cava and associated structures

Netter 258

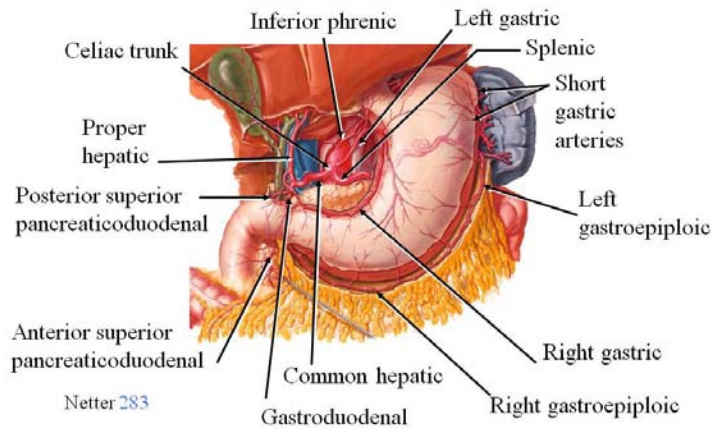


Slide 19.

This Netter plate shows the aorta and its branches as well as the vena cava and associated structures. Observe the 3 main unpaired branches of the aorta, the celiac trunk, the superior mesenteric artery and the inferior mesenteric artery. These 3 main arteries and their main branches will be reviewed in the next few slides.

20

Arteries of Stomach, Liver, Duodenum, Pancreas and Spleen

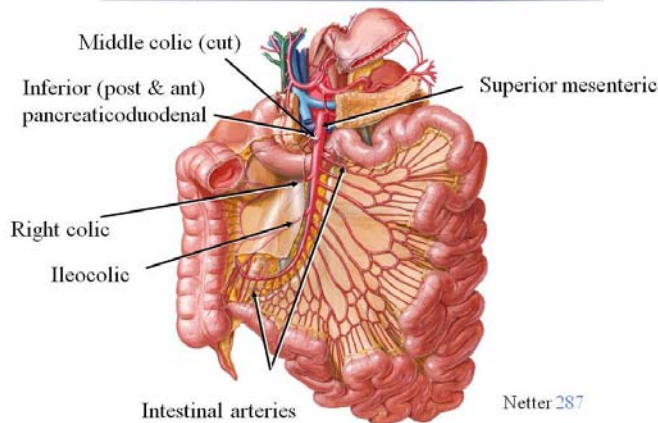


Slide 20.

This Netter plate shows the main primary and secondary branches of the celiac trunk. Recall how these arteries provide the blood supply to the stomach, liver, duodenum (proximal portion), pancreas and spleen. Note that in terms of embryology, this blood supply develops from the foregut.

21

Superior Mesenteric Artery

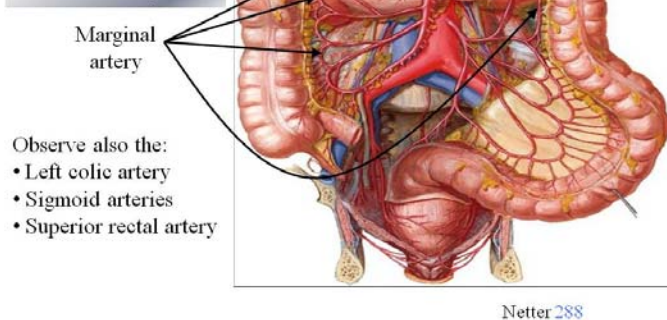


Slide 21.

This Netter plate shows the main primary and secondary branches of the superior mesenteric artery. Recall how these arteries provide the blood supply to the distal portion of the duodenum, jejunum, ileum, cecum, ascending colon and the right 2/3 of the transverse colon. Note that in terms of embryology, this blood supply develops from the midgut.

22

Inferior Mesenteric Artery



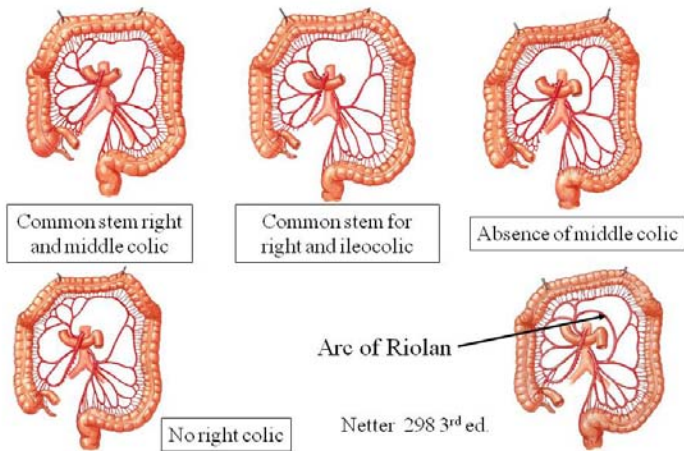
Slide 22.

On this Netter plate, observe the main branches of the inferior mesenteric artery, the left colic artery, the sigmoid arteries and the superior rectal artery. Understand that in terms of embryology, this blood supply develops from the hindgut.

Note how the branches of the superior mesenteric artery anastomose with branches of the inferior mesenteric artery through the marginal artery as well as the Arc of Riolan (See next slide).

23

Variation in Colic Arteries



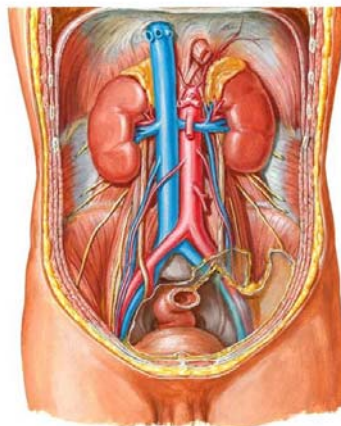
Slide 23.

This Netter slide shows us some of the main variations of the colic arteries. Refer to this diagram during your dissection. Observe also in the bottom right drawing the Arc of Riolan described in the previous slide.

24

Kidneys on Posterior Wall

- Kidneys
 - T₁₂-L₃ vertebral levels
 - diaphragm
 - 11th and 12th ribs
- Suprarenal glands
- Ureters.



Netter 308

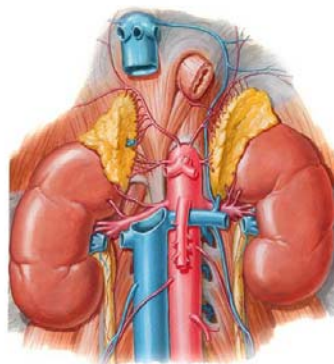
Slide 24.

The right kidney is located lateral to the T₁₂ - L₃ vertebral bodies and anterior to the 12th rib. It is anterior to the psoas, quadratus lumborum, and transversus abdominis muscles. The left kidney has the same relationships but is higher and in contact with the 11th rib. The subcostal nerves (T₁₂) pass posterior and lateral to the kidneys and the iliohypogastric and ilioinguinal nerves (L₁) pass more inferiorly. The suprarenal glands are anterior to the posterior extent of the diaphragm. The ureters pass anterior to the psoas muscles, as far as the pelvic brim, on their course to the bladder in the pelvis.

25

Kidney Functions

- Paired, retroperitoneal organs
- Located bilaterally
- Functions:
 - metabolic waste excretion
 - production of urine
 - water and electrolyte balance
 - acid-base balance of blood
 - blood pressure.



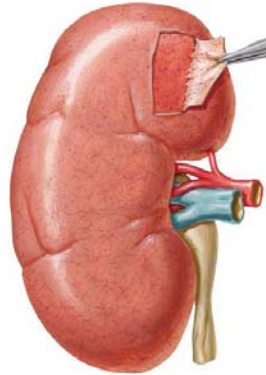
Netter 310

Slide 25.

The kidneys are paired retroperitoneal organs on each side of the vertebral column, at about the T₁₂ - L₃ vertebral levels. The functions of the kidneys include: excretion of waste products of metabolism; production of urine, containing waste products; a role in water and electrolyte balance in the body; helping to maintain the acid-base balance of blood; and contributing to the regulation of blood pressure. Total loss of kidney function is fatal; patients with renal failure require dialysis, a process which substitutes for the functions of the kidney.

Gross Structure of Kidney

- Smooth, oval or bean shaped
- Connective tissue capsule
- Vessels, nerves, ureter enter hilum on medial aspect
- At hilum:
 - Renal vein anterior to renal artery
 - Renal artery anterior to renal pelvis (ureter).



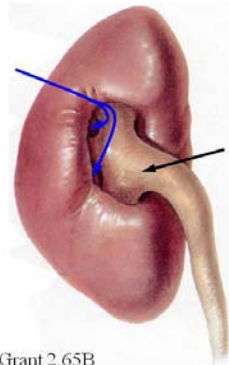
Netter 311

Slide 26.

The kidneys are smooth, oval or “bean-shaped” organs, with a rounded lateral margin and a hilum on the medial side receiving a renal vein, a renal artery, and a ureter. The kidney is covered by a tough fibrous connective tissue capsule. At the hilum, the entering structures are arranged with the renal vein most anterior, the ureter most posterior and the renal artery between.

Renal Sinus

- From medial aspect: the open space in the hilum is the renal sinus
- Renal pelvis: expansion of ureter within renal sinus
- Fat, vessels, and nerves in renal sinus surround renal pelvis
- Renal pelvis receives and collects urine from kidney to drain into ureter.



Grant 2.65B

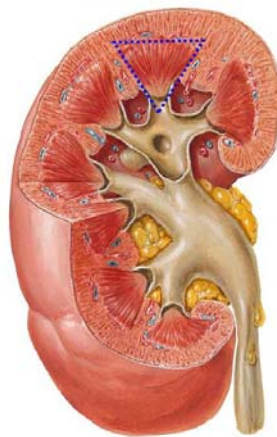Slide 27.

From a medial aspect, the hilum can be seen opening to a space, the renal sinus, in which the ureter expands to form a funnel-shaped renal pelvis, collecting urine from the kidney. Also within the sinus, the renal artery and vein divide to segmental branches, surrounded by fat, lymphatics, and nerves.

Internal Structure of Kidney

- Cortex: outer layer
- Medulla: inner layer
- Medulla: renal pyramids (▽) with renal columns of cortex
- Renal papilla at tip of renal pyramid
- Minor calyx receives urine from renal papilla
- 2-3 minor calyces join to form major calyx
- 2-3 major calyces join to form renal pelvis

Netter 311



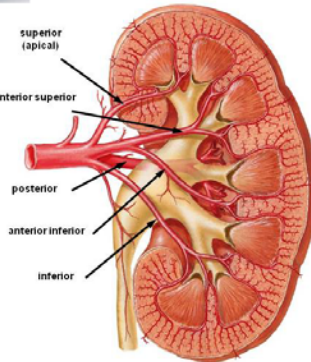
Slide 28.

A frontal section shows the outer cortex and the inner medulla layers. Within the medulla are organized areas called renal pyramids, with a base at the cortex and an apex (papilla) pointing into the renal pelvis. Cortex tissue extends between pyramids to form renal columns. Striations within each pyramid from base to papilla are called medullary rays. Each renal papilla is cupped by a branch of the renal pelvis called a minor calyx. 2 or 3 minor calyces join to form a major calyx. The major calyces join to form the renal pelvis. Within each pyramid are thousands of the functional filtration subunits of the kidney known as nephrons.

Segmental Arteries

Netter 312

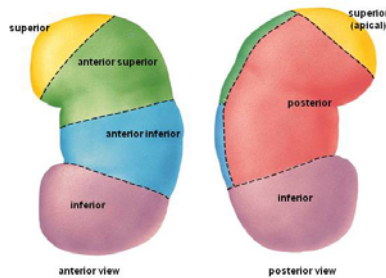
- Renal artery branches at renal sinus to 5 segmental arteries
- Each segmental artery supplies single lobe
- Posterior segmental artery crosses superior to pelvis to reach posterior aspect.



Slide 29.

The renal artery branches to 5 segmental arteries, each supplying a single lobe of the kidney. There are no anastomoses between segmental arteries or their branches, so loss of blood supply in a segmental artery results in a necrotic zone. The renal segments are shown in the diagram on the right. Note the posterior segmental artery crossing superior to the posteriorly placed renal pelvis to reach the posterior renal segment.

Segmental Arteries to Renal Segments



Netter 312

Slide 30.

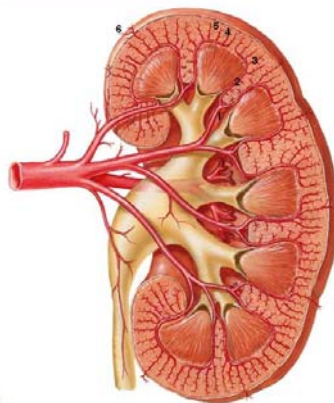
Note on this Netter plate the segments receiving blood supply by the segmental arteries

Renal Arteries Branches

Each renal artery branches to 5 segmental (lobar) arteries with successive branching:

1. Interlobar
2. Arcuate
3. Cortical radiate (interlobular)
4. Afferent arteriole
5. Glomerular capillaries
6. Capsular branches supplying renal capsule

Netter 312

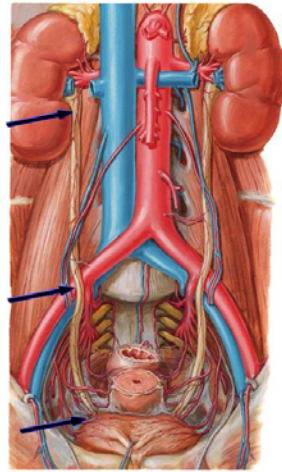


Slide 31.

Each of the segmental arteries sequentially branches to lobar arteries. The lobar arteries provide 2 or 3 interlobar arteries which pass on the sides of the pyramids. At the margin between the cortex and medulla, the interlobar arteries branch to arcuate arteries, coursing over the base of the pyramid, further branching to interlobular arteries, passing into the cortex. Here, they branch into afferent arterioles, which end as glomerular capillaries in the glomerulus. Direct branches from the segmental arteries supply the capsule and the renal pelvis.

Ureters

- 10-inch long tubes
- Renal pelvis to urinary bladder
- Smooth muscle in wall
- Retroperitoneal
- 3 constrictions:
 - Renal pelvis to ureter
 - Ureter crosses pelvic brim
 - Ureter enters wall of bladder



Netter 316

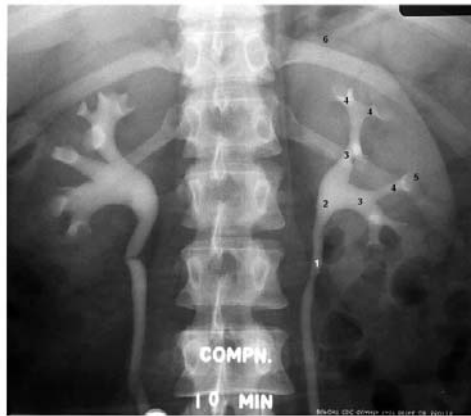Slide 32.

Beginning at the renal pelvis, the ureters are retroperitoneal tubes with walls containing smooth muscle, which convey urine from the kidneys to the bladder. There are usually 3 constrictions along the 10-inch length: at the connection junction of the renal pelvis, as the ureter crosses the pelvic brim, and as the ureter enters the bladder wall. These are significant points at which renal stones may be trapped as they attempt to pass along the ureter.

Intravenous Pyelogram (IVP)

IV-injected radio-opaque dye, after passing through kidney, identifies:

- 1) Ureter
- 2) Renal pelvis
- 3) Major calyces
- 4) Minor calyces
- 5) Renal papilla
- 6) Upper pole of kidney.



Weir & Abrahams 148b

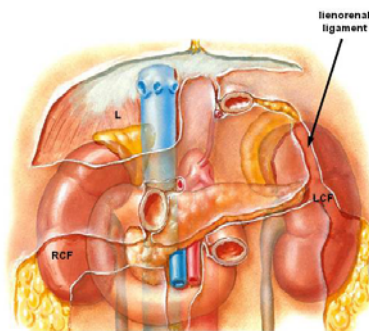
Slide 33.

In an intravenous pyelogram, injected contrast medium filters out through the kidney. Residual dye remains in the kidney circulation, showing a faint outline of the organ (6). Ureters, renal pelvis, and major and minor calyces are marked, as well as a blush of contrast medium still in renal papillae at minor calyces (5). Ureters can have varying diameters due to peristaltic contraction of smooth muscle walls, assisting passage of urine. If blocked by a stone, a ureter lumen dilates above the point of blockage as urine collects there. Contrast medium introduced through a urethral catheter gives a similar view (retrograde urogram).

Anterior Relationships

Kidneys, ureters, suprarenal glands are retroperitoneal, but are in contact with the:

- Bare area of liver
- Right colic flexure
- Duodenum
- IVC
- Left colic flexure
- Descending colon
- Lienorenal ligament.



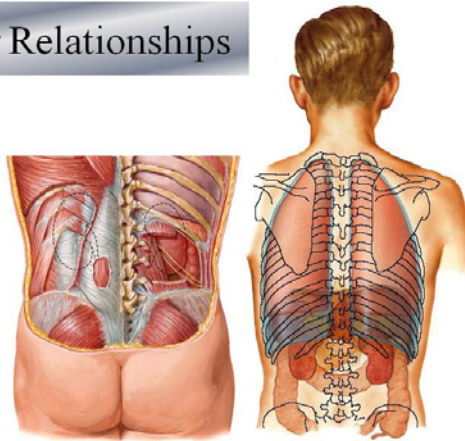
Netter 308

Slide 34.

The right kidney and adrenal are in contact with the bare area of the liver. The inferior lobe of the kidney lies posterior to the right colic flexure, and the hilum and renal pelvis lie just posterior to the retroperitoneal 1st and 2nd parts of the duodenum. The right kidney, ureter, and suprarenal gland are adjacent to the IVC (superior medial end of right adrenal is posterior to IVC). The left kidney, renal pelvis, and adrenal are posterior to the lesser sac and stomach, tail of the pancreas, spleen, and superior loops of jejunum. The splenorenal (lienorenal) ligament passes across the superior lobe of right kidney. The left colic flexure and superior part of descending colon are anterior to right kidney.

Posterior Relationships

- Both kidneys and suprarenal glands under costal margin (ribs 11 & 12)
- Right kidney more inferior
- Move downward during breathing
- Note ureter passes anterior to psoas muscle, anterior to tips of transverse processes.



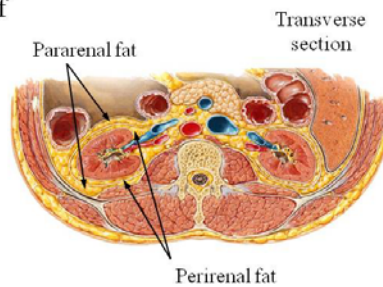
Netter 278 3rd ed., 309

Slide 35.

As already discussed, the kidneys and adrenals are closely applied to the posterior body wall, under the costal margin, adjacent to ribs 11 and 12. The right kidney is slightly inferior, due to the presence of the right lobe of the liver. The absolute position of the kidneys and adrenals changes during breathing, and at deep inspiration the right kidney can be palpated below the costal margin. The ureters (dotted outlines in left figure) descend anterior to the tips of transverse processes of lumbar vertebra and anterior to the psoas muscles.

Renal Support: Renal Fat and Fascia

- Pararenal fat : continuous with retroperitoneal fat of body wall
- Perirenal fat: surrounds kidney and enters renal sinus, also surrounds suprarenal gland and separates it from kidney
- Renal fascia: separates pararenal fat from perirenal fat, encloses suprarenal gland and anchors suprarenal glands to body wall and diaphragm.



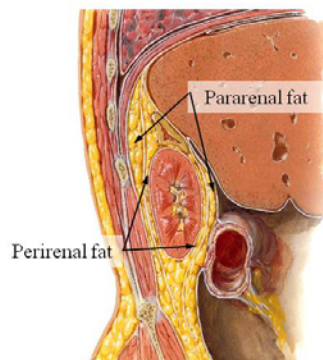
Netter 317

Slide 36.

Perirenal fat surrounds the kidney, fills the renal sinus and surrounds vessels and renal pelvis. Renal fascia separates perirenal fat from the pararenal fat, which is mostly posterior to the kidney and continuous with extraperitoneal fat in the abdominal wall. Perirenal fat can be seen between the kidney and the adrenal.

Renal Support: Renal Fat and Fascia

- Thin fascia between kidney and suprarenal gland
- Collagen fibers from renal fascia extend into both fat layers to stabilize
- Renal vessels also support organs
- No substantial inferior support.



Netter 317

Sagittal section

Slide 37.

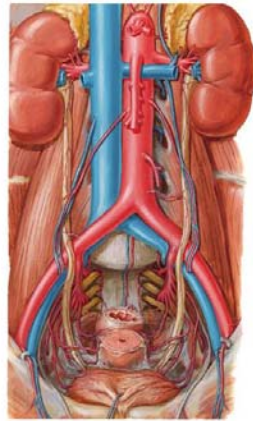
Collagen fibers from renal fascia stabilize and anchor the kidney in the body wall and superiorly to the diaphragm. Except for this thin layer and renal vessels, there is little substantial inferior support for the kidney. Due to poor support in this area, kidneys are usually transplanted to the iliac fossa of the pelvis.

38

Blood Supply of Kidneys

- Renal arteries from aorta (L₁/L₂)
- Right renal artery longer than left
- Right renal artery posterior to IVC
- Renal veins drain into IVC
- Renal veins anterior to arteries
- Left renal Vein longer than right
- Left renal vein crosses aorta
- Superior mesenteric artery crosses left renal Vein
- Left gonadal vein to left renal vein.

Netter 316



Slide 38.

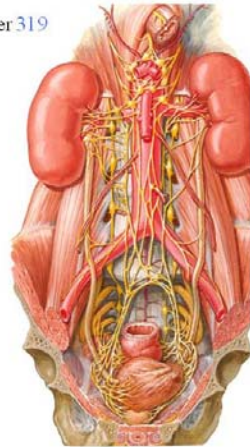
The kidneys are supplied by the left and right renal arteries, branches of the aorta arising between L₁ and L₂ vertebral levels. The right renal artery is longer than the left, crossing posterior to the inferior vena cava. Both left and right renal veins are anterior to the arteries and drain directly to the inferior vena cava. The segmental branches of the renal arteries have already been presented, and branches of renal veins follow these. The longer left renal vein crosses the aorta immediately inferior to the branching of the superior mesenteric artery. The left renal vein receives the left gonadal and left adrenal veins, but the right set of veins drain directly to the inferior vena cava.

39

Nerve Supply of Kidneys and Ureters

Netter 319

- Para-aortic nerve plexuses:
 - Sympathetic trunk and ganglia
 - Vagal trunks
 - Splanchnic nerves
- Pre-aortic plexuses:
 - Celiac
 - SM
 - IM
- Other plexuses:
 - Renal
 - Gonadal
 - Superior hypogastric
- Nerve branches follow arteries.



Slide 39.

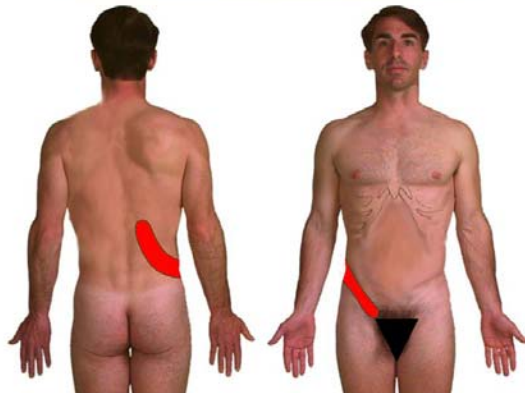Plexuses of nerves and ganglia are formed around the abdominal aorta and its branches by contributions from the abdominal sympathetic trunk, vagal trunks (parasympathetic), and splanchnic nerves. Most of the plexuses are named by the artery they surround: celiac, superior mesenteric, inferior mesenteric, gonadal, hypogastric. The hypogastric plexus receives parasympathetic fibers from the pelvic splanchnic parasympathetic nerves. Nerve branches from the plexuses travel on arterial branches to the various organs. Nerve supply to the kidney is from the renal plexus. Ureters receive nerves from the renal, gonadal, and hypogastric plexuses.

40

Referred Pain for Kidney and Ureter

- Kidney: (posterior)
T₁₀₋₁₂
- Ureter: (lateral to anterior)
L₁₋₂

Grant 2.77



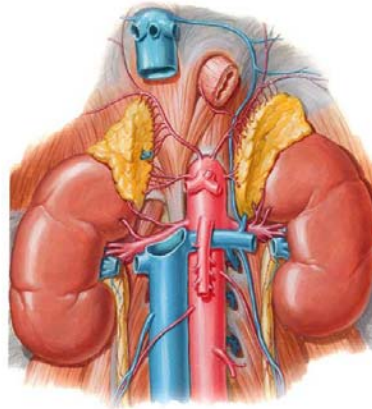
Slide 40.

Visceral afferent fibers from the kidney return to the T₁₀ through T₁₂ spinal cord segments, following the sympathetic supply. Afferent fibers from the ureters return to the L₁ and L₂ spinal cord segments. Pain from the kidneys or ureters is referred to dermatomes supplied by spinal nerves of those segments. Renal or ureteric colic (pain) is described as a “loin to groin” pain pattern as illustrated in the figure on this slide (red area, on back and sweeping around to inguinal region).

41

Suprarenal (Adrenal) Glands

- At upper pole of kidney
- Not attached to kidney
- On left:
 - Crescent shaped
 - On medial aspect
- On right:
 - Pyramid shaped
 - On superior aspect
- Yellow to tan colored
- Retroperitoneal



Netter 310

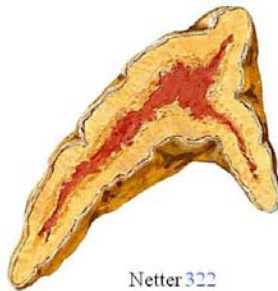Slide 41.

The adrenal or suprarenal glands are endocrine glands, retroperitoneal and positioned but not attached at the upper pole of kidney. They are yellow to tan in color. On the left, the adrenal is crescent shaped and lies along the superior and medial aspect of the kidney. On the right it is roughly pyramidal in shape and is located more directly at the superior pole of the kidney.

42

Suprarenal Gland Structure

- Cortex
 - Embryologically from mesoderm
 - Mineral corticoids
 - Glucocorticoids
 - Androgens
- Medulla
 - Embryologically from neural crest
 - Epinephrine
 - Norepinephrine.



Netter 322

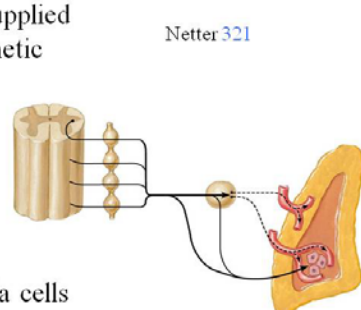
Slide 42.

The adrenal gland has somewhat distinct cortex and medulla regions, derived from different tissues embryologically and having different functions. The cortex (derived from mesoderm) secretes hormones which regulate fluid and electrolyte balance (mineral corticoids), metabolism (glucocorticoids), and development of reproductive structures and secondary sex characteristics (androgens). The medullary cells (from neural crest) receive sympathetic innervation and behave somewhat like sympathetic ganglia. They secrete epinephrine and norepinephrine, hormones important in the sympathetic response.

43

Nerve Supply of Suprarenal Gland

- Suprarenal gland cortex supplied by postganglionic sympathetic fibers from renal plexus (on artery branches)
- Suprarenal gland medulla receives preganglionic sympathetic nerves (T_{10} - L_1)
- Form synapses with medulla cells
- Medulla functions as ganglion
- Epinephrine and norepinephrine.



Netter 321

Slide 43.

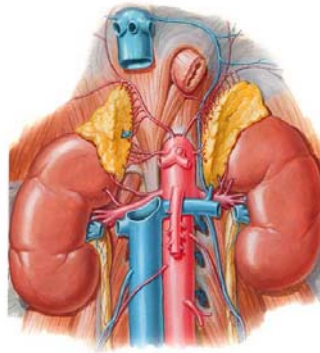
Like the kidney, the cortex of the adrenal gland is supplied by nerves from the renal plexus, with both parasympathetic and postganglionic sympathetic nerves. The adrenal medulla, however, receives preganglionic sympathetic nerves. These synapse directly with the cells of the adrenal medulla, and thus, the medulla can be considered acting as a ganglion, and the cells secrete epinephrine and norepinephrine in response to the preganglionic sympathetic nerves.

44

Blood Supply of Suprarenal Glands

- Superior suprarenal arteries from inferior phrenic artery
- Middle suprarenal artery directly from aorta
- Inferior suprarenal artery from renal artery (or segmental branch of renal artery)
- Left suprarenal vein drains into left renal vein
- Right suprarenal vein drains directly into IVC.

Netter 310



Slide 44.

The adrenal glands receive a rich blood supply from three sources. The superior adrenal arteries branch from the inferior phrenic arteries (branching from the aorta). The middle adrenal arteries are direct branches of the aorta. The inferior adrenal arteries branch from the renal arteries or from one of its segmental branches. The left adrenal vein drains to the left renal vein, but the right adrenal vein drains directly into the adjacent inferior vena cava.

Slide 45.

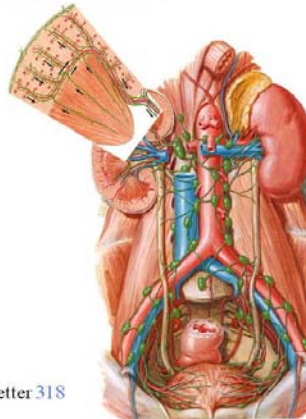
Lymphatic vessels from posterior abdominal structures drain to pre-aortic and para-aortic (or lumbar) nodes. Pre-aortic nodes are located at major arterial trunks of the aorta (celiac, superior mesenteric, inferior mesenteric) and receive lymph from structures supplied by these arteries. Pre-aortic nodes are connected by the intestinal trunk. Para-aortic nodes, on either side of the aorta, receive lymph from kidneys, adrenals, gonadal and common iliac nodes, and structures of the abdominal wall itself. These are connected by the right and left lumbar lymphatic trunks, paralleling the aorta. The cisterna chyli is a lymphatic sac just to the right of the aorta superior to the right renal artery that drains both lumbar trunks and the intestinal trunk. It is the beginning of the thoracic duct, conveying lymph from the abdomen, left side of the thorax, and left upper limb to the junction of left jugular and subclavian veins. Lymphatic drainage of the upper ureter follows drainage from the kidneys and adrenals to the para-aortic nodes. Lymphatic drainage of the lower ureter is to the internal iliac and then to common iliac nodes.

45

Lymphatic Drainage

- Pre-aortic nodes (celiac, SM, IM)
 - Lymph from structures supplied by those arteries
 - Connected by intestinal trunk
- Para-aortic or lumbar nodes
 - Kidneys, suprarenal glands, gonads, common iliac nodes, deep wall
 - Connected by right and left lumbar trunks
- Cisterna chyli
 - Lymph from 3 trunks
 - To thoracic duct.

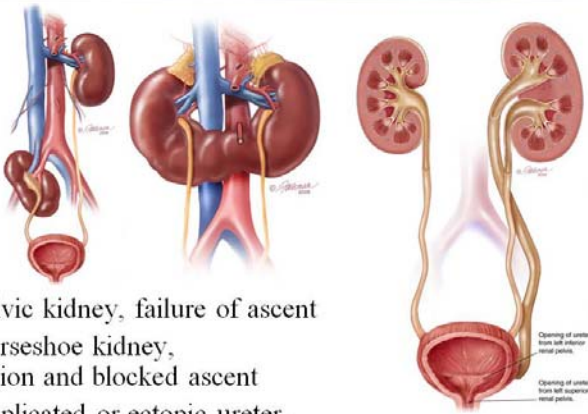
Netter 318



46

Anomalies of Kidney Formation

- Pelvic kidney, failure of ascent
- Horseshoe kidney, fusion and blocked ascent
- Duplicated or ectopic ureter.



from: www.urologyhealth.org

Slide 46.

A pelvic kidney, due to failure of ascent of one kidney, could be mistaken for a neoplastic mass in the pelvis. A horseshoe kidney, due to fusion of the inferior poles, is usually halted in its ascent by the inferior mesenteric artery and may also be misdiagnosed as a tumor in the abdomen or pelvis. Duplication of the ureter, due to extra branching of the ureteric bud at the start of development may result in faulty location or course of the ureter.

Pelvis and Perineum.

By Thierry Bacro

Center for Anatomical Studies and Education
Department of Regenerative Medicine and Cell Biology
College of Medicine
Medical University of South Carolina

Introduction: Slide 1-4

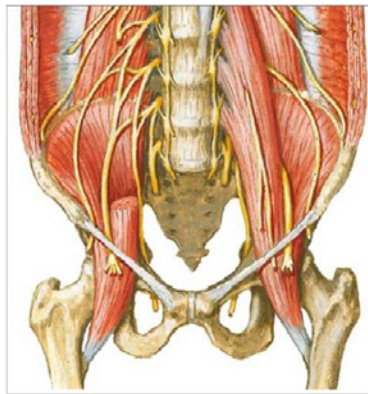
This lecture will detail the pelvic walls and floor and the perineum, including arterial supply, innervation, and sex differences. The specific contents of the male and female pelvis will be discussed in future lectures.

5

Pelvis Functions

- Support weight from trunk-vertebral column to lower limbs
- Attachment of trunk and lower limb muscles
- Protection of pelvic contents

Netter 486

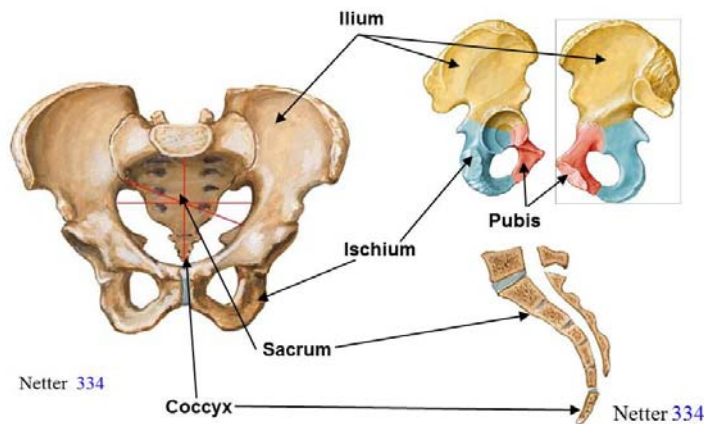


Slide 5.

The pelvis consists of two hip bones, the sacrum, and the coccyx. The pelvis functions to transmit the weight from the trunk through the vertebral column on to the lower extremities. The pelvis is also responsible for providing a sturdy and broad surface for the attachment of both lower limb and trunk muscles. Further, by acting like a bowl, the pelvis protects the pelvic viscera contained within: parts of the lower intestine and internal reproductive organs.

6

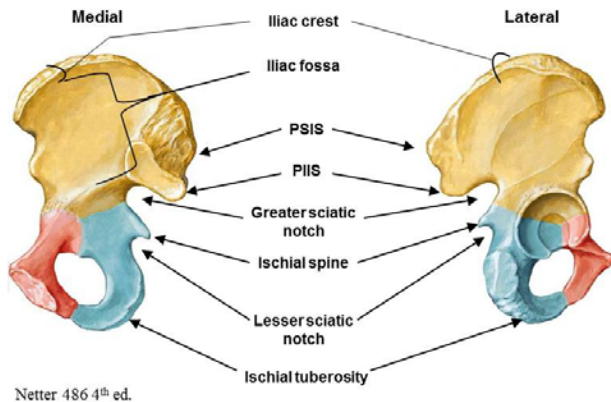
The Pelvis



Slide 6.

As mentioned previously the pelvis is composed of two hip bones, the sacrum, and the coccyx. These parts can be seen here. It is important to note that each hip bone is actually composed of three fused bones: the ilium, the ischium, and the pubis. The ilium is the largest and most superior bone, creating the lateral walls of the false pelvis (which will be discussed later). The ischium bones are where you sit. The pubic bones together create the pubic arch that is connected at the pubic symphysis.

Bony Structures

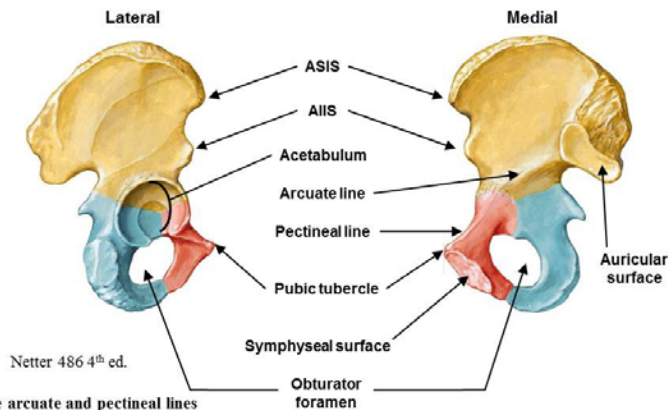


Slide 7.

There are many structures and landmarks that are on the hip bone, observed in the next two slides. The most obvious structure is where the three bones fuse, the acetabulum. It is located on the lateral side of the hip bone and is useful for orientation. The acetabulum helps to form the hip joint with the head of the femur. The thickening of the superior border of the ilium forms the iliac crest, ending at the anterior superior iliac spine (ASIS) and the posterior superior iliac spine (PSIS).

The iliac crest is the site of muscle and fascia attachment of the abdomen. Inferior to the ASIS and PSIS, there are another set of protuberances that serve as the attachment points for muscles of the lower limbs: the anterior inferior iliac spine (AIIS) and the posterior inferior iliac spine (PIIS). On the medial surface the arcuate line of the ilium is continuous with the pectineal line of the pubis. Together these lines form the iliopectineal line, which divides the pelvis into a true and a false pelvis. Between the arcuate line and the iliac crest is the iliac fossa. On the posterior aspect of the ischium, the ischial spine is located between the greater and lesser sciatic notches and is a site of ligament attachment.

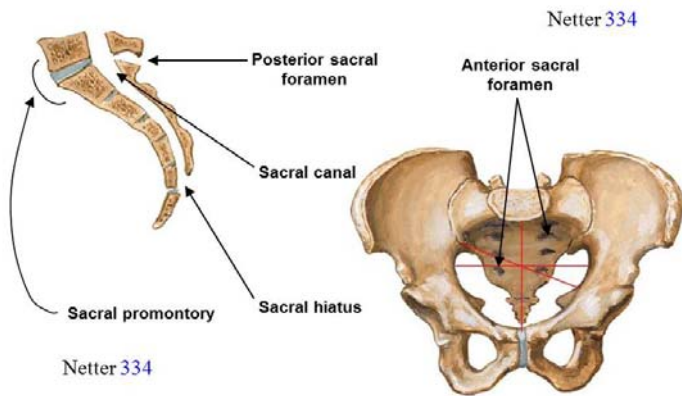
Bony Structures



Slide 8.

The obturator foramen is bound by the pubis and the ischium. The most inferior portion of the pelvis is the ischial tuberosity and the most anterior portion is the pubic tubercle. Also identified here is the symphyseal surface where the pubic symphysis is located and the auricular surface where the sacrum and hip bones articulate.

Bony Structures



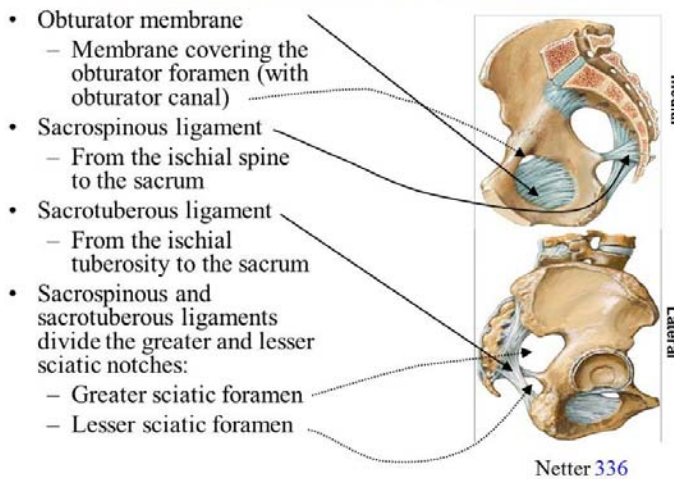
Slide 9.

Shown here, the sacrum is five fused vertebra continuous with the vertebral column at L₅ and the coccyx. The coccyx is four fused vertebra. The anterior and posterior sacral foramina allow the passage of the ventral and dorsal primary rami. The sacral canal is a continuation of the vertebral canal and ends inferiorly at the sacral hiatus. The anterior edge of the sacrum protrudes, called the sacral promontory. The sacral promontory forms the posterior aspect of the pelvic brim (see later).

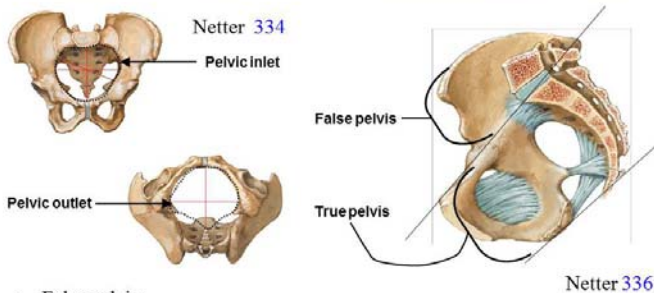
Slide 10.

Recall that the ischial spine is located on the posterior aspect of the hip bone, located between the greater and lesser sciatic notches. The sacrospinous ligament attaches from the ischial spine to the antero-lateral aspect of the sacrum and coccyx. The sacrospinous ligament helps to divide the greater and lesser sciatic notches into the greater and lesser sciatic foramina, respectively. The greater sciatic foramen allows passage of the piriformis muscle and vessels and nerves from the pelvis to the lower limb. The lesser sciatic foramen allows passage of the obturator internus muscle and vessels and nerves from the pelvis to the perineum and gluteal region (see later). The sacrotuberous ligament, located laterally to the sacrospinous ligament, attaches from the antero-lateral part of the sacrum and coccyx and the PIIS to the ischial tuberosity. The obturator membrane covers the obturator foramen. Note the obturator canal is the passage of an artery and nerve to the thigh.

Ligaments and Foramina



The Pelvis: True and False



- False pelvis:
 - Continuation of the abdominal cavity to the iliopectineal line (pelvic inlet)
- True pelvis:
 - Begins at the iliopectineal line/sacral prominence and ends at pelvic outlet (the ischial tuberosities and the tip of the coccyx)

Slide 11.

The pelvis is actually composed of two parts: the false pelvis and the true pelvis. The false pelvis is a continuation of the abdominal cavity and ends at the pelvic inlet (brim). The pelvic inlet runs from the sacral promontory to the pubic symphysis, following the iliopectineal line. The true pelvis begins at the pelvic inlet and ends at the pelvic outlet (the coccyx, ischial tuberosities, and pubic arch). The pelvic outlet is narrowed by the sacrospinous and sacrotuberous ligaments.

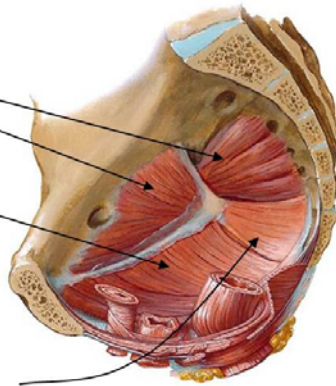
The Pelvic Muscles

The muscles of the pelvic wall:

- Piriformis muscle
- Obturator internus muscle

The muscles of the pelvic floor:

- Levator ani muscle: 3 parts
 - Puborectalis muscle
 - Pubococcygeus muscle
 - Iliococcygeus muscle
- Coccygeus (ischiococcygeus) muscle.

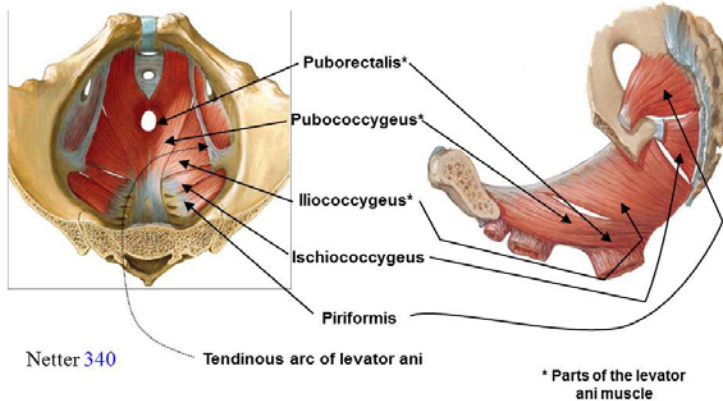


Netter 337

Slide 12.

There are two groups of pelvic muscles, the muscles of the pelvic wall and the muscles of the pelvic floor. The muscles of the pelvic wall are the obturator internus and the piriformis muscles. The obturator internus muscle arises from the obturator membrane and has a tendon that passes through the lesser sciatic foramen to attach on the femur. The piriformis muscle originates from the sacrum and its tendon passes through the greater sciatic foramen to attach on the femur. The muscles of the pelvic floor will be discussed on the next slide.

The Pelvic Muscles



Netter 340

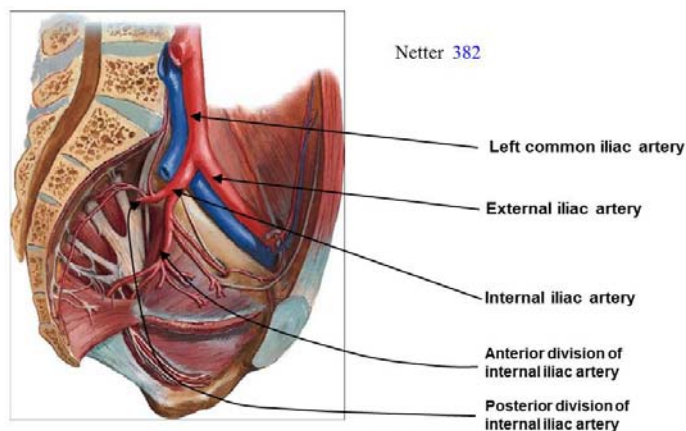
Netter 337

* Parts of the levator ani muscle

Slide 13.

The pelvic floor (also known as the pelvic diaphragm) is the group of muscles that comprise the pelvic outlet and mark the lower end of the pelvis. Inferior to the pelvic floor is the perineum, which will be discussed later in the lecture. Levator ani and ischiococcygeus muscles are the two muscles that compose the pelvic floor. Levator ani muscle has three sets of fibers with differing attachments. The puborectalis connects from the pubis to the rectum, forming a “sling”. The pubococcygeus connects from the pubis to the coccyx. The iliococcygeus originates from a fascia thickening covering the obturator internus muscle, termed the tendinous arch. The ischiococcygeus muscle is separate from levator ani and originates from the ischial spine and inserts at the lower border of the sacrum and the coccyx.

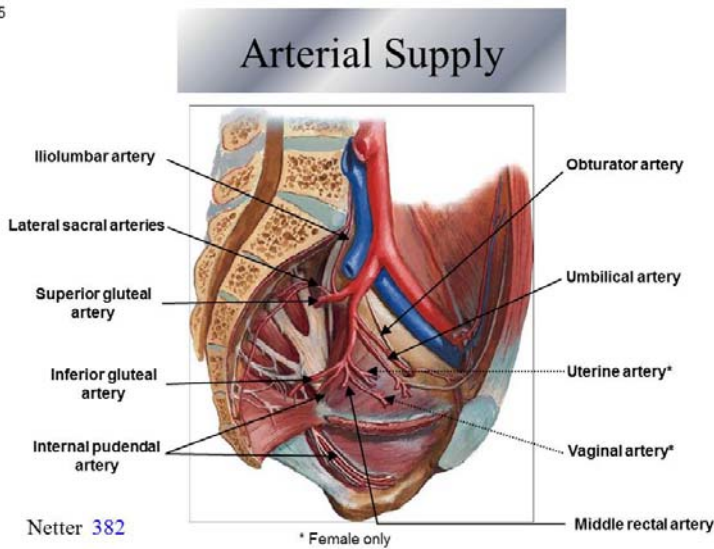
Arterial Supply



Netter 382

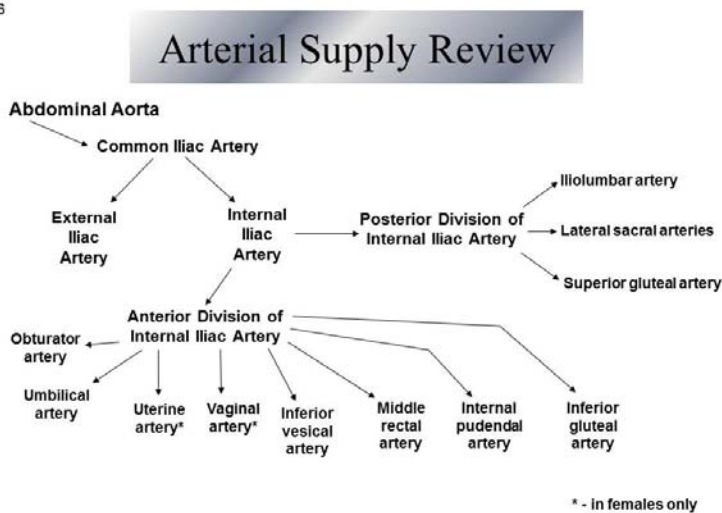
Slide 14.

The blood supply of the pelvis is from the abdominal aorta by way of the internal iliac artery. At the level of L₄, the aorta bifurcates into the common iliac arteries. At the pelvic inlet, anterior to the sacroiliac joint, the common iliac artery branches into the internal and external iliac arteries. The pelvis is supplied by the internal iliac artery, which further branches into anterior and posterior divisions.



Slide 15.

The largest branch from the posterior division of the internal iliac artery is the superior gluteal artery, which leaves the pelvis between the lumbosacral trunk and S₁ through the greater sciatic foramen to the gluteal region. The iliolumbar artery and lateral sacral arteries also arise from the posterior division. The anterior division of the internal iliac artery has many important branches that should be named according to path and relationship to visceral structures. The obturator artery leaves pelvis through obturator canal. The umbilical artery is found between bladder and lateral wall becoming the medial umbilical fold. The uterine artery runs medially to floor of pelvis into broad ligament of uterus and the vaginal artery runs anteriorly to the side of the vagina and inferior bladder (both only in females). The inferior vesical artery (males only) goes to prostate and seminal vesicles. The middle rectal artery supplies the inferior portion of the rectum. The internal pudendal artery leaves through greater sciatic foramen to enter the gluteal region, then enters the perineum through lesser sciatic foramen. Finally the inferior gluteal artery leaves the pelvis through greater sciatic foramen between S₂ and S₃.

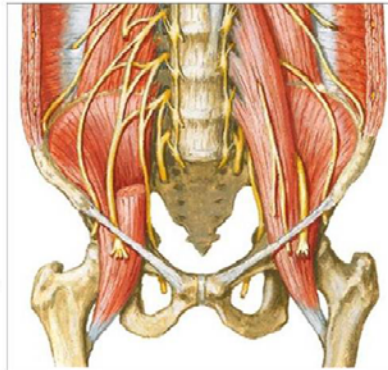


Slide 16.

A simplified review of the arterial supply to the pelvis. There is extensive variation in the branches of the pelvis; it is important to identify the arteries based on their visceral relationships, not just order alone.

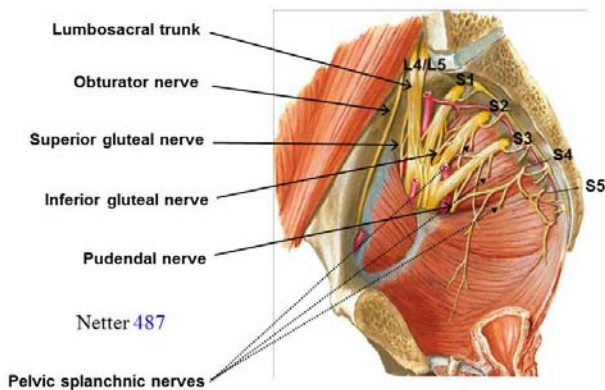
Pelvic Innervation

- The lumbar plexus has 2 branches entering the pelvis:
 - Obturator nerve
 - Lumbosacral trunk (L₄-L₅), joins sacral plexus
- Sacral plexus
- Sympathetic supply: arise from L₁-L₂
- Parasympathetic supply: arise from S₂-S₄ (pelvic splanchnic nerves)



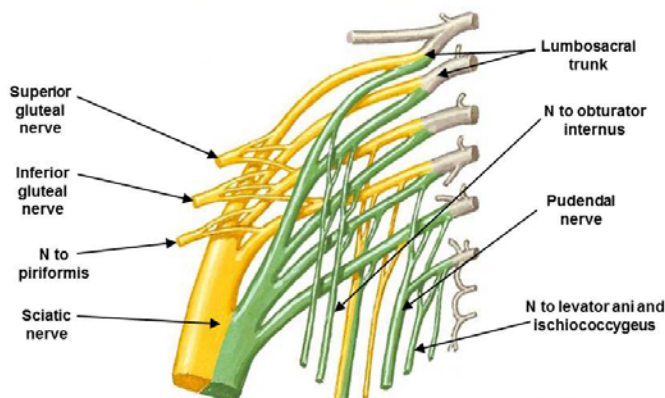
Netter 486

Sacral Plexus in Pelvis



Netter 487

Sacral Plexus



Netter 487

Slide 17.

The nervous supply to the pelvis is composed of branches from the lumbar plexus and the sacral plexus. The obturator nerve and the lumbosacral trunk, seen in this slide, arise from the lumbar plexus. The obturator nerve descends medial to the psoas muscle and crosses the sacroiliac joint, then moves to enter the obturator canal with the obturator artery. The lumbosacral trunk (L₄-L₅) leaves to join the sacral plexus and contribute to the sciatic nerve. The sympathetic supply of the pelvis is from the lumbar splanchnic nerves and sacral splanchnic nerves (L₁-L₂). The parasympathetic supply of the pelvis is from the pelvic splanchnic nerves (S₂-S₄). Both sympathetic and parasympathetic nerves are transmitted via various plexuses to the various targets within the pelvis.

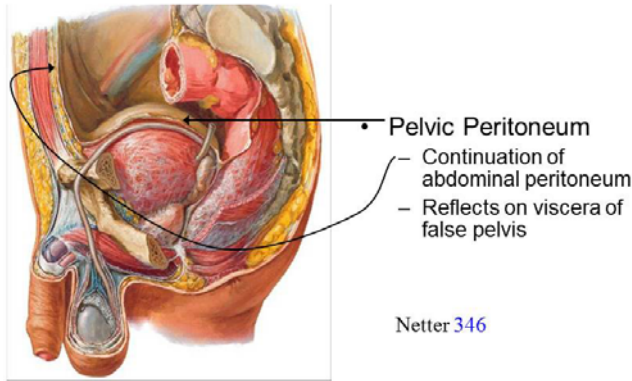
Slide 18.

The sacral plexus is located on the posterior-lateral wall of the pelvis, anterior to the piriformis muscle. Mentioned before, the sciatic nerve is the largest branch and exits to the gluteal region, supplying the lower limb. The superior gluteal nerve exits the pelvis with the superior gluteal artery through the greater sciatic foramen. The inferior gluteal nerve is found posterior to the sciatic nerve and exits the pelvis through the greater sciatic foramen (seen later). The pudendal nerve exits the pelvis between piriformis and ischiooccygeus muscles through the greater sciatic foramen and re-enters the perineum through the lesser sciatic foramen (PIN structure). The pelvic splanchnic nerves can also be seen here arising from S₂, S₃, and S₄.

Slide 19.

Additional branches of the sacral plexus that are motor to muscles of the pelvis are identified in this schematic: the nerve to the obturator internus (PIN structure), the nerve to levator ani and ischiooccygeus, and the nerve to piriformis.

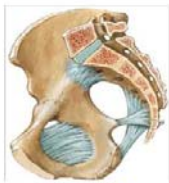
Peritoneum



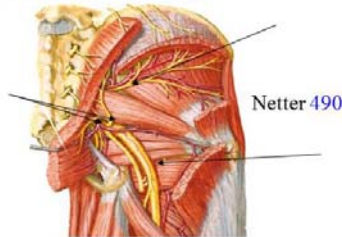
Slide 20.

Observe here that the pelvic peritoneum is a continuation of the abdominal peritoneum. This pelvic peritoneum reflects on the viscera of the false pelvis and will be discussed in a future lecture. Not shown here, but this reflection onto the pelvic viscera creates low points in both males and females. In the male peritoneal cavity, the reflection of peritoneum between the rectum and bladder forms the rectovesical pouch. In the female peritoneal cavity, the reflection of peritoneum between the rectum and posterior wall of the vagina and uterus forms the rectouterine pouch.

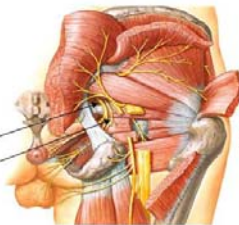
The Pelvic Foramina



Netter 336



Netter 490



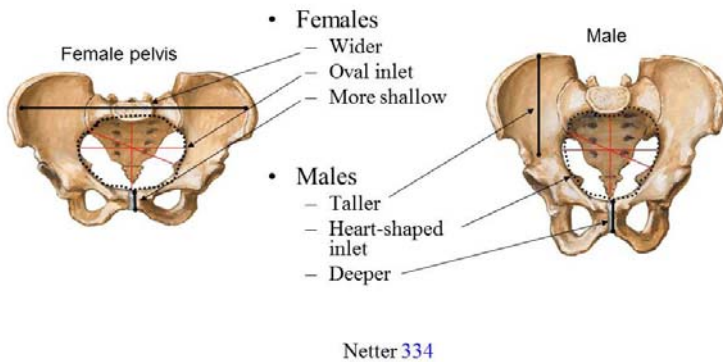
Netter 491

- Greater sciatic foramen:
 - Sciatic nerve
 - Superior gluteal nerve
 - Superior gluteal artery
 - Inferior gluteal nerve
 - Inferior gluteal artery
- Greater sciatic foramen to the lesser sciatic foramen:
 - Pudendal nerve
 - Internal pudendal artery
 - N. to obturator internus

Slide 21.

From this posterior view, the relationship between the greater and lesser sciatic foramina can be appreciated. The arteries and nerves that exit the pelvis through the greater sciatic foramen are the sciatic nerve, the superior gluteal artery and nerve, and the inferior gluteal artery and nerve. The PIN structures exit the pelvic cavity via the greater sciatic foramen and re-enter the perineum via the lesser sciatic foramen. The PIN structures are the Pudendal nerve, the Internal pudendal artery, and the Nerve to the obturator internus. Recall that the piriformis muscle passes through the greater sciatic foramen and that the obturator internus muscle passes through the lesser sciatic foramen to attach to the femur.

Pelvic Sex Differences

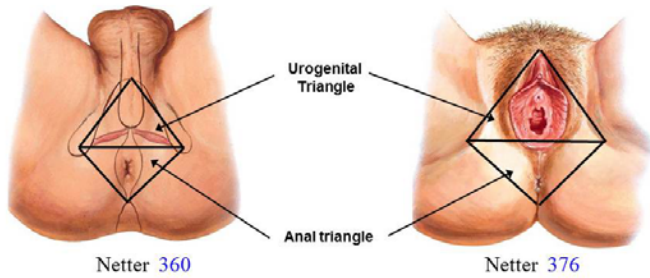


Slide 22.

Differences between the male and female pelvis relate to pregnancy, child birth, and muscular support. The female pelvis is wider to support the fetus during pregnancy and the anterior portion of the pubis bone is shallower with a more obtuse pubic arch angle. Also the female pelvic inlet is more oval (to allow for passage of the fetus during childbirth). The male pelvis is taller, allowing for greater support for muscle attachments. The anterior portion of the pubis bone is deeper, again adding in support. Finally the male pelvic inlet is more oriented like the shape of a heart.

23

Perineum Boundaries

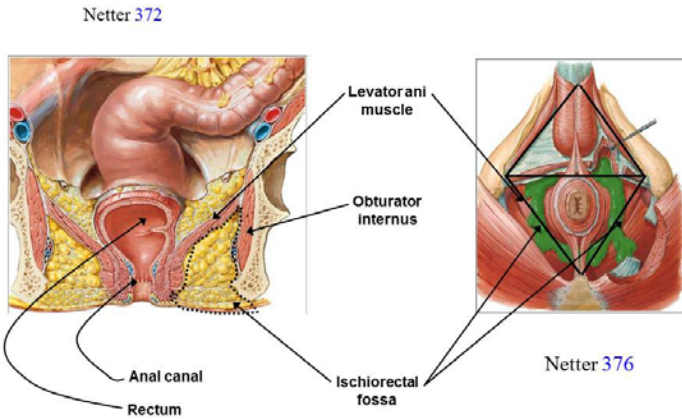


Slide 23.

The perineum is the area that is located inferior to the pelvic floor and is contained inferiorly by the skin. It is important to remember that in this area, structures that are superior in the perineum are considered deep and structures that are inferior in the perineum are considered superficial. The perineum is a diamond-shaped area: pubic symphysis anteriorly, the tip of the coccyx posteriorly, and the ischial tuberosities laterally, with a line between the ischial tuberosities separating the perineum into the anal triangle and the urogenital triangle.

24

Anal Triangle

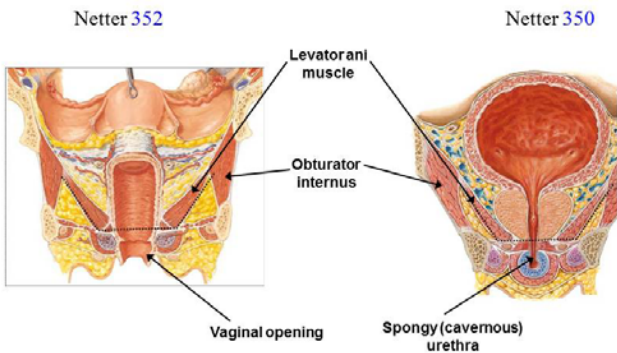


Slide 24.

Within the anal triangle the levator ani muscle can be seen forming the superior boundary of the perineum (the pelvic floor). The lateral borders are formed by the ischial tuberosities. The external anal sphincter muscle lines the anal canal and aids in controlling the anus. The ischiorectal fossa is a fat-containing area between the ischial tuberosities and levator ani muscle that allows for distension during defecation. The ischiorectal fossa of the anal triangle communicates with the urogenital triangle. Infections originating in the anal triangle may pass to the urogenital triangle.

25

Urogenital Triangle

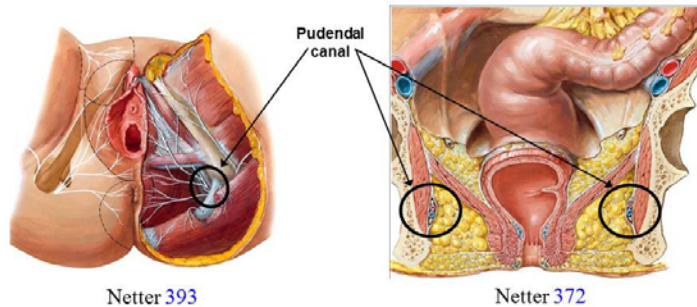


Slide 25.

The urogenital triangle contains the urethra in both sexes. In females, the vagina passes through the pelvic floor into the perineum. The urogenital triangle is bound posteriorly by the superficial transverse perineal muscles. Note the prostate gland in the male cross-section.

Pudendal Canal

- Passage of internal pudendal artery, pudendal nerve, and perineal nerve
- In fascia of obturator internus muscle



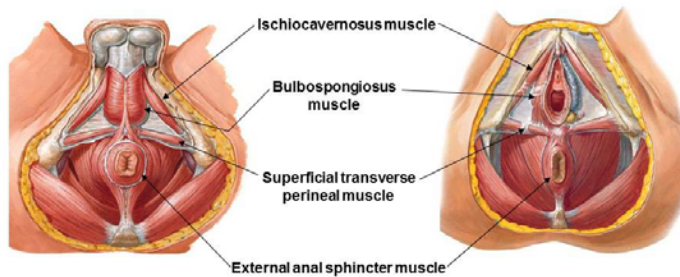
Netter 393

Netter 372

Slide 26.

The pudendal canal is located within the ischiorectal fossa. Specifically, the pudendal canal is located within the fascia of the obturator internus muscle. It transmits the internal pudendal artery, the pudendal nerve, and the perineal nerve (a branch of the pudendal nerve) after re-entering the pelvis through the lesser sciatic foramen.

The Muscles



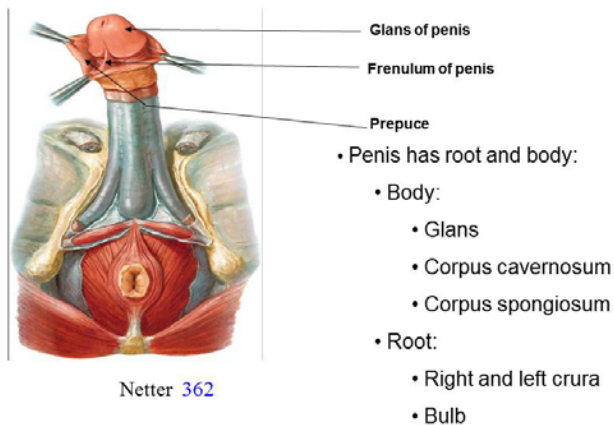
Netter 375

Netter 358

Slide 27.

The muscles that can be found in the perineum are split between the anal and urogenital triangles and located just deep to the skin and fascia. The anal triangle contains the external anal sphincter, seen in both the male and female perineum. The urogenital triangle contains three paired muscles: the ischiocavernosus muscle, found laterally; the bulbospongiosus muscle, found along the midline; and the superficial transverse perineal muscle, at the posterior border. These muscles are responsible for forcing blood into erect tissue in both males and females. The ischiocavernosus and bulbospongiosus muscles cover structures of the male and female genitalia and will be discussed in the following slides.

Male Genitalia

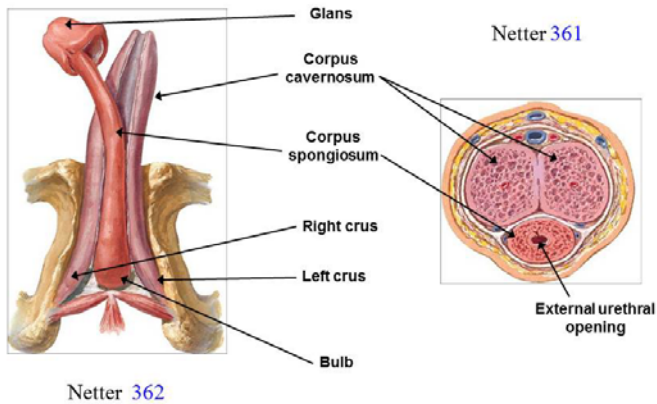


Netter 362

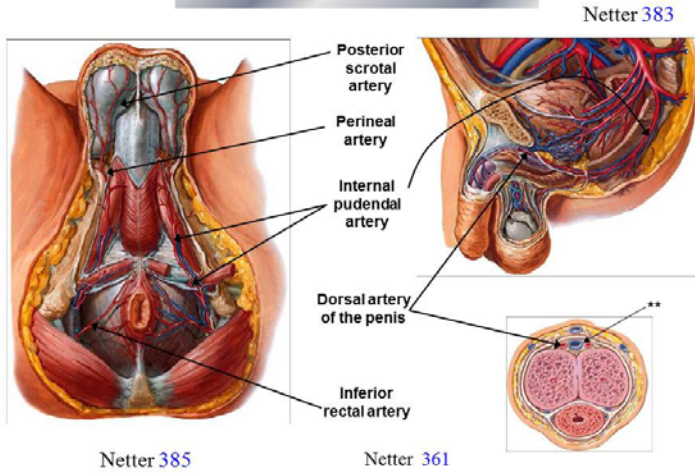
Slide 28.

The penis is the genitalia of the male sex. The penis is composed of a body and two roots. The body of the penis has a glans, corpus cavernosum, and corpus spongiosum. The prepuce is connected to the body of the penis by the frenulum. The prepuce is removed during circumcision. The root of the penis is discussed in the next slide.

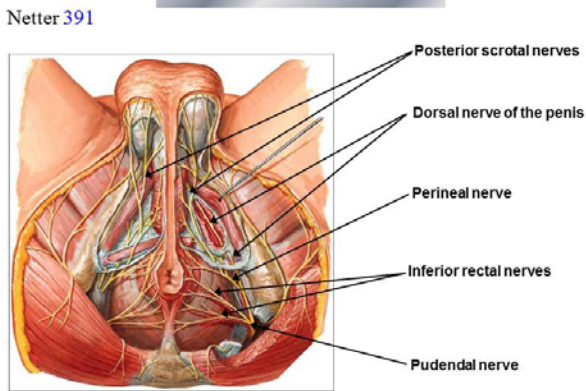
Male Genitalia



Male Arteries



Male Nerves



Slide 29.

The root of the penis is composed of right and left crura and the bulb. The crura are formed by the corpus cavernosum tissue. The bulb is formed by the corpus spongiosum tissue and is where the urethra is located. The right and left crura are covered by the ischiocavernosus muscles and the bulb of the penis is covered by the bulbospongiosus muscles.

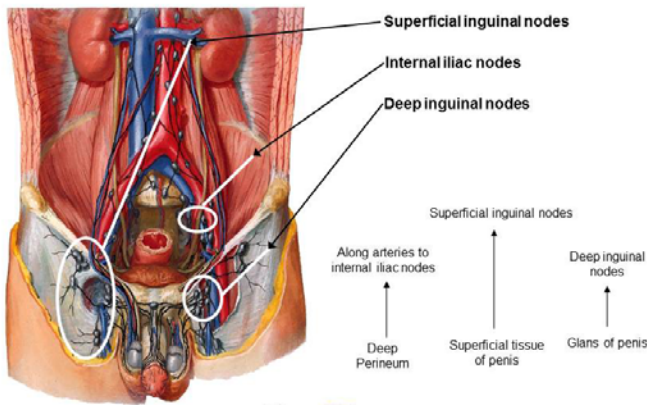
Slide 30.

The root of the penis is composed of right and left crura and the bulb. The crura are formed by the corpus cavernosum tissue. The bulb is formed by the corpus spongiosum tissue and is where the urethra is located. The right and left crura are covered by the ischiocavernosus muscles and the bulb of the penis is covered by the bulbospongiosus muscles.

Slide 31.

The innervation of the male perineum is by branches from the pudendal nerve. The inferior rectal nerves branch off the pudendal nerve just after the perineal nerve leaves the pudendal canal. Once the pudendal nerve enters the pudendal canal, it gives the perineal nerve, which further gives the posterior scrotal nerves. The pudendal nerve also gives the dorsal nerve of the penis. Although not shown in this slide, it is important to note that the autonomic nervous system innervates the erectile tissue. Parasympathetic nerves (the pelvic splanchnic nerves) are responsible for erections, whereas sympathetic nerves (from the lumbar and sacral splanchnic nerves) are responsible for ejaculation.

Male Lymphatics



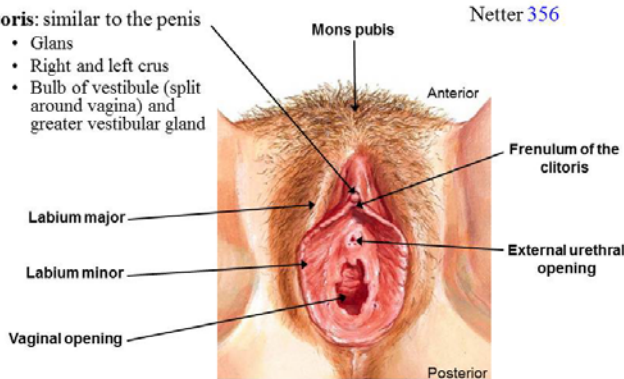
Netter 388

Slide 32.

The deep portion of the perineum will drain through nodes that follow the arteries of the internal iliac artery until the lymph reaches the internal iliac nodes. Lymph from the superficial portion of the perineum is drained by the superficial inguinal nodes and lymph from the glans of the penis drains to the deep inguinal nodes.

Female Genitalia

- **Clitoris:** similar to the penis
 - Glans
 - Right and left crus
 - Bulb of vestibule (split around vagina) and greater vestibular gland

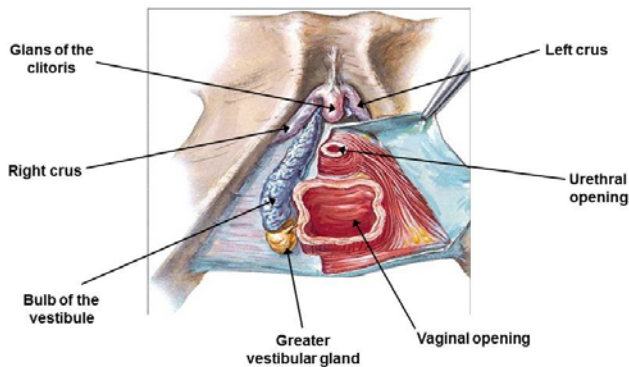


Netter 356

Slide 33.

In addition to the urethra and anal canal, the female perineum has the passage of the vagina. The mons pubis is the area just superficial to the pubic symphysis. The labium major is lateral to the labium minor. The frenulum is just posterior to the glans and connects the right and left labia minora. The clitoris is similar to the penis in males, consisting of a glans, right and left crura, and bulb of vestibule. Note that the bulb of the vestibule splits to surround the vagina and has a greater vestibular gland associated with it.

Female Genitalia

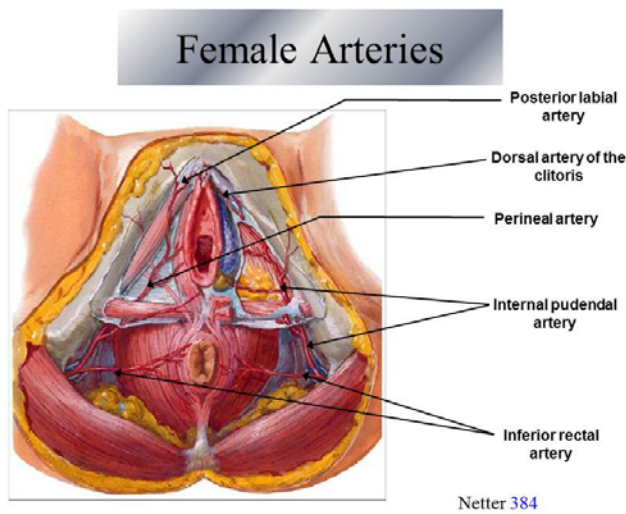


Netter 358

Slide 34.

Seen here are the parts that compose the clitoris. The glans of the clitoris is visible externally. The right and left crura are covered by the ischiocavernosus muscles. The bulb of the vestibule is covered by the bulbospongiosus muscles.

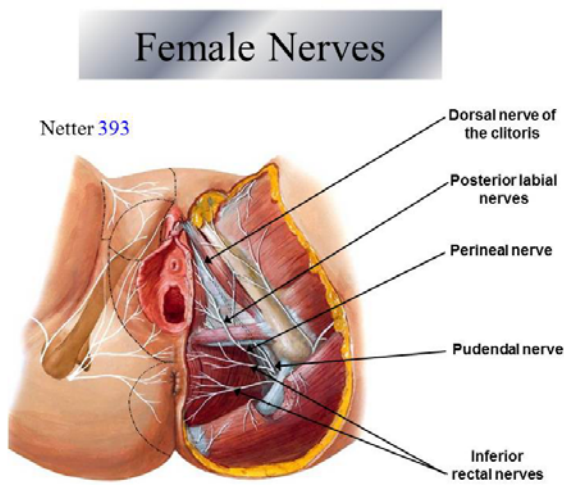
35



Slide 35.

The arterial supply of the female perineum is similar to that of the male with the exception of the dorsal artery of the clitoris replacing the dorsal artery of the penis.

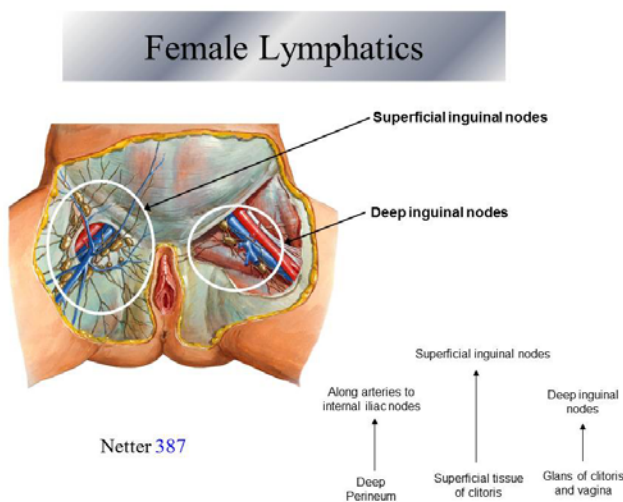
36



Slide 36.

As with the arterial supply, the female perineum innervation is similar to that of the male with the exception of the dorsal nerve of the clitoris replacing the dorsal nerve of the penis.

37



Slide 37.

Lymph drainage of the female perineum is similar to that of the male perineum. The deep portion of the female perineum drains following the arterial supply eventually to the internal iliac nodes. The lymph from the superficial tissue of the perineum drains to the superficial inguinal nodes. Lymph from the glans of the clitoris and vagina drains to the deep inguinal nodes.

Slide 37.

The End.

Contents of the Male Pelvis.

By Thierry Bacro, Ph.D

Department of Regenerative Medicine and Cell Biology
Center for Anatomical Studies and Education
College of Medicine
Medical University of South Carolina

Introduction.

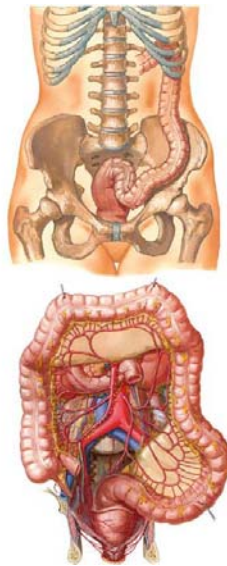
Slide 1: In this lecture, we will discuss the contents of the male pelvis. We will start with the organs that are common to both male and female and then continue with the organs that are specific to the male pelvis. Note that the bony pelvis as well as the pelvic muscles, nerves and vessels have already been studied. Please take time to review this information before studying this lecture.

2

Sigmoid Colon

- Continuation of the descending colon
- Anterior to the pelvic brim (starts at)
- Continuous with rectum in the front of the 3rd sacral vertebra
- Is about 10 to 15 inches long
- Mobile (intraperitoneal): fan-shaped sigmoid mesocolon
- Has haustra, epiploic appendices and free tenia
- Site of storage of the feces before evacuation.

Netter 285 and 307



II. The pelvic organs common to both male and female.

2. 1. The sigmoid colon.

Slide 2.

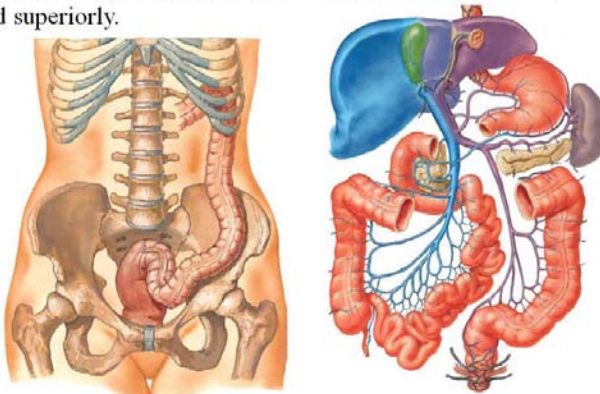
The sigmoid colon is the continuation of the descending colon. It starts at the level of the pelvic brim. It then becomes continuous with the rectum in the front of the 3rd sacral vertebra. The sigmoid colon is about 10 to 15 inches long. It is mobile (intraperitoneal) and hangs from the fan-shaped sigmoid mesocolon in the pelvic cavity. Note the characteristic looping shape of this organ and recall the fact that the sigmoid colon has haustra, epiploic appendices and free tenia (longitudinal bands of muscle). The sigmoid colon is a site of storage of the feces before evacuation into the rectum.

3

Sigmoid Colon

Netter 285 and 312

The bony pelvis (coxal bone and sacrum) and the rectum are found posteriorly. The lower coils of the terminal ileum are found superiorly.



Slide 3.

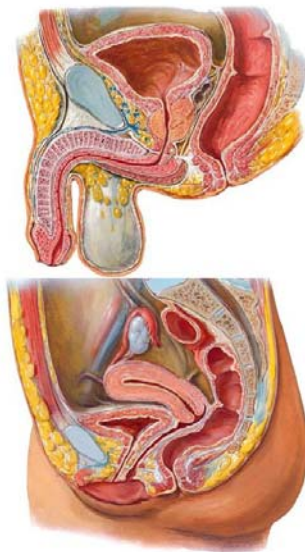
In terms of relationship with other organs, the bony pelvis (coxal bone and sacrum) and the rectum are found posteriorly. The lower coils of the terminal ileum are found superiorly.

4

Sigmoid Colon

- The urinary bladder is found anterior to the sigmoid colon in male
- The posterior surface of the uterus and the most superior part of the vagina are found anterior to the sigmoid colon in female.

Netter 360 and 361



Slide 4.

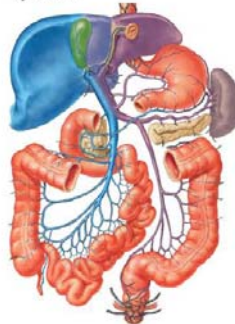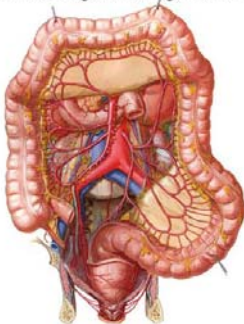
Note that the urinary bladder is found anterior to the sigmoid colon in male whereas the posterior surface of the uterus and the superior part of the vagina are found anterior to the sigmoid colon in female.

5

Blood Supply

Netter 307 and 312

- Is by the sigmoid arteries, from the inferior mesenteric artery. Note the how these arteries also branch in anastomotic loops or arcades before ending in straight arteries.
- The blood drainage is by tributaries of the inferior mesenteric vein, which then drains in the portal system.



Slide 5.

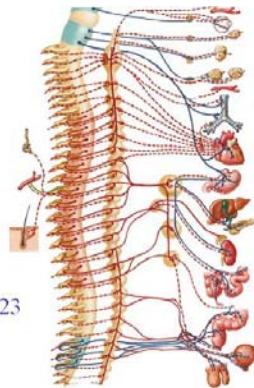
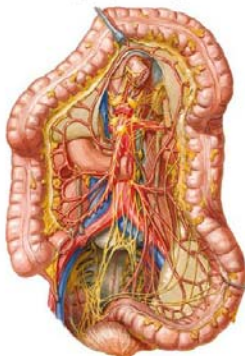
The blood supply to the sigmoid colon is by the sigmoid arteries, from the inferior mesenteric artery. Note the how these arteries also branch in anastomotic loops or arcades before ending in straight arteries. The blood drainage is by tributaries of the inferior mesenteric vein, which then drains into the portal system.

6

Nerve Supply

By sympathetic and parasympathetic fibers, mainly from the inferior hypogastric plexuses.

Netter 167 and 323



The lumbar and the sacral splanchnic nerves bring sympathetic fibers.
The pelvic splanchnic nerves bring parasympathetic fibers.

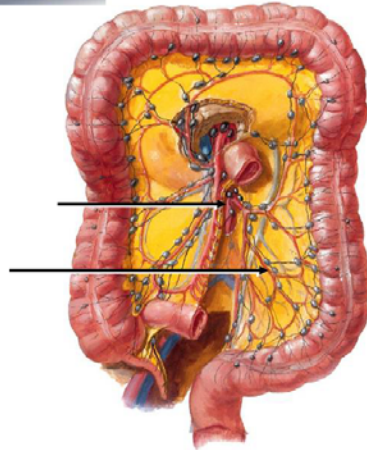
Slide 6.

The nerve supply to the sigmoid colon is by sympathetic and parasympathetic fibers, mainly from the inferior hypogastric plexuses. Recall how the lumbar and the sacral splanchnic nerves (sympathetic) bring pre-ganglionic fibers to the right and left inferior hypogastric plexuses and how the post-ganglionic fibers originate there to reach the pelvic organs. Note also how the proximal part of the sigmoid colon receives post-ganglionic fibers originating from the superior hypogastric plexus and the inferior mesenteric plexus. The parasympathetic innervation is from the pelvic splanchnic nerves.

Lymphatic Drainage

Netter 317

The lymphatic drainage of the sigmoid is through nodes found along the sigmoid arteries and then into the inferior mesenteric nodes.

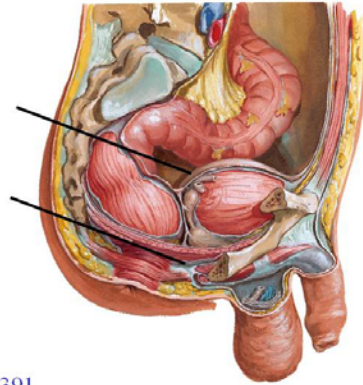


Slide 7.

The lymphatic drainage of the sigmoid is through nodes found along the sigmoid arteries and then into the inferior mesenteric nodes.

Rectum

- Is the continuation of the sigmoid colon
- Starts at the level of the 3rd sacral vertebra
- Passes downward, anterior to the curve of the sacrum and coccyx
- Ends at the tip of the coccyx by becoming the anal canal



Netter 391

2.2. The rectum

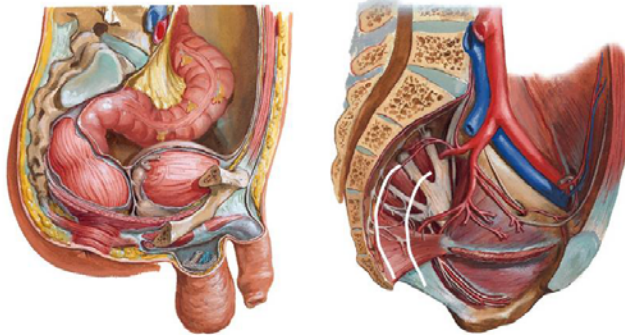
Slide 8.

The rectum is the continuation of the sigmoid colon. It starts at the level of the 3rd sacral vertebra. It passes downward, anterior to the curve of the sacrum and coccyx and ends at the tip of the coccyx by becoming the anal canal (see next).

Relationships

Netter 391 and 402

Note how posteriorly the rectum is in contact with sacrum and coccyx, the piriformis, and coccygeus and levatores ani muscles, the sacral plexus and the sympathetic trunks.



Slide 9.

Note how posteriorly the rectum is in contact with sacrum and coccyx, the piriformis, and coccygeus and levatores ani muscles, the sacral plexus and the sympathetic trunks.

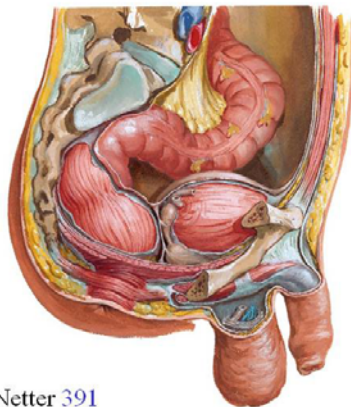
Anterior Relationships in Male

The upper 2/3 of the rectum:

- Is covered anteriorly by peritoneum
- Is related to the distal portion of the sigmoid colon and the lower coils of the terminal ileum found in the rectovesical pouch.

The lower 1/3 of the rectum:

- Is related to the posterior aspect of the bladder and its associated organs (termination of the vas deferens, seminal vesicles on each side and the prostate).



Netter 391

Slide 10.

In male, the upper 2/3 of the rectum is covered anteriorly by peritoneum and is related to the distal portion of the sigmoid colon and the lower coils of the terminal ileum found in the rectovesical pouch. The lower 1/3 of the rectum in male is related to the posterior aspect of the bladder and its associated organs (termination of the vas deferens, seminal vesicles on each side and the prostate: see later in this lecture).

Anterior Relationships in Female

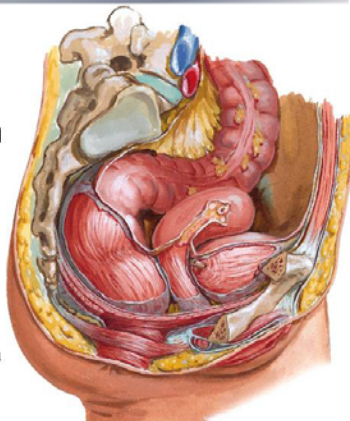
The upper 2/3 of the rectum:

- Is covered anteriorly by the peritoneum
- Is related to the distal portion of the sigmoid colon, the lower coils of the terminal ileum (in the rectouterine pouch of Douglas)

The lower 1/3 of the rectum:

- Is not covered by peritoneum and is in contact anteriorly with the posterior aspect of the vagina.

Netter 391

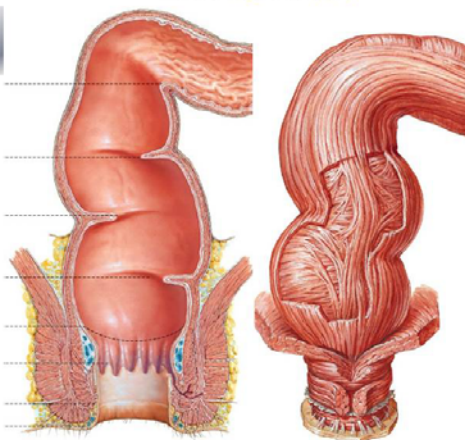


Slide 11.

In female, the upper 2/3 of the rectum is, like in male, covered anteriorly by peritoneum and related to the distal portion of the sigmoid colon, the lower coils of the terminal ileum. Note however that in this case, these organs are in the rectouterine pouch (pouch of Douglas). The lower 1/3 of the female rectum is not covered by peritoneum and is in contact anteriorly with the posterior aspect of the vagina.

Rectum

- Peritoneum
- External longitudinal layer
- Internal circular layer of muscle
- Internal mucous membrane (muscularis mucosae)
- Superior, middle and inferior transverse folds (valves of Houston) formed by the mucous membrane and the circular muscle layer
- The rectal ampulla or distal dilated part of the rectum.



Netter 393 and 394

Slide 12.

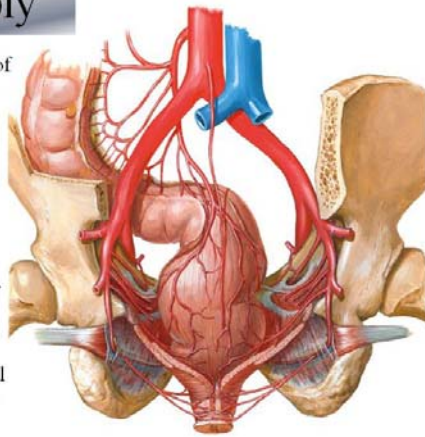
In this anterior view and frontal cross-section of the rectum, observe the following features associated of the rectum:

- The peritoneum coverings, the external longitudinal layer of muscle on mainly the anterior and posterior aspect of the organ (a continuation of the 3 tenia coli), the internal circular layer of muscle and finally the internal mucous membrane (muscularis mucosae)
- The superior, middle and inferior transverse folds (valves of Houston) formed by the mucous membrane and the circular muscle layer
- The rectal ampulla or distal dilated part of the rectum.

13

Blood Supply

- Superior rectal artery (branch of the inferior mesenteric artery): descends in the pelvis (in the sigmoid mesocolon) and divides into right and left branches, which anastomose distally with each other and with the middle and inferior rectal arteries.
- Middle rectal artery (branch of the internal iliac artery)
- Inferior rectal artery being a branch of the internal pudendal artery (a branch of the anterior division of the internal iliac artery)
- Note that these arteries anastomose with one another.



Netter 398

Slide 13.

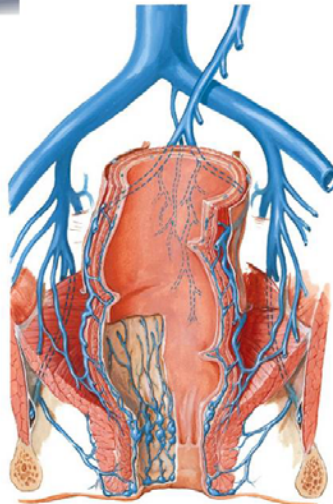
The superior, middle and inferior rectal arteries provide blood supply to the rectum. The superior rectal artery is one of the terminal branches of the inferior mesenteric artery. It descends into the pelvis in the sigmoid mesocolon and divides into right and left branches, which anastomose distally with each other and with the middle and inferior rectal arteries. The middle rectal artery is a branch of the internal iliac artery with the inferior rectal artery being a branch of the internal pudendal artery (itself a branch of the anterior division of the internal iliac artery). Note that the inferior rectal artery anastomoses with the middle rectal artery at the anorectal junction.

14

Venous Drainage

- Veins match named arteries
- Superior rectal vein drains in the inferior mesenteric vein (portal circulation)
- Middle rectal vein drains in the internal iliac vein and the inferior rectal vein in the internal pudendal vein (caval circulation)
- Note the portal-systemic bypass
- Observe the anastomotic connections: the internal and external rectal plexuses and the perimuscular rectal venous plexus.

Netter 399



Slide 14.

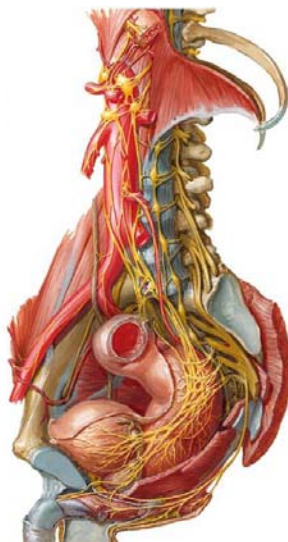
The veins of the rectum matches the arteries named in the previous slide. Note, however, that the superior rectal vein drains into the inferior mesenteric vein (part of the portal circulation), with the middle rectal vein draining into the internal iliac vein and the inferior rectal vein into the internal pudendal vein. Note that these last two veins are part of the caval circulation. Observe the anastomotic connections, the internal and external rectal plexuses and the perimuscular rectal venous plexus. The importance of this portal-systemic anastomosis has been discussed in previous lectures.

15

Nerve Supply

The innervation of the rectum is by the sympathetic and parasympathetic fibers from the inferior hypogastric plexuses, with the rectum being sensitive to stretch (gas and feces).

Netter 410



Slide 15.

The innervation of the rectum is by the sympathetic and parasympathetic fibers from the inferior hypogastric plexuses, with the rectum being sensitive to stretch (gas and feces).

Lymphatic Drainage

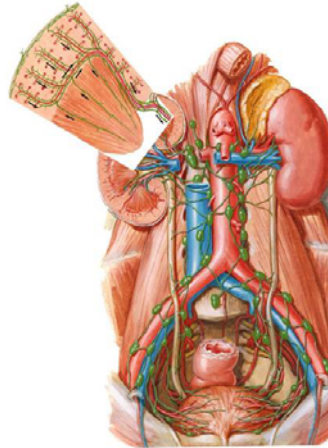
Netter 343

Upper part of the rectum:

Is into the pararectal nodes, draining then into the inferior mesenteric nodes through lymph vessels following the superior rectal artery

Lower part of the rectum:

Flows into the internal iliac nodes through lymph vessels following the middle rectal artery.



Slide 16.

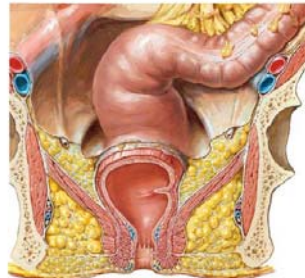
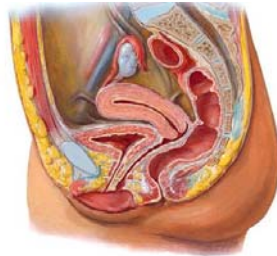The lymphatic drainage of the upper part of the rectum is into the pararectal nodes, draining then into the inferior mesenteric nodes through lymph vessels following the superior rectal artery. Lymph from the lower part of the rectum flows into the internal iliac nodes through lymph vessels following the middle rectal artery.

2.3. The anal canal

Anal Canal

- Continuation of the rectum
- Distal to the rectal ampulla, at the level of the sling of the puborectalis muscle
- Is about 1 ½ inch long
- Is found in the anal triangle described in perineum lecture
- Note in both male and female, the anal canal is bound laterally by the fat-filled ischioanal fossae and posteriorly by the anococcygeal body.

Netter 360 and 392



Slide 17.

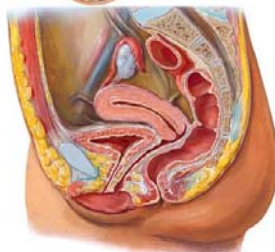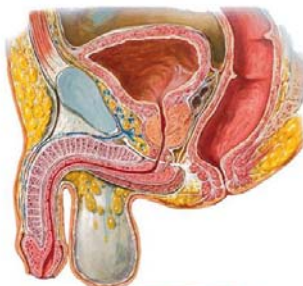The anal canal is the continuation of the rectum. It starts immediately distal to the rectal ampulla, at the level of the sling of the puborectalis muscle. It is about 1 ½ inch long and is found in the anal triangle that was described with the perineum. Note in both male and female, the anal canal is bound laterally by the fat-filled ischioanal fossae and posteriorly by the anococcygeal body.

Anterior Relationships

In the male, observe the perineal body, the urogenital diaphragm, the membranous part of the urethra and the bulb of the penis.

In the female, note the presence of the perineal body, the urogenital diaphragm and the lower part of the vagina.

Netter 360 and 361



Slide 18.

Anteriorly, in the male, observe the perineal body, the urogenital diaphragm, the membranous part of the urethra and the bulb of the penis. Anteriorly, in the female, note the presence of the perineal body, the urogenital diaphragm and the lower part of the vagina.

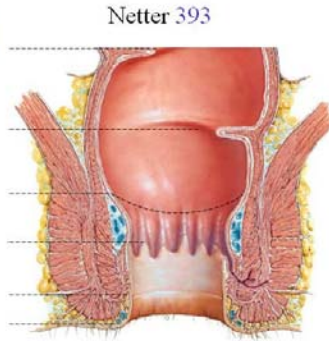
Anal Canal

The anal canal is composed of a:

- Longitudinal layer (continuation of the longitudinal layer of the rectum with fibers from the levator ani muscles)
- Circular layer
- Internal mucous membrane

The anal canal can be divided in two (pectinate or dentate line):

- The upper part, derived from the hindgut endoderm, lined by columnar epithelium; has anal columns, anal valves and anal crypts.
- The lower part, derived from the ectoderm of the proctodeum, lined by stratified epithelium (progressively merging with the perianal epidermis at the anus); no anal columns and associated structures.



Slide 19.

The anal canal is composed of a longitudinal layer (continuation of the longitudinal layer of the rectum with fibers from the levator ani muscles) and a circular layer. It is lined internally by a mucous membrane. Based on embryological origin, the lining of the mucous membrane of the anal canal can be divided in two parts, the upper part, derived from the hindgut endoderm and the lower part, derived from the ectoderm of the proctodeum. Note that the pectinate (dentate) line separates the upper from the lower anal canal. These 2 parts of the anal canal present very different features. The upper part is lined by columnar epithelium, has anal columns, anal valves and anal crypts. The lower part has stratified epithelium (progressively merging with the perianal epidermis at the anus), no anal columns and associated structures.

Anal Sphincters

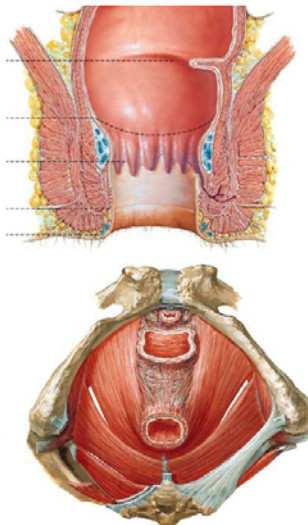
Anal canal has two sphincters:

- An involuntary internal sphincter, a thickening of the circular layer of the anal canal
- A voluntary external sphincter.

Note that the puborectalis (part of the levator ani) blends with the deep part of the external sphincter.

Recall also that the puborectalis muscle forms a sling passing at the junction of the rectum and the anal canal.

Netter 357 and 393



Slide 20.

The anal canal has two sphincters, an involuntary internal sphincter and a voluntary external sphincter. The internal sphincter is a thickening of the circular layer of the anal canal. Note that the puborectalis (part of the levator ani) blends with the deep part of the external sphincter. Recall that the puborectalis muscle forms a sling passing at the junction of the rectum and the anal canal.

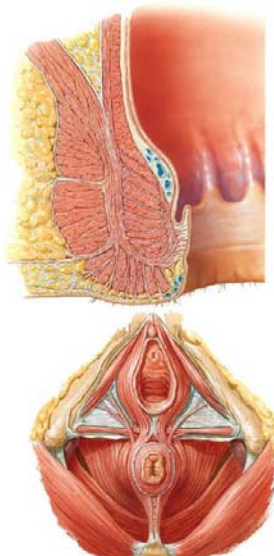
Sphincters

The external sphincter can be divided in three parts:

- A subcutaneous part, found at the lowest aspect of the anal canal
- A superficial part, attached posteriorly to the coccyx and anteriorly to the perineal body
- A deep part, located at the upper end of the anal canal.

Note that the internal and the 3 parts of the external sphincter form together an anorectal ring palpable on rectal examination.

Netter 394 and 395

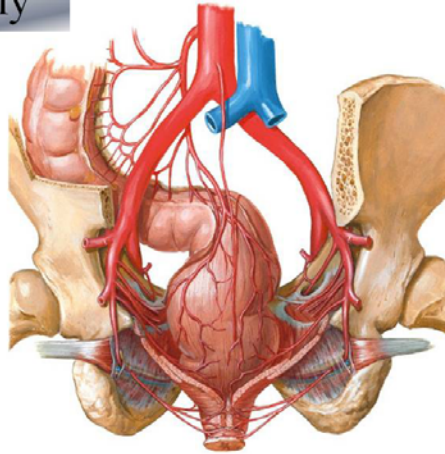


Slide 21.

The external sphincter can be divided in three parts: a subcutaneous part found at the lowest aspect of the anal canal, a superficial part attached posteriorly to the coccyx and anteriorly to the perineal body, and the deep part, located at the upper end of the anal canal. Note that the internal and the 3 parts of the external sphincter form together an anorectal ring that can be found on rectal examination.

Blood Supply

The upper part of the anal canal is by the superior rectal artery (branch of the inferior mesenteric artery). The blood supply to the lower portion of the anal canal is by the inferior rectal artery (branch of the internal pudendal artery).



Netter 398

Slide 22.

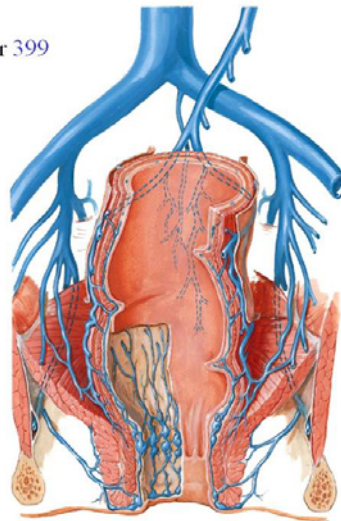
The blood supply to the upper part of the anal canal is by the superior rectal artery (branch of the inferior mesenteric artery). The blood supply to the lower portion of the anal canal is by the inferior rectal artery (branch of the internal pudendal artery).

Venous Return

Netter 399

- Upper part: by the superior rectal vein draining in the inferior mesenteric vein and then in the portal vein
- Lower part: by the inferior rectal vein draining in the internal iliac vein and then the inferior vena cava

Recall that any significant increase in blood pressure in the portal-systemic anastomosis due to liver disease can lead to internal or external hemorrhoids.

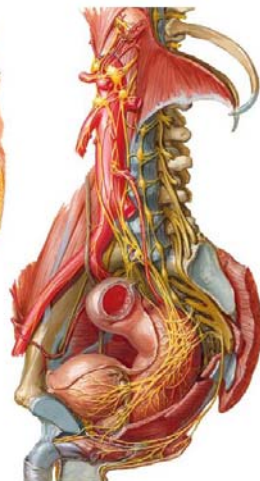
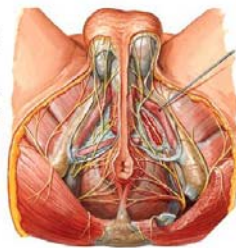


Slide 23.

The venous return of the upper portion of the anal canal is by the superior rectal vein draining into the inferior mesenteric vein and then into the portal vein. The venous drainage of the lower part of the anal canal is by the inferior rectal vein draining into the internal iliac vein and then the inferior vena cava. Recall that any significant increase in blood pressure in the portal-systemic anastomosis due to liver disease can lead to internal or external hemorrhoids.

Nerve Supply

- Sensory: mucous membrane of upper part is by fibers ascending through the hypogastric plexuses (only sensitive to stretch) with lower part of canal by fibers ascending through the inferior rectal nerves
- Motor: internal sphincter receive sympathetic innervation from the hypogastric plexuses whereas the voluntary external sphincter is innervated by the inferior rectal nerve.



Netter 410 and 411

Slide 24.

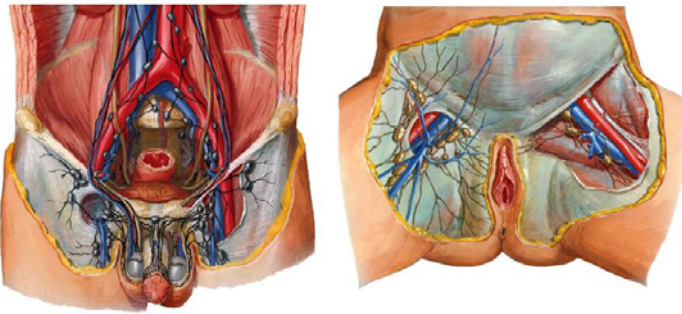
In terms of sensory innervation, note that the mucous membrane of the upper part of the anal canal is innervated by sensory fibers ascending through the right and left hypogastric plexuses. It is only sensitive to stretch. The lower portion of the anal canal is innervated by sensory fibers ascending through the inferior rectal nerves (branches of the pudendal nerve).

In terms of motor innervation, the muscle fibers of the internal sphincter receive sympathetic innervation from the hypogastric plexuses whereas the voluntary external sphincter is innervated by the inferior rectal nerve.

Lymphatic Drainage

Netter 408 and 407

Is in the pararectal nodes and then in the inferior mesenteric nodes. The lower part of the canal drains in the medial superficial inguinal nodes.



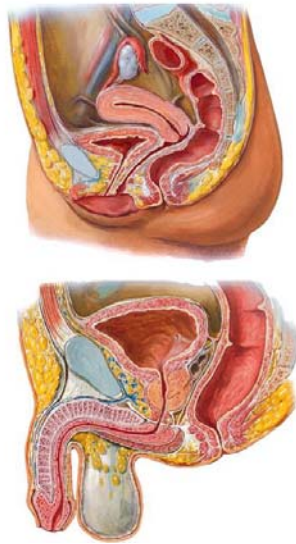
Slide 25.

The lymphatic drainage of the upper part of the anal canal is in the pararectal nodes and then in the inferior mesenteric nodes. The lower part of the canal drains into the medial superficial inguinal nodes.

Bladder

- Immediately posterior to the pubic symphysis in both male and female
- Able to receive about 500 ml of urine
- Has a strong muscular wall composed of three layers of smooth muscle collectively known as the detrusor muscle
- Note that the bladder, when full, can be palpated through the anterior abdominal wall, immediately above the pubic symphysis.

Netter 360 and 361



2.4. The bladder

Slide 26.

The urinary bladder is found immediately posterior to the pubic symphysis in both male and female. The bladder has a strong muscular wall and is able to receive about 500 ml of urine. This muscular wall is composed of three layers of smooth muscle collectively known as the detrusor muscle. Note that although located in the pelvis, the bladder can be palpated through the anterior abdominal wall, immediately above the pubic symphysis, when completely full.

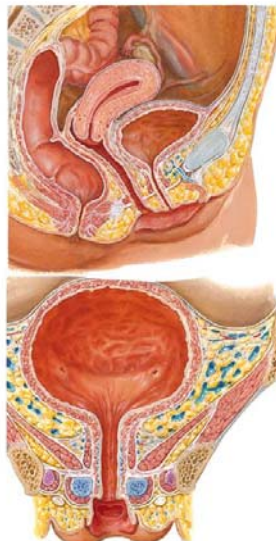
Bladder

Note the bladder has the following features:

- A pyramidal shape
- An apex: connected to the umbilicus by the median umbilical ligament, a remnant of the urachus
- A base: or triangular posterior surface
- A neck, inferiorly

Note how the superolateral angles of the base receive the two ureteric orifices.

Netter 365 and 366



Slide 27.

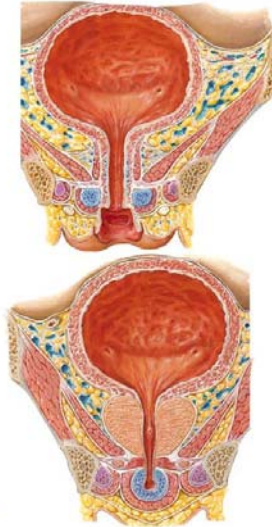
Classically, the bladder is described as having a pyramidal shape, has an apex (connected to the umbilicus by the median umbilical ligament, a remnant of the urachus), a base (triangular posterior surface), and a neck (inferiorly). Note how the superolateral angles of the base receive the two ureteric orifices.

Bladder

Note also the following features:

- The neck opens in the urethra (prostatic urethra in male)
- At the neck, the circular muscular fibers thickened to form the sphincter vesicae
- The sphincter vesicae, under autonomic control, regulates the release of urine from the bladder
- The neck is anchored to the walls of the pelvis by the pubovesical ligaments in female and puboprostatic ligament in male.

Netter 366



Slide 28.

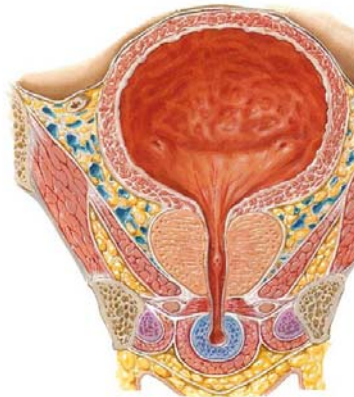
Note that the neck opens in the urethra (prostatic urethra in male) and that at the neck, the circular muscular fibers thickened to form the sphincter vesicae. This sphincter, under autonomic control, regulates the release of urine from the bladder. Observe also that the neck is anchored to the walls of the pelvis by the pubovesical ligaments in female and puboprostatic ligament in male.

Bladder

Note also the following features:

- A mucous membrane lines the inside of the bladder muscular wall, forming folds in the empty bladder
- These folds disappear when the bladder is full
- The smooth portion of the mucous membrane found below a line passing between the two ureteric orifices on the posterior wall is called the trigone
- In this trigone, the mucous membrane do not form folds, even in the empty bladder, due to the fact the membrane is tightly adherent to the underlying muscular layer.

Netter 366



Slide 29.

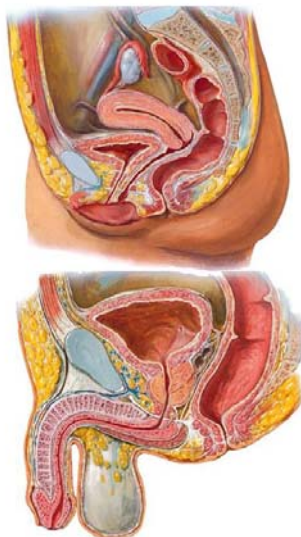
The inside of the bladder muscular wall is covered by a mucous membrane forming folds in the empty bladder. These folds disappear when the bladder is full. Observe the opening of the two ureters on the posterior wall of the bladder. The smooth portion of the mucous membrane found below a line passing between the two ureteric orifices on the posterior wall is called the trigone. In this area, the mucous membrane do not form folds, even in the empty bladder, due to the fact the membrane is tightly adherent to the underlying muscular layer.

Relationships

The superior surface and the upper part of the posterior surface of the bladder is covered by peritoneum forming in:

- In male, the anterior wall of the rectovesical pouch
- In female, the anterior wall of the vesicouterine pouch.
- Note that in female, the neck of the bladder (inferiorly) rests on the upper surface of the urogenital diaphragm whereas in male the neck of the bladder lies on the upper surface of the prostate.

Netter 360 and 361



Slide 30.

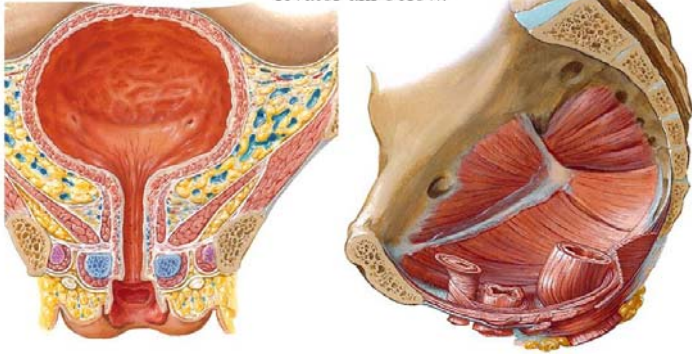
The superior surface and the upper part of the posterior surface of the bladder is covered by peritoneum. In male, it forms the anterior wall of the rectovesical pouch. In female, it forms the anterior wall of the vesicouterine pouch. Note that in female, the neck of the bladder (inferiorly) rests on the upper surface of the urogenital diaphragm whereas in male the neck of the bladder lies on the upper surface of the prostate.

31

Relationships

Netter 366 and 356

Laterally, in both the male and the female, the inferolateral surfaces are related anteriorly to the retropubic fat pads and posteriorly to the obturator internus above and the levator ani below.



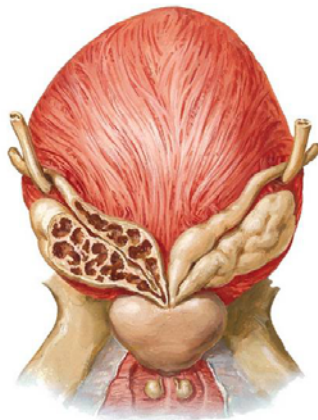
Slide 31.

Laterally, in both the male and the female, the inferolateral surfaces are related anteriorly to the retropubic fat pads and posteriorly to the obturator internus above and the levator ani below.

32

Posterior Relationship in Male

Note that in male, the two vas deferens and the two seminal vesicles can be found on the inferior aspect of the posterior surface of the bladder, superior to the prostate.



Netter 384

Slide 32.

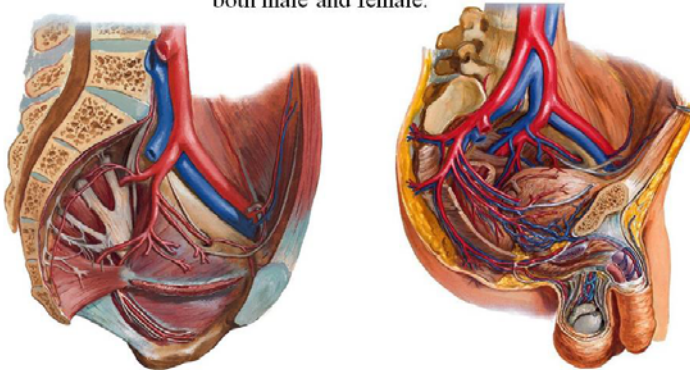
Note that in males, the two vas deferens and the two seminal vesicles can be found on the inferior aspect of the posterior surface of the bladder, superior to the prostate (see later in this lecture).

33

Blood Supply

Netter 402 and 403

The superior and inferior vesical arteries (branches of the internal iliac arteries) provide blood supply to the bladder in both male and female.



Slide 33.

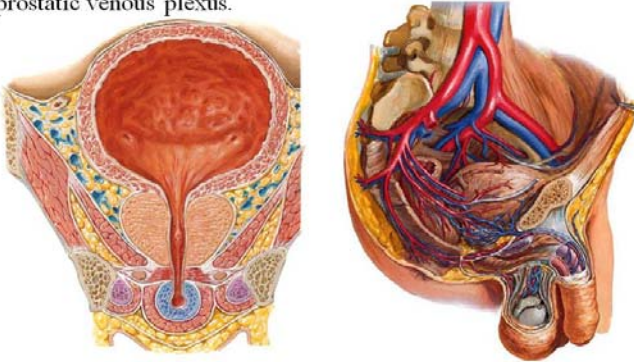
The superior and inferior vesical arteries (branches of the internal iliac arteries) provide blood supply to the bladder in both males and females.

Venous Drainage

Netter 366 and 403

By the vesical venous plexus draining into the internal iliac vein through the superior and inferior vesical veins.

Note that in male, the vesical venous plexus communicates with the prostatic venous plexus.

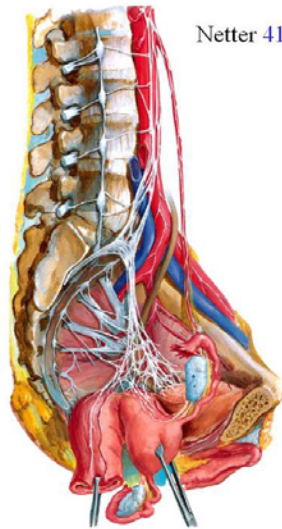


Nerve supply

By the inferior hypogastric plexuses:

- Sympathetic fibers from the first and second lumbar ganglion, synapsing in the inferior hypogastric plexuses and end in the bladder
- Inhibit contraction of the detrusor and stimulate the closure of the sphincter vesicae
- Parasympathetic fibers by the pelvic splanchnic nerves (S₂₋₄), passing in the inferior hypogastric plexuses before innervating the bladder
- Stimulate contraction of the muscular wall and inhibit the action of the sphincter vesicae

Note that the afferent (sensory) fibers are believed to reach the central nervous system through the pelvic splanchnic nerves, with only a few passing through the sympathetic fibers (1st and 2nd lumbar splanchnic).

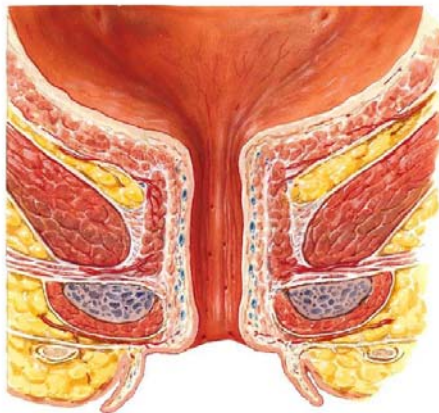


Netter 412

Female Urethra

In female, because of the absence of prostate and penis, the urethra is short. The sphincter urethra muscle surrounds it. This muscle, innervated by the perineal branch of the pudendal nerve, compresses the urethra to stop the flow of urine out of the bladder.

Netter 362 3rd ed.



Slide 34.

In both males and females, the venous drainage is by the vesical venous plexus draining into the internal iliac vein through the superior and inferior vesical veins. Note that in males, the vesical venous plexus communicates with the prostatic venous plexus.

Slide 35.

In terms of innervation, the bladder is under the control of the inferior hypogastric plexuses. The sympathetic fibers originate from the first and second lumbar ganglion, synapse in the inferior hypogastric plexuses and end in the bladder. They inhibit contraction of the detrusor and stimulate the closure of the sphincter vesicae. The parasympathetic fibers pass through the pelvic splanchnic nerves (S₂₋₄), and also synapse in the inferior hypogastric plexuses before innervating the bladder. They stimulate contraction of the muscular wall and inhibit the action of the sphincter vesicae.

Most of the afferent (sensory) fibers are believed to reach the central nervous system through the pelvic splanchnic nerves, with only a few passing through the sympathetic fibers (1st and 2nd lumbar splanchnic).

2.4. The urethra

Slide 36.

In female, because of the absence of prostate and penis, the urethra is short. The sphincter urethra muscle surrounds it. This muscle, innervated by the perineal branch of the pudendal nerve, compresses the urethra to stop the flow of urine out of the bladder.

37

Male Urethra

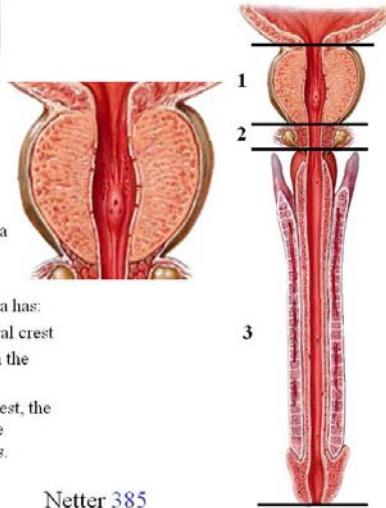
Divided in 3 parts, the prostatic (1), membranous (2) and penile (3).

The prostatic urethra is:

- A little longer than one inch
- Begins at the neck of the bladder
- Passes through the prostate and becomes the membranous urethra
- Is the widest and most dilatable portion of the entire urethra

On its posterior wall, the prostatic urethra has:

- A longitudinal ridge called the urethral crest
- A prostatic groove, on each side with the openings of the prostatic gland
- A small depression on the urethral crest, the prostatic utricle, with on its edges the openings of the two ejaculatory ducts.



Netter 385

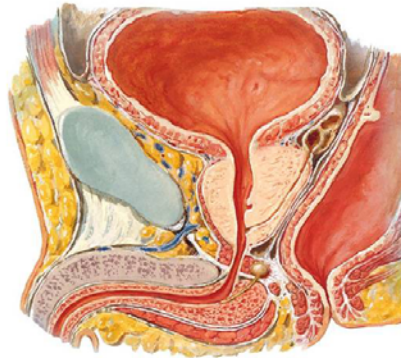
Slide 37.

In male, as already discussed, the urethra is divided in 3 parts, the prostatic, membranous and penile urethra. The prostatic urethra is a little longer than one inch. Beginning at the neck of the bladder, it passes through the prostate and then becomes the membranous urethra. The prostatic urethra is the widest and most dilatable portion of the entire urethra. On its posterior wall, it has longitudinal ridge called the urethral crest. Observe on each side of this crest the prostatic groove with the openings of the prostatic gland. Note also a small depression on the urethral crest, the prostatic utricle, with on its edges the openings of the two ejaculatory ducts (see later in this lecture).

38

Prostate

- Is a male fibromuscular organ located around the urethra, below the bladder and above the urogenital diaphragm
- Has a fibrous capsule covered externally by a fibrous sheath (part of the visceral pelvic fascia)
- A base, superiorly against the neck of the bladder
- An apex, lying inferiorly against the urogenital diaphragm.



Netter 384

III. The male pelvic organs.

3.1. The prostate.

Slide 38.

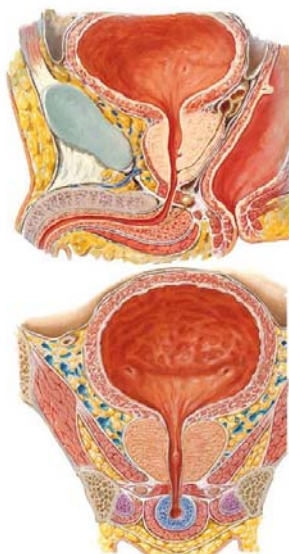The prostate is a male fibromuscular organ located around the urethra, below the bladder and above the urogenital diaphragm. The prostate has a fibrous capsule covered externally by a fibrous sheath (part of the visceral pelvic fascia), a base (superiorly against the neck of the bladder), and an apex (lying inferiorly against the urogenital diaphragm).

39

Relationships

- Anterior surface is related to the extraperitoneal fat located in the retropubic space (posterior to the symphysis pubis).
- Recall that antero-laterally, the prostate is anchored through the puboprostatic ligament.
- Laterally, the prostate is bound by the levator ani.
- Posterior surface is related to the rectal ampulla (separated from it by the fascia of Denonvilliers).

Netter 384 and 366



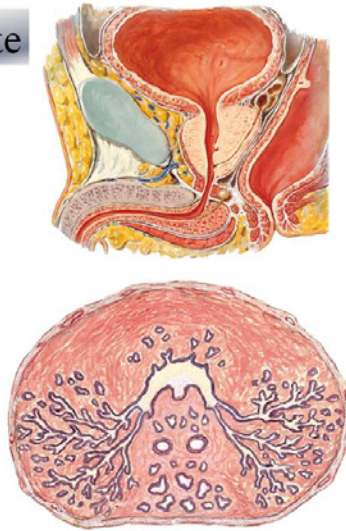Slide 39.

The anterior surface of the prostate is related to the extraperitoneal fat located in the retropubic space (posterior to the symphysis pubis). Recall that antero-laterally, the prostate is anchored through the puboprostatic ligament. Laterally, the prostate is bound by the levator ani. The posterior surface of the prostate is related to the rectal ampulla (separated from it by the fascia of Denonvilliers).

Lobes of the Prostate

- Made of a mix of smooth muscle and connective tissue
- Ducts open in the prostatic urethra as previously described
- 3 lobes: an anterior, with little glandular tissue, a middle lobe, between the prostatic urethra and the ejaculatory ducts, and a posterior lobe, posterior to the ejaculatory ducts
- Middle and posterior lobes contain large amount of glands
- Note that some authors also describes a right and a left lobe
- Note the relationship between the rectum and the prostate (rectal examination).

Netter 384



Slide 40.

The glands forming the prostate are embedded in a mix of smooth muscle and connective tissue. The ducts of the prostatic gland open into the prostatic urethra as previously described. Classically, the prostate is described as having 3 lobes: an anterior, with little glandular tissue, a middle lobe, between the prostatic urethra and the ejaculatory ducts, and a posterior lobe, posterior to the ejaculatory ducts. These last two lobes contain large amount of glands. Note that Snell also describes a right and a left lobe. Note the relationship between the rectum and the prostate, allowing the palpation of the prostate during rectal examination.

Function of the Prostate

The function of the prostate is to produce a thin fluid containing citric acid and phosphatase that is added to the seminal fluid at the time of the ejaculation.

The prostatic secretion, an alkaline solution, is squeezed into the prostatic urethra. It helps neutralize the acidity in the vagina.

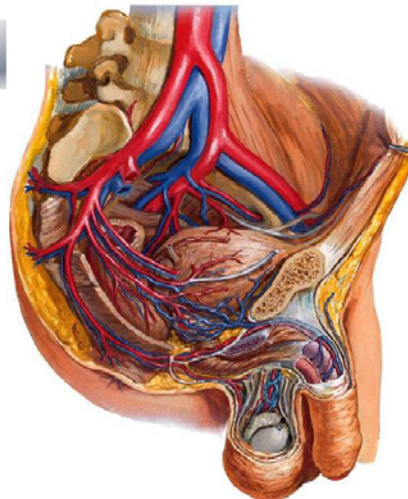
Slide 41.

The function of the prostate is to produce a thin fluid containing citric acid and phosphatase that is added to the seminal fluid at the time of the ejaculation. The prostatic secretion, an alkaline solution, is squeezed into the prostatic urethra. It helps neutralize the acidity in the vagina.

Blood Supply

The prostate receives blood supply essentially from the inferior vesical and middle rectal arteries.

Netter 403



Slide 42.

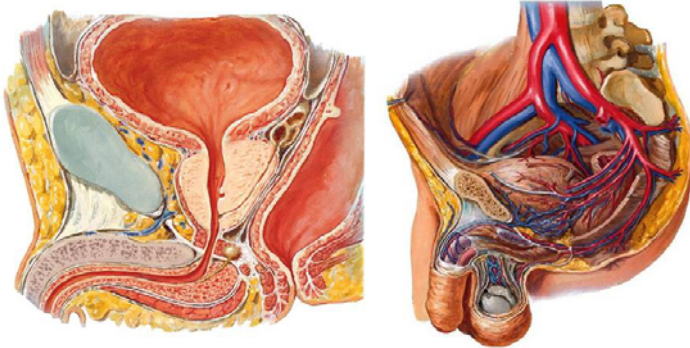
The prostate receives blood supply essentially from the inferior vesical and middle rectal arteries.

43

Venous Return

Netter 384 and 403

The prostatic venous plexus found between the fibrous sheath and the capsule of the prostate drains the prostate. It receives the deep dorsal vein of the penis, has communications with the vesical venous plexus and drains into the internal iliac veins



Slide 43.

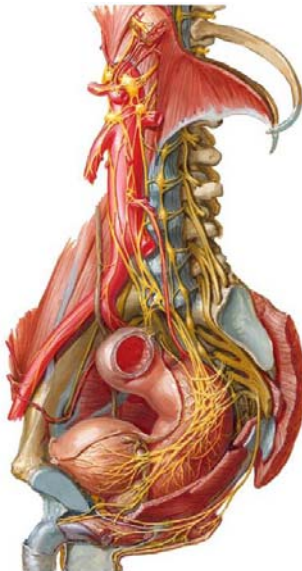
The prostatic venous plexus found between the fibrous sheath and the capsule of the prostate drains the prostate. It receives the deep dorsal vein of the penis, has communications with the vesical venous plexus and drains into the internal iliac veins.

44

Nerve Supply

The nerve supply of the prostate is through the prostatic nerve plexus, receiving sympathetic fibers from the inferior hypogastric plexus. The sympathetic fibers stimulate the smooth muscle of the prostate during ejaculation.

Netter 410



Slide 44.

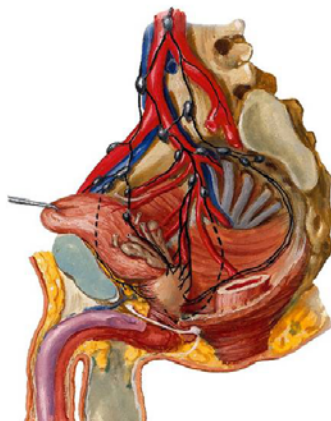The nerve supply of the prostate is through the prostatic nerve plexus, receiving sympathetic fibers from the inferior hypogastric plexus. The sympathetic fibers stimulate the smooth muscle of the prostate during ejaculation.

45

Lymphatic Drainage

Netter 408

The lymphatic drainage of the prostate is through the internal and external nodes, draining then in the common iliac nodes.



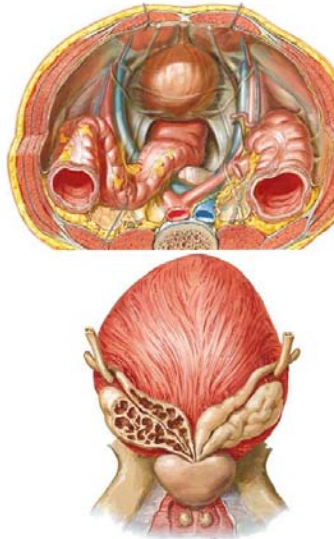
Slide 45.

The lymphatic drainage of the prostate is through the internal and external nodes, draining then into the common iliac nodes.

Vas Deferens

- Is a thick-walled tube (about 18 inches long) moving sperm from epididymis ejaculatory duct/urethra
- Emerges at the deep inguinal ring and passes downward and backward on the lateral wall of the pelvis where it crosses the ureter anteriorly in the region of the ischial spine
- Runs medially and downward on the posterior surface of the prostate
- Has a dilated terminal portion called the ampulla of the vas deferens.
- Fuses then with the duct of the seminal vesicle to form the ejaculatory duct.

Netter 363 and 384



3.1. The vas deferens

Slide 46.

Recall that the vas deferens is a thick-walled tube (about 18 inches long) allowing the mature sperm to move from the epididymis to the ejaculatory duct and then into the urethra. In the pelvis, it emerges at the deep inguinal ring (lateral to the inferior epigastric artery) and passes downward and backward on the lateral wall of the pelvis where it crosses the ureter anteriorly in the region of the ischial spine. It then runs medially and downward on the posterior surface of the prostate. This terminal portion of the vas is dilated to form the ampulla of the vas deferens. Finally, the vas deferens fuses with the duct of the seminal vesicle to form the ejaculatory duct. Note also the presence of the vesical seminal, immediately below the terminal portion of the vas deferens, on the posterior aspect of the prostate (see next).

3.1. The seminal vesicles

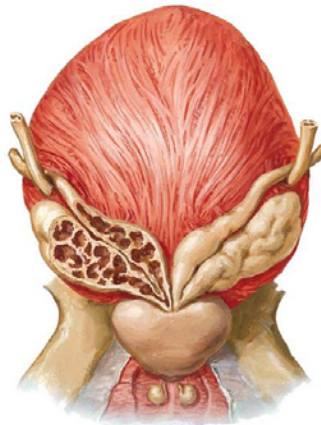
Slide 47.

Note also the presence of the seminal vesicles, immediately below the terminal portion of the vas deferens, on the posterior aspect of the bladder. Each vesicle is a coiled tube embedded in connective tissue. It produces a secretion that is added to the seminal fluid. This one contains substances essential to the survival of the spermatozoa. During ejaculation, the walls of the seminal vesicles contract to add their secretions into the ejaculatory ducts. Review the location of the openings of both the prostate and the ejaculatory ducts in the prostatic urethra.

Seminal Vesicles

- Below the terminal portion of the vas deferens, on the posterior aspect of the bladder
- Each vesicle is a coiled tube embedded in connective tissue. It produces a secretion that is added to the seminal fluid
- Secretion contains substances essential to the survival of the spermatozoa
- During ejaculation, the walls of the seminal vesicles contract to add their secretions into the ejaculatory ducts.

Netter 384



The Female Pelvis

By *Thierry Bacro, Ph.D*

Department of Regenerative Medicine and Cell Biology
Center for Anatomical Studies and Education
College of Medicine
Medical University of South Carolina

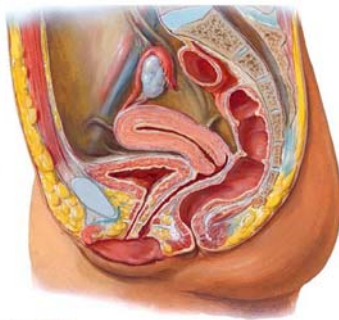Slide 1.

In this lecture, we describe the essential features of the organs found in the female pelvis as well as their blood supply, venous and lymphatic drainages. We will also focus on the relationships of these organs with one another and some important clinical points related to these organs.

2

Female Pelvic Organs

- Ovary
- Uterine (Fallopian) tube
- Uterus
- Vagina



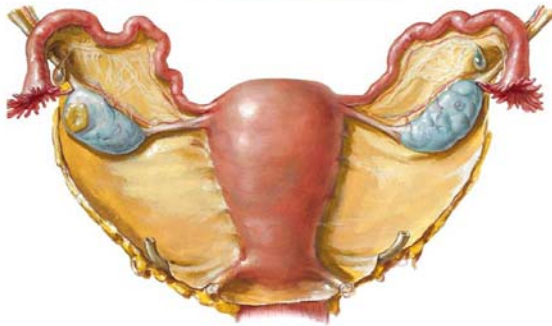
Netter 360

Slide 2.

In addition to the pelvic organs already described in the previous lecture of the male pelvis (sigmoid colon, rectum, etc), one can find the following organs in the normal female pelvis: a set of 2 ovaries and 2 uterine tubes (also called Fallopian tubes or oviducts), a uterus and a vagina. Note that all of these structures (with the exception of the lower vagina) are located in the pelvic cavity. Note the relationship between these organs in this mid-sagittal section.

3

Female Pelvic Organs



Posterior view of broad ligament
with uterus, tubes, and ovaries

Netter 355

Slide 3.

On this posterior view, one can observe the relative arrangement of the 2 ovaries, 2 uterine tubes, uterus and vagina. Note also on this view how the peritoneum covers nearly the entire set of structures and by doing so create the broad ligament (see details later in the lecture).

Slide 4.

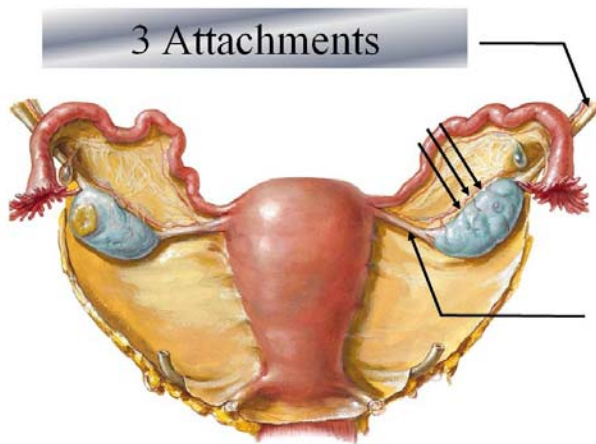
We will now discuss each of the organs mentioned above one by one. Let's start with the ovary. This organ is where the ovum (plural ova) develops through the regular hormonal cycle to be released close to the opening of the uterine tube. The ovary is attached to the pelvic wall by the suspensory ligament (which contains the ovarian artery and vein, and lymphatic vessels) and to the uterus by the ovarian ligament (proper ligament of the ovary). It is also suspended from the main broad ligament by the mesovarium (a part of the broad ligament).

4

The Ovary Has 3 Attachments

1. Suspensory ligament: also called the infundibulo-pelvic ligament, contains the ovarian artery and vein, lymphatic vessels and nerves from pelvic wall to the ovary
2. Ovarian ligament: also proper ligament of the ovary, is an embryological remnant
3. Mesovarium: is part of the broad ligament

5



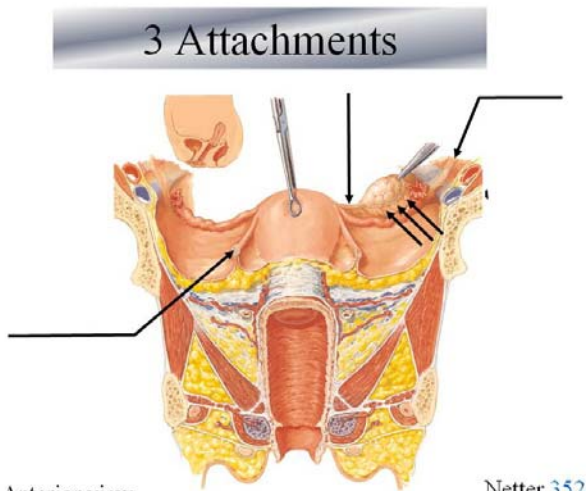
Posterior view

Netter 355

Slide 5.

On this posterior view, observe the 3 attachments of the ovary, the suspensory ligament, the mesovarium and the proper ligament of the ovary.

6



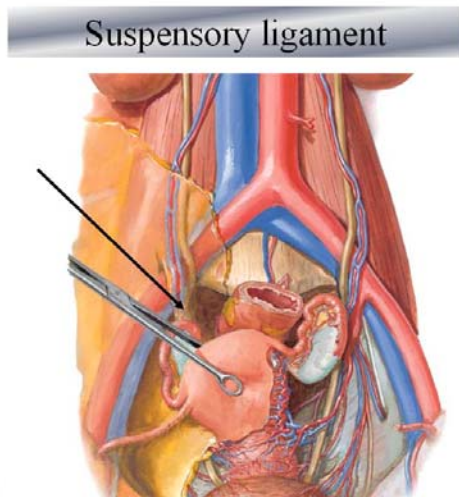
Anterior view

Netter 352

Slide 6.

On this anterior view of the organs of the female pelvis, observe the same set of structures. Note however that one can see much better the mesovarium forming a shelf-like structure from the main broad ligament. Note also on this view the round ligament of the uterus passing on each side anteriorly toward (through) the inguinal canal (see later in lecture).

7



Netter 380

Slide 7.

This view shows in more details the suspensory ligament attaching the ovary to the posterior pelvic wall (intact on the right side and dissected on the left side). Recall that this one contains the ovarian artery and vein, and lymphatic vessels. Note that this structure is also called the infundibulo-pelvic ligament by surgeons.

Uterine (Fallopian) Tubes

- Convey ovum (ova) from ovaries to uterus
- Convey sperm from uterus to ovum
- Are the normal site of fertilization of ovum
- Are enclosed in the most superior part of broad ligament
- The peritoneal reflection conveying blood supply to uterine tube is called mesosalpinx (salpinx in Greek means trumpet). Is part of the broad ligament.

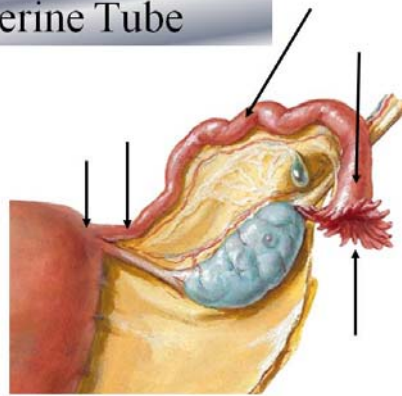
Slide 8.

The uterine tubes have several important functions and features:

- It conveys the ovum from the ovary to uterus (has mobile cilia lining the mucosa)
- It also conveys the sperm from uterus to the ovum
- It provides a environment for the fertilization of the ovum
- It is enclosed in the most superior part of broad ligament on each side
- Note that the part of the broad conveying the blood supply to the uterine tube is called mesosalpinx (salpinx in Greek means trumpet).

Uterine Tube

- Fimbria: fingerlike processes
- Infundibulum: funnel shaped
- Ampulla: widest, longest part; where fertilization usually occurs
- Isthmus: narrowest part, adjacent to uterus
- Intramural part: within wall of uterus



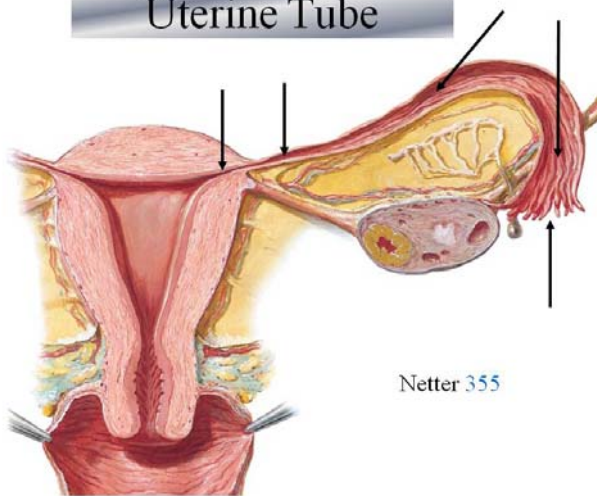
Netter 355

Slide 9.

The uterine tube is composed of several distinct parts, namely the:

- Fimbria: a set of fingerlike processes
- Infundibulum: a funnel shaped structures with the fimbria at the end
- Ampulla: the widest part of the tube where fertilization usually takes place
- Isthmus: the narrowest part of the tube immediately adjacent to the uterus
- Intramural part of the tube: within the wall of the uterus (see next slide)

Uterine Tube

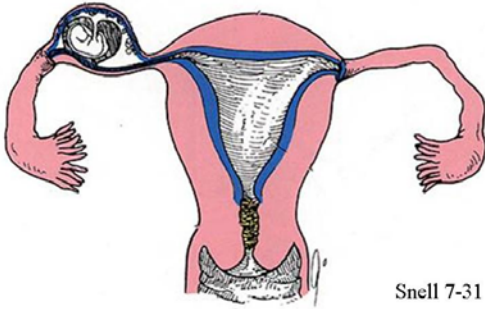


Netter 355

Slide 10.

Observe on this frontal section of the uterus the different parts of the uterine tube. Note in particular the intramural part of the uterine tube.

Ectopic (Tubal) Pregnancy

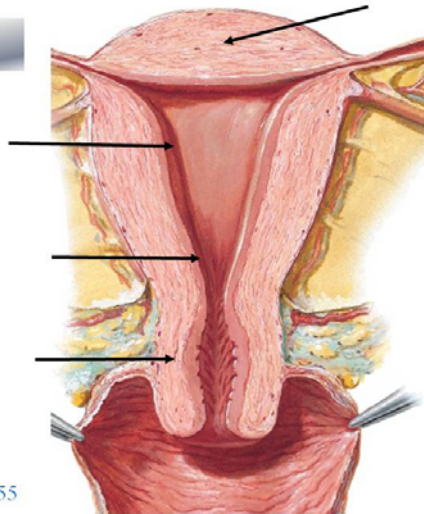


Slide 11.

Normally in pregnancy, the fertilized ovum, also called zygote, implants on the posterior wall of the body of the uterus (see next slide). An ectopic pregnancy is defined as a pregnancy in which the zygote implants in an abnormal location. A common site for an ectopic pregnancy is in the ampulla of the uterine tube as shown on this image. This is an extremely dangerous situation as the wall of the tube is not suited for this purpose and can rupture with the growth of the embryo. Rupture of the tube can lead to serious hemorrhage and in life-threatening emergency.

Uterus

- Fundus
- Body
- Isthmus
- Cervix (neck)



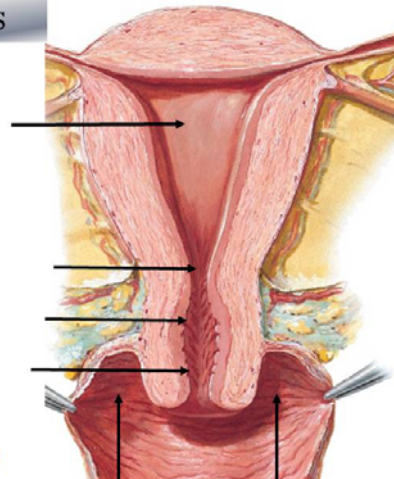
Slide 12 .

The uterus also has named portions:

- The fundus: the portion above the entrance of the uterine tube
- The body: extends between the entry point of the two uterine tubes superiorly and the isthmus inferiorly
- The isthmus: is the narrow portion between the body and the cervix
- The cervix: the neck-like portion of the lower uterus.

Lumen of Uterus

- Uterine lumen
- Internal os
- Cervical canal
- External os
- Fornix of vagina (lateral fornices)

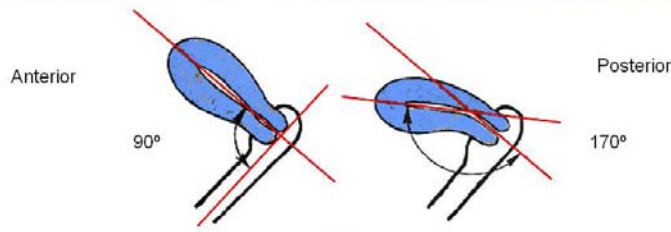


Slide 13.

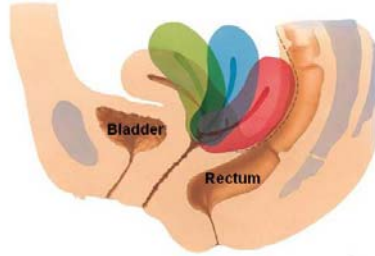
Note that the uterus is a hollow organ. Observe the uterine lumen. Note also that the cervix has an internal os and an external os with the cervical canal between the two. The part of the cervix that protrudes in the vagina is called the fornix. The presence of the fornix in the upper vagina creates spaces that are called the anterior, posterior, and lateral fornices. To fertilize the ovum, the sperm has to pass from the vagina to the ampulla of the uterine tube.

14

Angles of Anteversion and Antelexion



Retroversion of Uterus

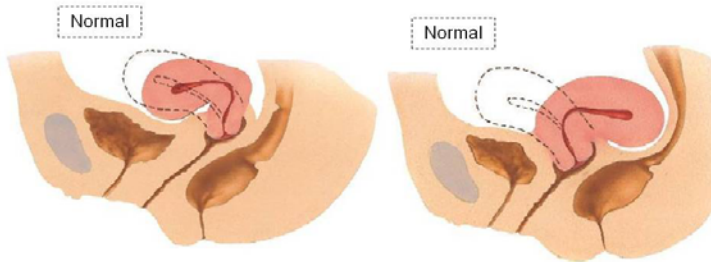


Slide 14.

Observe in these pictures (mid-sagittal section) that the uterus does not align with the vagina. Note that the cervical canal is normally at a 90 degree angle with the vagina (anteversion). Note also that uterine body is often (anteriorly) flexed over the cervical canal. The two form an angle of about 170 degree (antelexion).

15

Anteflexion and Retroflexion



Netter 358 3rd ed.

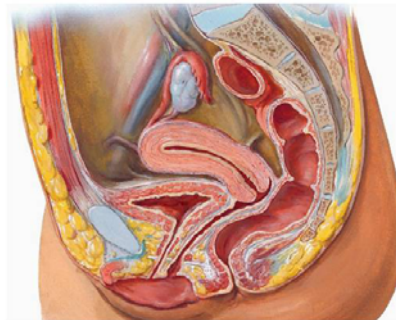Slide 15.

In some cases, the anteflexion can be excessive or the body of the uterus can also be found in the opposite position called retroflexion. Excessive anteflexion or retroflexion can be the cause of fertilization problems.

16

Surfaces of Uterus

- Intestinal surface:
 - Posterosuperior
 - Related to ileum and sigmoid colon
- Vesical surface:
 - Anteroinferior
 - Related to urinary bladder



Netter 342

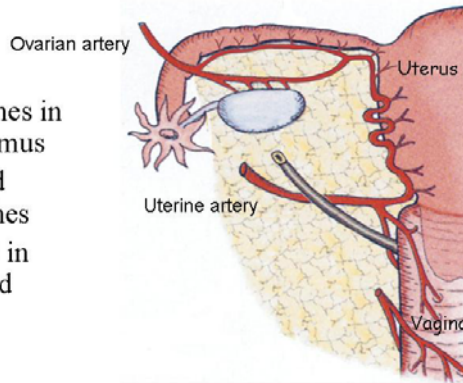
Slide 16.

The uterus also presents 2 surfaces:

- The intestinal surface: found postero-superiorly and related to the ileum and sigmoid colon
- The vesical surface: found antero-anteriorly and related to the urinary bladder.

Lateral Border of Uterus

- Uterine artery comes in at level of the isthmus
- Has ascending and descending branches
- Ascending branch in broad ligament and anastomoses with ovarian artery

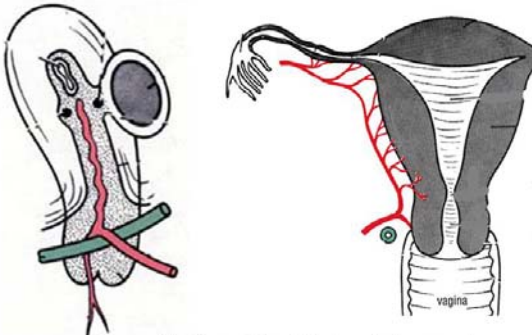


Grant's Dissector 5.27

Slide 18.

The uterus also has two lateral borders (right and left). The uterine artery brings blood supply to the organ laterally through the broad ligament at about the level of the isthmus. It provides ascending and descending branches passing upward and downward in the thickness of the broad ligament. The ascending branch of the uterine artery anastomoses with the ovarian artery superiorly.

Important Relationship



- Ureter passes close (1-2 cm) just lateral to cervix
- Ureter passes immediately inferior to uterine artery
- (Water under the bridge)

Snell 7-19 & 7-25

Slide 19.

Observe also on this diagram the important relationship of the uterine artery with the ureter passing in the pelvic cavity toward the bladder. At that level, the ureter is passing less than one inch lateral to the cervix, immediately inferior to the artery coming in at that level.

Layers of uterus

1. Endometrium: mucous membrane lining lumen of uterus
2. Myometrium: thick wall of smooth muscle and connective tissue
3. Parametrium: very thin serous covering (visceral peritoneum) on vesical and intestinal surfaces of uterus

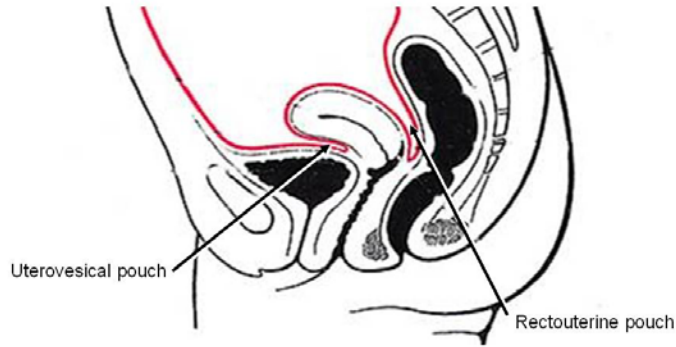
Slide 20.

The uterus presents with 3 well developed layers:

- The endometrium: a mucous membrane lining the lumen of the uterus undergoing cyclic changes in response to the monthly hormonal cycle
- The myometrium: the thick wall of the uterus consisting of smooth muscle and connective tissue
- The Parametrium: a thin serous covering the vesical and intestinal surfaces of the uterus

21

Uterovesical and Rectouterine Pouches



Clemente's Dissector, 19-5

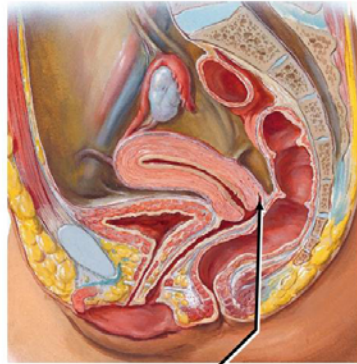
Slide 21.

Observe on this mid-sagittal section the presence of two spaces called pouches, the uterosacral pouch and the rectouterine pouch. These 2 pouches are lined by the parietal peritoneum covering the superior aspect of the pelvic cavity. The uterovesical pouch is anterior to the uterus, between the bladder and the uterus with the rectouterine pouch being between the uterus and the rectum posteriorly.

22

Rectouterine Pouch

Relationship of the rectouterine pouch (Pouch of Douglas) to posterior vaginal fornix allows culdocentesis by needle aspiration through vagina.



Posterior vaginal fornix

Netter 342

Slide 22.

Clinically, the rectouterine pouch is also called the Pouch of Douglas. Observe the relationship between the posterior vaginal fornix and the Pouch of Douglas. This close relationship allows a technique called culdocentesis (needle aspiration through the vagina).

23

Broad Ligament

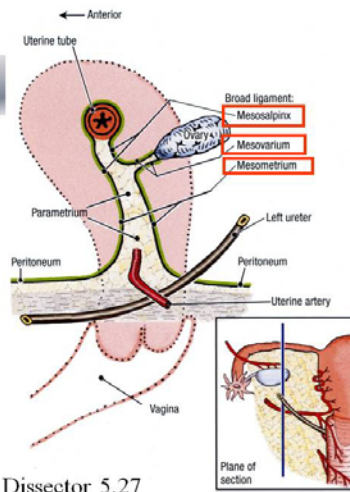
- Is the peritoneal layer covering the uterus
- Has an anterior and a posterior lamina
- Has 3 named parts, the mesovarium the mesosalpinx, and the mesometrium.

Slide 23.

The broad ligament is the name given to the peritoneum layer covering the uterus and associated organs. It is classically described as having an anterior and posterior lamina and 3 named parts: the mesovarium, the mesosalpinx and the mesometrium.

Broad Ligament

- The mesovarium
- The mesosalpinx
- The mesometrium



Grant's Dissector 5.27

Slide 24.

This mid-sagittal section from our Grant's Dissector allows the visualization of the 3 named parts of the broad ligament:

- The mesovarium is the shelf-like structure horizontally extending posteriorly toward the ovary
- The mesosalpinx is the portion of the uterus immediately inferior to the uterine (Fallopian tube)
- The mesometrium is the portion of the broad ligament that extends laterally from the right and left lateral borders of the uterus, under the level of the ovaries. The anterior and posterior lamina of the uterus can best be demonstrated at that level.

Ligaments of Uterus

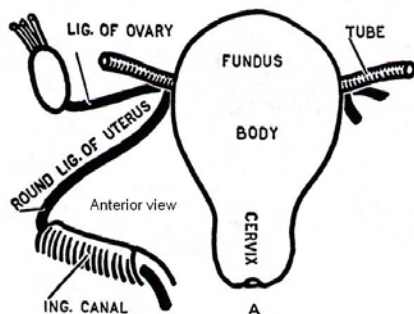
1. Broad ligament: peritoneum between pelvic wall and uterus
2. Round ligament of the uterus: lower derivative of the gubernaculum, pass through the inguinal canal
3. Pubocervical ligament
4. Cardinal (transverse cervical) ligament
5. Uterosacral (rectouterine) ligament

Slide 25.

Several ligaments are associated with the uterus. The broad ligament and the round ligament were already mentioned in this lecture with the round ligament (a derivative or remnant of the gubernaculum passing anterior to/through the inguinal canal).

Other ligaments anchor the uterus and vagina in the pelvic floor: the pubocervical ligament, the cardinal (transverse cervical) ligament and the uterosacral (rectouterine) ligament.

Round Ligament of Uterus



Grant's Method 19.5

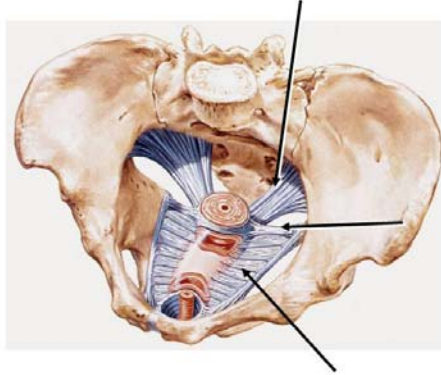
Slide 26.

Observe on this diagram the round ligament passing anteriorly to/through the inguinal canal.

27

Ligaments of Uterus

- Uterosacral ligaments
- Transverse cervical ligaments
- Pubocervical ligaments



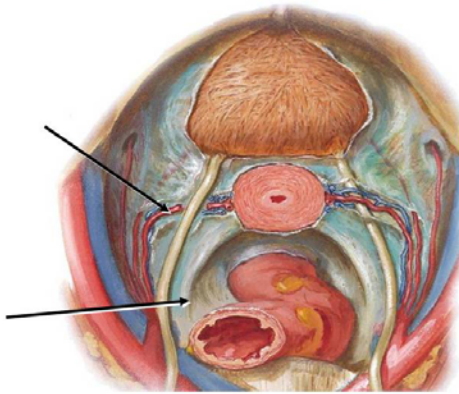
Netter 353

Slide 27.

Observe on this new Netter plate (existing only in the 4th edition) the other ligaments anchoring the uterus and vagina in the pelvic floor: the uterosacral (rectouterine) ligament, the cardinal (transverse cervical) ligament and the pubocervical ligament.

28

Cardinal and Uterosacral Ligaments



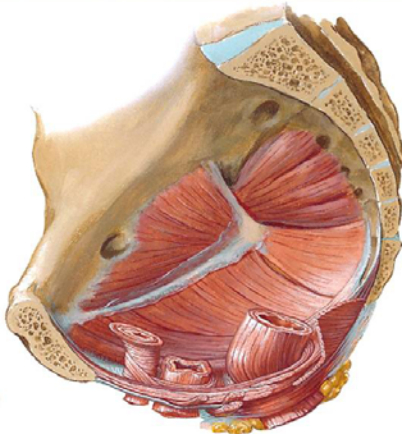
Netter 344

Slide 28.

Note on this plate how the uterine artery uses the cardinal ligaments to enter the lateral aspect of the broad ligament at the level of the isthmus. Observe also posteriorly the uterosacral ligaments.

29

Levator Ani Muscles Support the Uterus

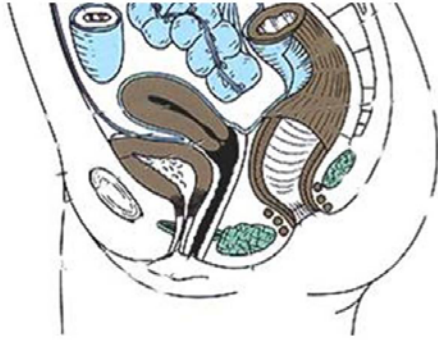


Netter 337

Slide 29.

The ligaments described in the previous slides maintains the orientation and provide some support of the uterus and associated structures with the levator ani muscles providing strong support to the uterus. Take here the opportunity to review the muscles forming the levator ani.

Vagina

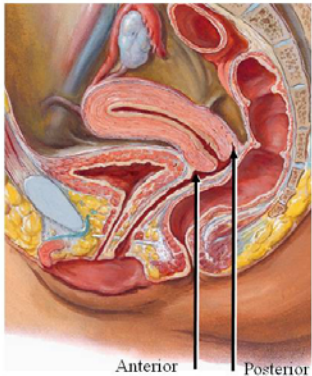


Snell 7-5

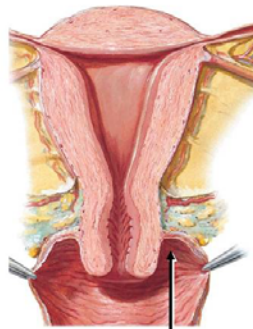
Slide 30.

The last organ to discuss in this lecture is the vagina. As already described, the vagina is found inferior to the uterus. Note that the anterior wall of the vagina is shorter than the posterior wall. Note that the posterior wall is related to the rectum.

Vaginal Fornices



Anterior Posterior
Netter 360

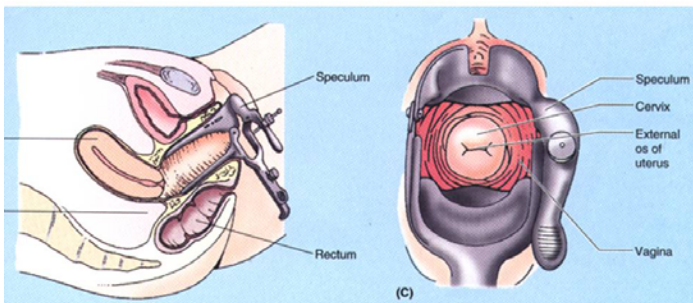


Lateral
Netter 355

Slide 31.

Observe again on these Netter plates the anterior and posterior as well as lateral fornices.

Examination of Vagina and Cervix with Vaginal Speculum



Moore & Dalley, p. 373

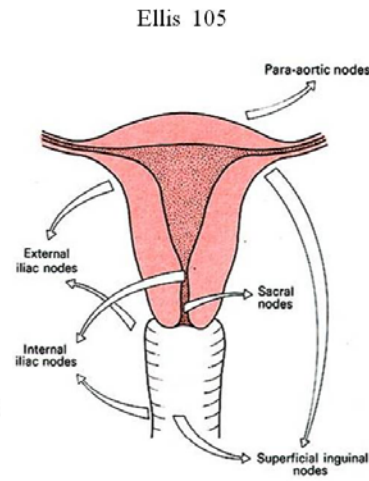
Slide 32.

Note on this slide from Moore and Dalley how a vaginal speculum can be used to spread the vaginal walls to examine the cervix of the uterus. Much important information can be learned from observing the cervix and fornices.

33

Lymphatic Drainage

- Ovary: para-aortic nodes
- Uterus: para-aortic nodes
- Uterus fundus and body: superficial inguinal nodes (via round ligament of uterus)
- Uterus: internal and external iliac nodes (and sacral nodes on posterior wall)
- Vagina: internal iliac nodes and superficial inguinal nodes

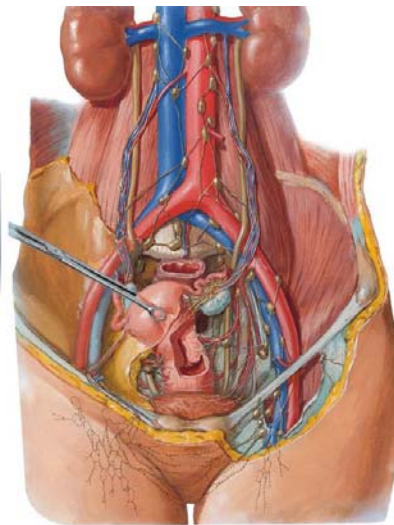


Slide 33.

The complex drainage of the ovaries, uterus and vagina is summarized on this slide.

34

Lymphatic Drainage



Netter 386

Slide 34.

Take this opportunity to review the main nodes draining organs and structures of the pelvic cavity: the para-aortic nodes, the internal and external nodes, the superficial and deep inguinal nodes.

35

The End.

Slide 35.

The end.

